

CE MONOGRAPH

PRESSURE MATTERS

NEW THERAPIES **IN THE MEDICAL MANAGEMENT OF GLAUCOMA**

Visit <http://tinyurl.com/manageglaucomaCE> for online testing
and instant CE certificate

FACULTY



MICHAEL CHAGLASIAN, OD

Chief of Staff
Illinois Eye Institute
Associate Professor
Illinois College of Optometry
Chicago, Illinois



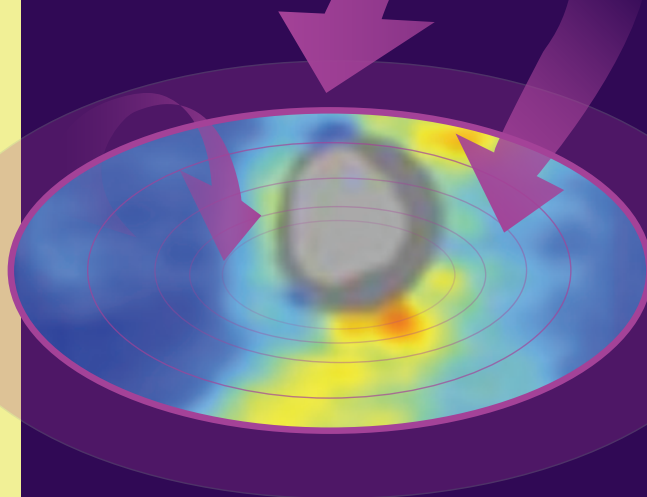
MURRAY FINGERET, OD

Clinical Professor
State University of New York
College of Optometry
New York, New York

COPE approved for 2.0 credits for optometrists
COPE Course ID: 59432-GL
Cope Course Category: Glaucoma



This continuing education activity is supported through an unrestricted
educational grant from Bausch & Lomb Incorporated.



ORIGINAL RELEASE: OCTOBER 1, 2018

EXPIRATION: OCTOBER 31, 2019

Sponsored by



Administrator



Distributed with



LEARNING METHOD AND MEDIUM

This educational activity consists of a supplement and twenty (20) study questions. The participant should, in order, read the learning objectives contained at the beginning of this supplement, read the supplement, answer all questions in the post test, and complete the Activity Evaluation/Credit Request form. To receive credit for this activity, please follow the instructions provided on the post test and Activity Evaluation/Credit Request form. This educational activity should take a maximum of 2.0 hours to complete.

CONTENT SOURCE

This continuing education (CE) activity captures content from a regional dinner meeting series.

ACTIVITY DESCRIPTION

This case-based educational activity focuses on reinforcing the role of nitric oxide (NO) in glaucomatous eyes; achieving target intraocular pressure (IOP) levels; targeting new sites of action, such as the trabecular meshwork, with emerging therapies; and interpreting clinically relevant data supporting a role for emerging medical therapies in patients with glaucoma.

TARGET AUDIENCE

This educational activity is intended for optometrists.

LEARNING OBJECTIVES

Upon completion of this activity, participants will be better able to:

- Describe how NO lowers IOP through the trabecular meshwork
- Recognize the relationship between aqueous humor dynamics and selection of therapies to lower IOP in patients with glaucoma
- Develop evidence-based treatment plans for achieving target IOP levels in patients with glaucoma
- Employ patient counseling strategies to ensure adherence to IOP-lowering medication schedules

ACCREDITATION STATEMENT

COPE approved for 2.0 CE credits for optometrists.

COPE Course ID: 59432-GL

COPE Course Category: Glaucoma

Administrator: **MedEdicus**

DISCLOSURES

Michael Chaglasian, OD, had a financial agreement or affiliation during the past year with the following commercial interests in the form of *Grants/Research Support Recipient*: Heidelberg Engineering, Inc; and Topcon Corporation; *Advisory Board*: Alcon; Allergan; and Bausch & Lomb Incorporated.

Murray Fingeret, OD, had a financial agreement or affiliation during the past year with the following commercial interests in the form of *Grants/Research Support Recipient*: Carl Zeiss Meditec, Inc; Heidelberg Engineering, Inc; and Topcon Medical Systems, Inc; *Consultant*: Aerie Pharmaceuticals, Inc; Alcon;

Allergan; Bausch & Lomb Incorporated; Carl Zeiss Meditec, Inc; Diopsys, Inc; and Topcon Medical Systems, Inc.

EDITORIAL SUPPORT DISCLOSURES

Tony Realini, MD, had a financial agreement or affiliation during the past year with the following commercial interests in the form of *Consultant/Advisory Board*: Aerie Pharmaceuticals, Inc; Inotek Pharmaceuticals Corporation; New World Medical, Inc; and Reichert, Inc.

Diane McArdle, PhD; Cynthia Tornallyay, RD, MBA, CHCP; and Michelle Ong have no relevant commercial relationships to disclose.

DISCLOSURE ATTESTATION

The contributing physicians listed above have attested to the following:

- 1) that the relationships/affiliations noted will not bias or otherwise influence their involvement in this activity;
- 2) that practice recommendations given relevant to the companies with whom they have relationships/affiliations will be supported by the best available evidence or, absent evidence, will be consistent with generally accepted medical practice; and
- 3) that all reasonable clinical alternatives will be discussed when making practice recommendations.

PRODUCT USAGE IN ACCORDANCE WITH LABELING

Please refer to the official prescribing information for each drug discussed in this activity for approved indications, contraindications, and warnings.

GRANTOR STATEMENT

This continuing education activity is supported through an unrestricted educational grant from Bausch & Lomb Incorporated.

SPONSORED BY



TO OBTAIN CE CREDIT

We offer instant certificate processing and support Green CE. Please take this post test and evaluation online by going to <http://tinyurl.com/manageglaucomaCE>. Upon passing, you will receive your certificate immediately. You must answer 14 out of 20 questions correctly in order to pass, and may take the test up to 2 times. Upon registering and successfully completing the post test, your certificate will be made available online and you can print it or file it. Please make sure you take the online post test and evaluation on a device that has printing capabilities. There are no fees for participating in and receiving CE credit for this activity.

DISCLAIMER

The views and opinions expressed in this educational activity are those of the faculty and do not necessarily represent the views of the State University of New York College of Optometry, MedEdicus LLC, Bausch & Lomb Incorporated, or *Review of Optometry*.

This CE activity is copyrighted to MedEdicus LLC ©2018. All rights reserved. 160D

PRESSURE MATTERS

NEW THERAPIES IN THE MEDICAL MANAGEMENT OF GLAUCOMA

INTRODUCTION

For the first time in more than 20 years, we have new classes of glaucoma medications with novel mechanisms of action for lowering intraocular pressure (IOP). Unlike the drugs we have been using for decades, latanoprostene bunod (LBN) and netarsudil both lower IOP by directly increasing the outflow of aqueous humor through the trabecular outflow pathway, which is the primary pathway through which aqueous humor exits the eye. These new drugs work where the problem is by improving the impaired trabecular outflow that leads to elevated IOP in eyes with glaucoma. In this educational activity, the mechanisms of action of LBN and netarsudil will be described, with a focus on their effect on aqueous humor dynamics. The development of evidence-based management of glaucoma in incorporating these new drugs to achieve and maintain target IOP in eyes with glaucoma will be discussed. Finally, strategies to improve patient adherence will be reviewed.

AQUEOUS HUMOR DYNAMICS: THE INS AND OUTS OF INTRAOCULAR PRESSURE

Intraocular pressure is determined by the balance of aqueous humor formation in the eye and the rate at which aqueous humor exits the eye. Aqueous humor is produced by the nonpigmented epithelial cells of the processes of the ciliary body.¹ Aqueous humor fills the posterior chamber, flows through the pupil, and fills the anterior chamber. The rate of aqueous humor formation is approximately 2.5 $\mu\text{L}/\text{min}$.² At this rate, aqueous humor in the anterior chamber is replaced approximately once every 100 minutes.

Aqueous humor leaves the eye through 2 distinct pathways. Most aqueous humor exits through the trabecular outflow pathway.³ This involves passing through the 3 layers of the trabecular meshwork—uveal layer, corneoscleral layer, and juxtacanalicular layer—before entering Schlemm canal, where it passes into distal collector channels to aqueous veins that drain into the episcleral venous system. The trabecular outflow pathway is also called the conventional outflow pathway, primarily because it handles most aqueous humor outflow.

A smaller proportion of aqueous humor exits the eye through the less well-characterized uveoscleral outflow pathway.⁴ To access this pathway, aqueous humor first crosses through the anterior face of the ciliary body, where it then passes between the muscle bundles of the ciliary body to access the suprachoroidal space, from which it exits the eye by passing through the sclera or by

entering the choroid and exiting the eye through the vortex veins. The uveoscleral outflow pathway handles the minority of aqueous outflow and is less well understood than the trabecular pathway. It is the uveoscleral outflow pathway that is modified with the use of prostaglandin agents, taking a larger role in aqueous outflow.

Eyes with primary open-angle glaucoma (POAG) have elevated IOP primarily because of decreased aqueous humor outflow through the trabecular meshwork.⁵ The rate of aqueous humor production is typically unchanged by glaucoma,⁶⁻⁸ and the effect of uveoscleral outflow on the development of glaucoma remains controversial, in part because of the challenges of measuring uveoscleral outflow.⁴

ENHANCING TRABECULAR OUTFLOW IN GLAUCOMA

The 2 new drugs—LBN and netarsudil—act directly in the trabecular meshwork to increase trabecular outflow. Pilocarpine and other miotic drugs increase trabecular outflow indirectly by stimulating the ciliary muscle to tug on the scleral spur, mechanically stretching the meshwork to open outflow channels. Latanoprostene bunod and netarsudil are the first to act directly on trabecular meshwork tissue to decrease resistance to aqueous humor outflow.

Latanoprostene Bunod

Latanoprostene bunod is a novel molecule consisting of the prostaglandin analogue latanoprost and a nitric oxide (NO)-donating moiety. Upon instillation into the eye, the molecule dissociates into its 2 active components. Latanoprost, a familiar prostaglandin analogue, lowers IOP by enhancing uveoscleral outflow. Nitric oxide, which has an interesting history leading up to its medical use, lowers IOP through direct action in the trabecular meshwork.⁹

Nitric oxide was discovered more than 200 years ago¹⁰ and, until just the past few decades, was thought to be generally not important to human health and disease. In the 1970s, the well-known vasodilating effect that nitrates such as nitroglycerin have in the management of diseases such as angina pectoris was attributable to the liberation of NO from nitrates.¹⁰ Soon thereafter, it was discovered that NO is synthesized by vascular endothelial cells,¹¹ leading to the realization that NO plays an important role in many biologic systems, including the cardiovascular and neurologic systems.

In healthy eyes, NO is synthesized in the endothelium of uveal vasculature, Schlemm canal, and the ciliary body.^{12,13} Nitric oxide is known to increase trabecular outflow facility in the human anterior segment,¹⁴ and NO donors lower IOP in animal models.⁹ The mechanism by which NO lowers IOP is through relaxation of cells in the trabecular meshwork and Schlemm canal via rearrangement of actin-myosin interactions by decreasing myosin phosphorylation, which leads to increased aqueous humor outflow and IOP reduction (**Figure 1**).^{12,15-17}

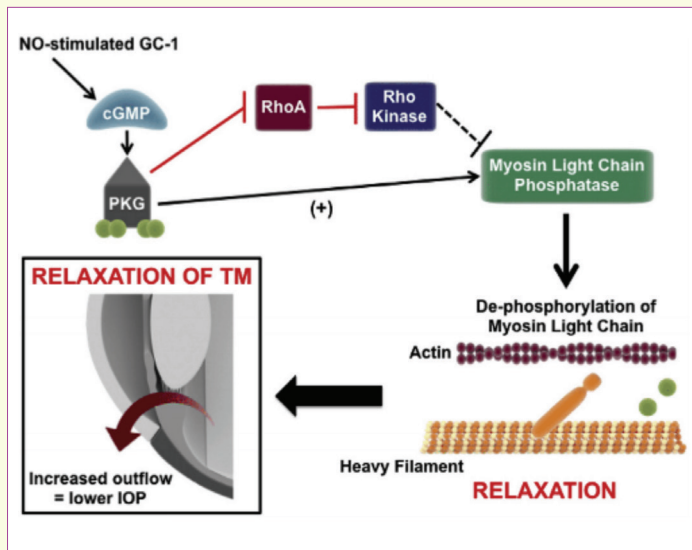


Figure 1. cGMP-mediated modulation of IOP through increase in aqueous humor outflow. Nitric oxide triggers production of cGMP by GC-1. cGMP activates PKG. Activated PKG can phosphorylate numerous targets with multiple downstream effects, including inhibition of Rho A, thus preventing inhibition of myosin phosphatase by Rho kinase. In addition to inhibition of Rho A, activated PKG can directly activate myosin light chain phosphatase. Subsequent dephosphorylation of the regulatory light chain of myosin by myosin light chain phosphatase prevents actin-myosin interaction, promoting cell relaxation. This in turn leads to a widening of the intercellular spaces in the juxtacanalicular TM and Schlemm canal, thus facilitating conventional aqueous humor outflow and relieving IOP.

Abbreviations: cGMP, cyclic guanosine monophosphate; GC-1, guanylate cyclase-1; IOP, intraocular pressure; NO, nitric oxide; PKG, protein kinase G; TM, trabecular meshwork.

Reprinted from *Nitric Oxide*, 77, Wareham LK, Buys ES, Sappington RM, The nitric oxide-guanylate cyclase pathway and glaucoma, 75-87, Copyright 2018, with permission from Elsevier.

The effect of LBN on IOP has been evaluated in a number of key glaucoma studies. The pivotal phase 3 APOLLO and LUNAR studies randomized subjects with open-angle glaucoma or ocular hypertension in a 2:1 ratio to receive either LBN dosed once daily or timolol, 0.5%, dosed twice daily for 3 months.^{18,19} Both studies were designed to evaluate the noninferiority of LBN to timolol as the primary end point. In a noninferiority trial, drug A is considered to be noninferior to drug B if drug A works at least as well (or better) than drug B. Intraocular pressure was measured at 8 AM, 12 PM, and 4 PM at baseline and at 2 weeks, 6 weeks, and 3 months after starting treatment. **Table 1** shows the IOP-lowering effects of the drugs in the APOLLO and LUNAR studies.¹⁹ In the APOLLO study, LBN provided statistically significantly greater IOP reductions than did timolol at all 9 time points. In the LUNAR study, LBN lowered IOP significantly more than did timolol at 8 out of 9 time points.¹⁸ Both drugs were associated with low rates of ocular irritation and conjunctival hyperemia.^{18,19} On the basis of these data, the US Food and Drug Administration approved LBN for the reduction of IOP in patients with open-angle glaucoma or ocular hypertension.²⁰ The US Food and Drug Administration–approved dose is 1 drop daily in the evening (qhs).

Table 1. Efficacy and Safety Outcomes of APOLLO and LUNAR Phase 3 Studies of LBN vs Timolol^{18,19}

	APOLLO		LUNAR	
	LBN (n = 284)	Timolol (n = 133)	LBN (n = 278)	Timolol (n = 136)
Baseline IOP, mm Hg	26.7	26.5	26.6	26.4
Mean IOP reductions, mm Hg	8.0-9.0	6.5-8.0	7.5-8.8	6.6-7.9
Significance	LBN > timolol at all 9 time points (P ≤ .002)		LBN > timolol at 8/9 time points (P ≤ .025)	
Common side effects				
Eye irritation, %	3.9	2.2	7.2	4.4
Conjunctival hyperemia, %	2.8	1.5	4.4	0.7

Abbreviations: IOP, intraocular pressure; LBN, latanoprostene bunod.

Additionally, the VOYAGER study was a phase 2 comparison of LBN with latanoprost (**Table 2**).²¹ In this dose-finding study, 4 concentrations of LBN, each dosed once daily at night, were compared with latanoprost, 0.005%, dosed once daily at night. Intraocular pressure was measured at 8 AM, 12 PM, and 4 PM at baseline and at 7, 14, and 28 days after starting treatment. Mean diurnal IOP reduction at the day 28 time point (the study's primary end point) was significantly greater in the LBN, 0.024%, group (the approved dose) than in the latanoprost group (9.00 mm Hg vs 7.77 mm Hg; P = .005). Although the concentration of latanoprost in each of the 4 LBN groups was greater than that in the latanoprost group, evidence suggests that increasing latanoprost concentration does not increase efficacy.²²

Netarsudil

Netarsudil is a novel drug in a new class of drugs known as Rho kinase inhibitors. Rho kinase is an enzyme that regulates the shape and movement of cells by acting on the cytoskeleton. In the eye, inhibition of Rho kinase leads to smooth muscle relaxation of both the trabecular meshwork and the episcleral veins. Thus, netarsudil acts to increase trabecular outflow by both increasing aqueous humor flow through the trabecular meshwork^{23,24} and reducing downstream resistance to flow by decreasing the pressure within the episcleral venous system.²³ In addition to inhibiting Rho kinase, netarsudil also inhibits the actions of a molecule called norepinephrine transporter. In doing so, netarsudil increases adrenergic activity within the eye, which in turn suppresses aqueous humor production. Thus, netarsudil lowers IOP by up to 3 distinct mechanisms at 3 locations within the eye.

The effects of netarsudil on IOP were evaluated in a series of clinical trials. The ROCKET-1 and ROCKET-2 studies were phase 3 comparisons of netarsudil, 0.02%, dosed once or twice daily and

Table 2. Efficacy and Safety Outcomes at Day 28 in the VOYAGER Phase 2 Study of LBN vs Latanoprost²¹

	LBN, 0.006% (n = 82)	LBN, 0.012% (n = 85)	LBN, 0.024% (n = 83)	LBN, 0.040% (n = 81)	Latanoprost (n = 82)
Baseline IOP, mm Hg	26.1	26.25	26.0	26.0	26.15
Mean IOP reductions, mm Hg	7.8	8.3	9.0	8.9	7.8
Significance vs latanoprost	.913	.258	.005	.009	—
Common side effects					
Eye irritation, %	1.2	2.4	3.6	6.2	0
Conjunctival hyperemia, %	1.2	3.6	4.8	3.7	0

Abbreviations: IOP, intraocular pressure; LBN, latanoprostene bunod.

timolol, 0.5%, dosed twice daily for 3 months.²⁵ Both studies were designed to establish noninferiority of netarsudil to timolol as the primary end point. Intraocular pressure was measured at 8 AM, 10 AM, and 4 PM at baseline and at 2 weeks, 6 weeks, and 3 months after starting treatment. **Table 3** shows the efficacy and safety outcomes of these studies. In ROCKET-1, mean IOP reductions in the timolol group were greater than those in the netarsudil once-daily group, and the criteria for noninferiority were not met. In a post hoc analysis of eyes with baseline IOP below 25 mm Hg, netarsudil once daily was statistically noninferior to timolol. In ROCKET-2, only eyes with baseline IOP below 25 mm Hg were included in the primary analysis. In this subset of eyes, once-daily netarsudil was also statistically noninferior to timolol. Netarsudil was associated with a substantially higher rate of hyperemia compared with timolol and with the development of both conjunctival hemorrhages and corneal verticillata. In addition, the

ROCKET-4 trial demonstrated noninferiority to timolol in patients with an IOP of up to < 30 mm Hg.²⁶ Safety data were consistent with observations in the ROCKET-1 and ROCKET-2 studies. The most common adverse event was hyperemia. These data led to the approval of netarsudil for the reduction of elevated IOP in patients with open-angle glaucoma or ocular hypertension.²⁷ Its approved dose is 1 drop daily in the evening (qhs).

In addition to these phase 3 studies, netarsudil was compared with latanoprost in a 28-day phase 2 study (also summarized in **Table 3**).²⁸ In this monotherapy study, subjects were randomly assigned to receive netarsudil or latanoprost, each dosed once daily. The primary end point was diurnal IOP reduction at day 28. At day 28, mean IOP reduction was 5.7 mm Hg for netarsudil and 6.8 mm Hg for latanoprost. In the statistical analysis, netarsudil was found to be inferior to latanoprost.

Table 3. Efficacy and Safety Outcomes of ROCKET-1 and ROCKET-2 Phase 3 Studies of Netarsudil vs Timolol²⁵ and the Phase 2 Study of Netarsudil vs Latanoprost²⁸

	ROCKET-1 (All Eyes)		ROCKET-1 (Eyes With IOP < 25 mm Hg)		ROCKET-2		Phase 2 Study	
	Netarsudil (n = 202)	Timolol (n = 209)	Netarsudil (n = 113)	Timolol (n = 124)	Netarsudil Once Daily (n = 251)	Timolol (n = 251)	Netarsudil, 0.02%* (n = 72)	Latanoprost (n = 77)
Baseline IOP, mm Hg	21.8-23.4	21.45-23.4	20.6-22.4	20.5-22.5	20.4-22.5	20.7-22.5	25.6	25.5
Mean IOP reductions, mm Hg	3.3-5.0	3.7-5.1	3.7-5.1	3.2-4.7	3.3-4.6	3.7-5.1	5.7	6.8
Significance	Netarsudil inferior to timolol		Netarsudil noninferior to timolol		Netarsudil noninferior to timolol		Netarsudil inferior to latanoprost	
Common side effects								
Conjunctival hyperemia, %	53.2	8.2	—	—	50.2	10.8	57.0	16.0
Conjunctival hemorrhage, %	13.3	0.5	—	—	14.7	0	6.0	0
Corneal verticillata, %	5.4	0	—	—	8.8	0.4	0 [†]	0 [†]

Abbreviation: IOP, intraocular pressure.

* Netarsudil, 0.02%, is the approved dose; additional doses were included in this study but not shown

† Short 28-day study precluded observation of corneal verticillata, which typically appears with longer dosing

NORMAL-TENSION GLAUCOMA:
AN OFTEN-OVERLOOKED DIAGNOSIS

Historically, POAG was considered to be caused by elevated IOP. Over time, it was observed that many people have classic glaucoma damage without IOP elevation. The term normal-tension glaucoma (NTG) was created to classify those patients who have the typical optic nerve and visual field abnormalities associated with POAG, but whose IOP is within the normal range (≤ 21 mm Hg). Given that there are no pathognomonic characteristics of NTG that distinguish it from POAG, it is likely that these are not different entities and that POAG exists across the full spectrum of IOP. However, for purposes of discussion, it remains useful to use the term NTG.

In the United States, approximately 50% of patients with open-angle glaucoma have IOP ≤ 21 mm Hg at the time of diagnosis.²⁹ Likewise, the Barbados Eye Study found that in people of African descent, approximately 54% of eyes with newly diagnosed glaucoma have IOP ≤ 21 mm Hg.³⁰ In Asia, NTG is far more common: 50% to 90% of all glaucoma cases are NTG, with an IOP ≤ 21 mm Hg.³¹ Still, it is not unusual to start therapy in these patients; the thinking is that they have normal-tension glaucoma and that elevated IOPs will appear later on as more visits and IOP measurements are collected.

Normal-tension glaucoma is diagnosed in the same manner as high-tension glaucoma, according to optic nerve and visual field damage. Without the red flag of elevated IOP, NTG will be detected on clinical examination only with a careful inspection of the optic nerve. Also, in the absence of elevated IOP, NTG becomes a diagnosis of exclusion, and a number of other conditions should be considered (Table 4). Some cases of NTG might actually be high-tension open-angle glaucoma, with intermittent IOP fluctuations above 21 mm Hg, particularly outside of typical office hours (eg, nighttime). Thin corneas, either natural or after refractive surgery, can artificially lower IOP measurements and mask true high IOP. Intermittent angle-closure glaucoma can also be mistaken for NTG if patients are seen only between subacute attacks, underscoring the importance of gonioscopy in the evaluation of suspected NTG. Historical IOP elevations with prior optic nerve damage can occur in a number of settings, including long-standing pigment dispersion syndrome/pigmentary glaucoma, with normalization of IOP occurring at the time of cataract formation and the reversal of reverse pupillary block, as well as prior trauma or the past use of steroids producing a now-resolved steroid IOP response.

Neurologic diseases can occasionally be confused with NTG, and the role of routine neuroimaging for cases of suspected NTG is often discussed. In fact, studies suggest that routine neuroimaging to rule out central nervous system lesions in eyes with NTG is generally nonproductive.³² Instead, neuroimaging should be reserved for cases in which the clinical findings are more consistent with a central lesion than with glaucoma. These findings include

Table 4. Differential Diagnosis of Normal-Tension Glaucoma

POAG with IOP fluctuations (including nocturnal elevations)
Thin central cornea with underestimation of IOP
Intermittent angle-closure glaucoma
Burned-out pigmentary glaucoma
Prior ocular trauma
Prior steroid use
Central nervous system lesions

Abbreviations: IOP, intraocular pressure; POAG, primary open-angle glaucoma.

optic nerve pallor rather than cupping, afferent pupillary defects out of proportion to cupping, color vision abnormalities, reductions in central visual acuity, visual field defects that respect the vertical meridian, and younger age.

Even though IOP is in the normal range in eyes with NTG, studies support the role of IOP reduction in reducing the risk of future progression. The Collaborative Normal-Tension Glaucoma Study randomized 145 patients with NTG to receive treatment or observation.^{33,34} The goal of treatment was to achieve a 30% IOP reduction using any means available, except that beta blockers and adrenergic agonists were not allowed because of their potential deleterious effects on ocular blood flow. After up to 8 years of follow-up, glaucoma progression was noted in 35% of untreated eyes and in only 12% of treated eyes ($P < .001$).³³ This protection from progression came at a cost, however, because the rate of cataract formation was significantly higher in the treatment group than in the observation group (35% vs 14%; $P = .001$).³⁴ In a separate study, eyes with NTG were randomized to receive either brimonidine, 0.2%, or timolol, 0.5%, each dosed twice daily.³⁵ Over a 4-year follow-up period, visual field progression was noted in 9.1% of brimonidine-treated eyes vs 39.2% of timolol-treated eyes ($P < .001$). However, discontinuation rates with assigned therapy were high: 10% of patients in the timolol group and 30% of patients in the brimonidine group discontinued therapy during the follow-up period.

As alluded to in the study design of the Collaborative Normal-Tension Glaucoma Study, ocular perfusion pressure (OPP) might have a role in the pathophysiology of NTG because the study precluded the use of drugs capable of unfavorably altering ocular blood flow.^{33,34} The role of OPP (the difference between blood pressure and IOP) in glaucoma remains controversial. Certainly, low OPP, particularly diastolic OPP, is a risk factor for the development of glaucoma.³⁶⁻⁴⁰ A role for OPP in the development of glaucoma is biologically plausible because low OPP indicates reduced perfusion of ocular tissues, which might contribute to hypoxia/ischemia of optic nerve tissue. Importantly, IOP is typically highest

at night when systemic blood pressure is typically lowest, resulting in low OPP.⁴¹ OPP is also potentially modifiable, most easily achieved by adjusting antihypertensive medications to avoid periods of hypotension.

THE ROLE OF NEW DRUGS IN EYES WITH NORMAL-TENSION GLAUCOMA

How effective are LBN and netarsudil in eyes with glaucoma and IOP in the normal range? The JUPITER study evaluated LBN in 130 Japanese patients with ocular hypertension or POAG (including NTG).⁴² Mean baseline IOP was 19.6 mm Hg—well within the normal range—in this single-arm, open-label study. Following 52 weeks of treatment, mean IOP was reduced by 22% ($P < .001$), and the most common adverse events were conjunctival hyperemia (17.7%), eyelash growth (16.2%), and ocular irritation/pain (11.5%/10%).

Netarsudil has also been evaluated in eyes with normal IOP. In a fellow-eye, placebo-controlled, randomized study, 11 healthy volunteers received netarsudil, 0.2%, once daily for 7 days in the randomly selected study eye and placebo drops in the fellow eye.²³ Mean diurnal IOP (the average of IOP at 1 PM and 3 PM) was reduced from 17.0 mm Hg to 12.4 mm Hg in the netarsudil eyes (27%) and from 16.7 mm Hg to 16.0 mm Hg (7.2%) in placebo eyes ($P < .0001$). These IOP changes in the netarsudil-treated eyes were associated with a statistically significant increase in mean diurnal trabecular outflow facility ($P = .004$), decrease in mean diurnal episcleral venous pressure ($P = .01$), a trend toward a lower aqueous humor production rate ($P = .08$), and no change in mean diurnal uveoscleral outflow ($P = .2$) compared with baseline values. Conjunctival hyperemia was seen in all 11 netarsudil-treated eyes. The post hoc analysis of ROCKET-1 data in eyes with lower baseline IOP (range, 20.6–22.4 mm Hg) also demonstrated the IOP-lowering efficacy of netarsudil (Table 3).²⁵

CASE 1: EARLY GLAUCOMA WITH MODERATELY ELEVATED INTRAOCULAR PRESSURE

A 56-year-old Asian female is referred for evaluation of optic nerve cupping suggestive of glaucomatous optic neuropathy. She is in good general health and uses only over-the-counter multivitamins and fish oil supplements. She has a history of low myopia and presbyopia, which are well corrected with spectacles. Her anterior segment examination is unremarkable. Her IOP is 22 mm Hg OD and 24 mm Hg OS. Her central corneal thickness is 585 μ m OD and 579 μ m OS. Her angles are open on gonioscopy. Figure 2 shows

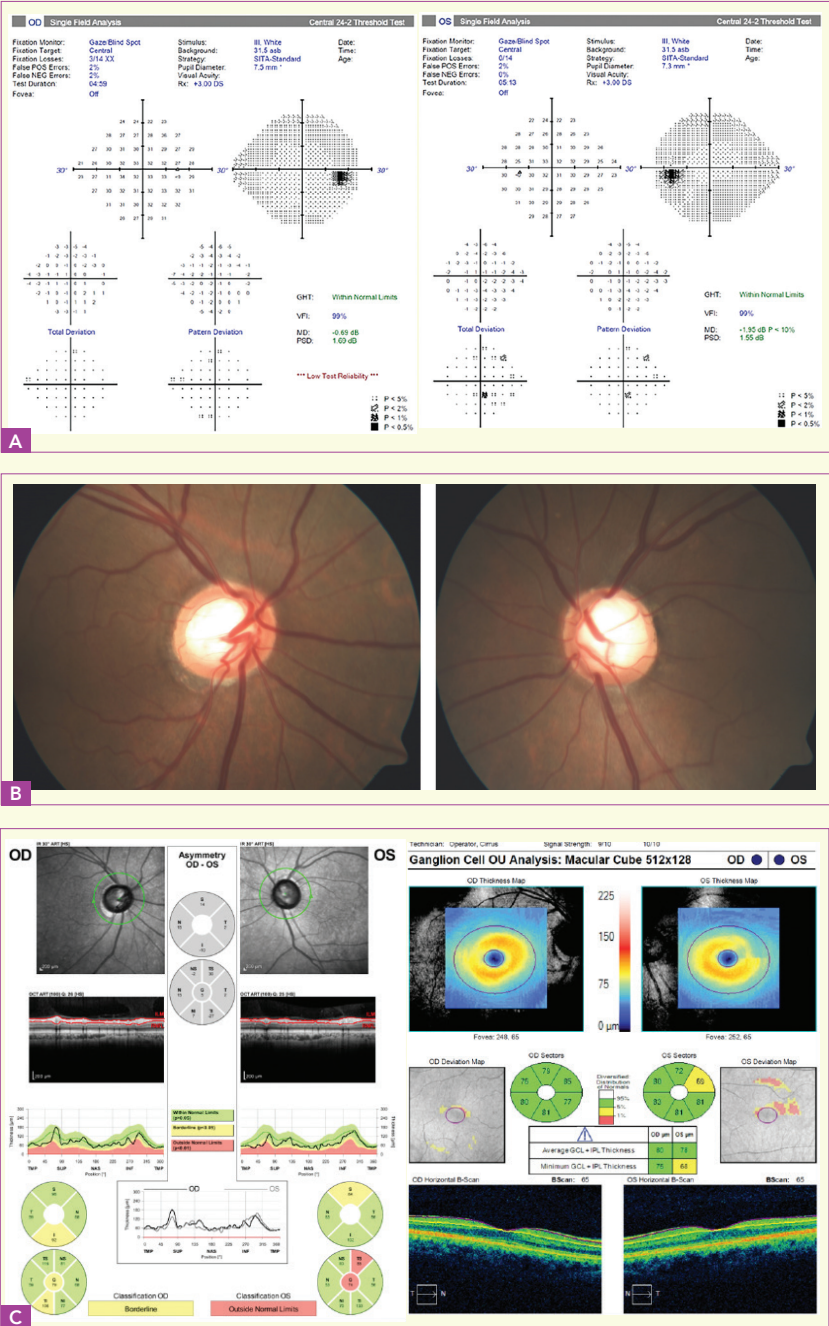


Figure 2. Visual fields (A), optic nerves (B), and retinal nerve fiber layer and macular optical coherence tomography images (C) of the patient presented in Case 1
Images courtesy of Michael Chaglasian, OD

her visual fields, optic nerves, and optical coherence tomography (OCT) images of the retinal nerve fiber layer (RNFL) and macular ganglion cell layer and inner plexiform layer.

The optic nerves exhibit large cups in both eyes. Most notably, there is rim thinning superotemporally in the right eye, with an associated RNFL bundle defect visible in the peripapillary retina. This RNFL defect is also visible on the RNFL and macular OCT images of the left eye and is associated with a subtle inferior arcuate defect in the visual field of the left eye.

The patient is brought back for several additional IOP assessments and to repeat the 24-2 visual field test and perform the 10-2 visual field test. The results of these additional studies reveal a reproducible inferior field defect in the left eye and IOP in the 20 to 24 mm Hg range in both eyes when measured at different times of the day.

This patient has an early case of POAG, with moderately elevated IOP. According to clinical guidelines, the therapeutic goal is a 25% IOP reduction from baseline,⁴³ setting her target IOP at 18 mm Hg or less from her peak of 24 mm Hg. After a discussion with the patient of various initial treatment options, generic latanoprost therapy is initiated. Over the next 2 visits, her IOPs are in the range of 19 to 21 mm Hg, representing reductions of only 10% to 15% from baseline. Treatment options at this time include adding a second agent vs switching to an alternate single agent.

In general, when the first agent produces the expected therapeutic efficacy and is well tolerated, a second agent should be added; treatment should be switched when the first agent does not yield these results. Although she tolerated the latanoprost well, it underperformed expectations; latanoprost typically delivers 30% to 35% IOP reductions.⁴⁴ Had latanoprost delivered its expected efficacy but the patient was still a few points short of her target IOP, adding a second agent, perhaps a beta blocker, a carbonic anhydrase inhibitor, an adrenergic agonist, LBN, or netarsudil, could be considered. Because it underperformed, however, latanoprost was discontinued and an alternate single agent was considered. Options included a prostaglandin analogue, timolol, and LBN.

One consideration when drugs fail to perform as expected is the issue of adherence to therapy. It is well known that adherence to glaucoma therapy is less than ideal, with patients frequently missing doses of IOP-lowering medications.⁴⁵ Improving adherence is a significant clinical challenge. Strategies that can improve adherence include increasing face-to-face time with patients and educating them about glaucoma and the risk of blindness.⁴⁶ Other strategies might include:

- Simplifying the regimen
- Considering nonmedical interventions
 - o Selective laser trabeculoplasty
 - o Combined cataract-glaucoma surgery
 - o Traditional glaucoma surgery: trabeculectomy/tube shunt
 - o Minimally invasive glaucoma surgery

CASE 2: GLAUCOMA INADEQUATELY CONTROLLED WITH PROSTAGLANDIN MONOTHERAPY

A 42-year-old African American male is referred for evaluation of suspected glaucoma based on elevated IOP. He has a positive family history of glaucoma. His only systemic medical issue is asthma, for which he periodically uses an albuterol inhaler. On examination, his uncorrected distance visual acuity is 20/20 in both eyes. His anterior segment examination is unremarkable. His IOP at the first encounter is 27 mm Hg OD and 24 mm Hg OS. On a

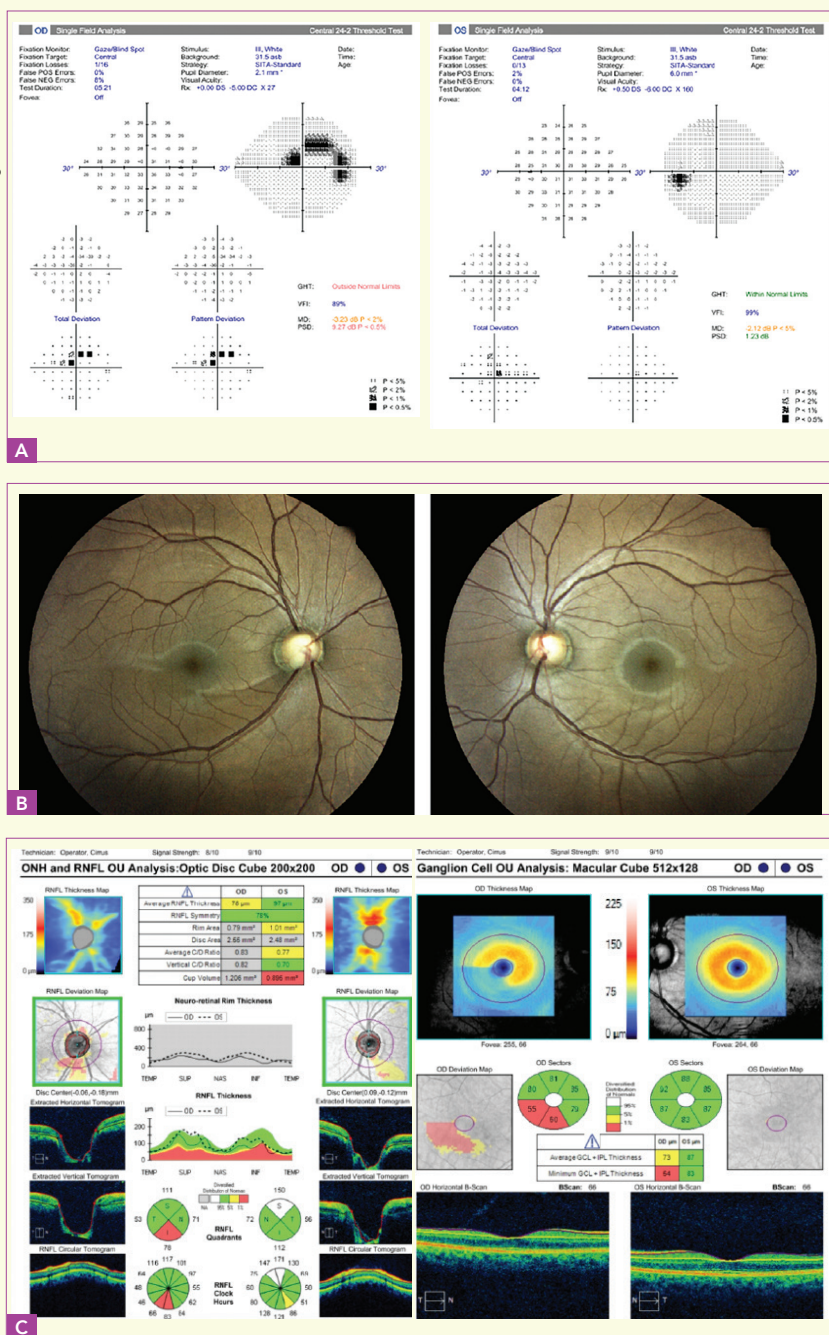


Figure 3. Visual fields (A), optic nerves (B), and retinal nerve fiber layer and macular optical coherence tomography images (C) of the patient presented in Case 2

Images courtesy of Michael Chaglasian, OD

subsequent visit, his IOP is 28 mm Hg OD and 24 mm Hg OS. His angles are open on gonioscopy. Central corneal thickness is 531 μm OD and 545 μm OS. **Figure 3** shows his visual fields, optic nerves, and RNFL and macular OCT images.

The optic nerve photographs reveal large cups with thin rims, particularly in the right eye, where a wide inferior RNFL defect is visible. This correlates well with the RNFL OCT and macular OCT, both of which show loss of the RNFL and the ganglion cell layer and inner plexiform layer, respectively, in the right eye. An RNFL defect, which is less pronounced, is also seen on the retinal photographs and OCT in the left eye. This structural damage has produced a dense superior arcuate defect in the right visual field. In all these studies, the left eye remains structurally and functionally intact. Although the left optic nerve does have a large cup, this can be a normal finding in people of African descent, who have larger optic nerve heads and larger cups than do whites.⁴⁷ Interestingly, this difference in optic nerve head size should be present since birth.⁴⁸ In this case, the large cup is not physiologic, but rather related to glaucoma.

This patient has POAG and requires IOP reduction. Although a 25% IOP reduction is a reasonable goal for initial therapy in many patients with glaucoma, the presence of risk factors for progression and vision loss often justify a greater initial IOP reduction.⁴³ In this case, the patient is young (42 years old), African American (which increases his risk for progression, vision loss, and blindness⁴⁹), and has advanced disease. A target IOP of 16 mm Hg, representing an approximately 40% IOP reduction, is set.

The patient begins treatment with a generic prostaglandin analogue. After 3 months, he reports good adherence and no significant side effects. His IOP is 19 mm Hg OD and 18 mm Hg OS. Although this represents an approximately 30% reduction from untreated baseline IOP in the right eye, he has not achieved his target IOP. Options for the next step of therapy include switching to a different monotherapy or adding a second agent. On average, LBN delivers an approximately 1.2-mm Hg additional IOP reduction compared with latanoprost alone and might be a reasonable alternate first-line agent to close the gap between current IOP and target IOP. On the other hand, because the primary therapy delivered its expected therapeutic efficacy, it could be maintained and a second agent could be added. Options for a second-line agent include a beta blocker, a carbonic anhydrase inhibitor, an adrenergic agonist, and netarsudil.

CASE 3: A NEW DIAGNOSIS OF NORMAL-TENSION GLAUCOMA

A 72-year-old African American male presents for a comprehensive eye examination. He complains of slightly reduced distance vision. His medical history is significant only for systemic hypertension, for which he takes a beta blocker, a calcium channel blocker, and a diuretic. On examination, he is easily refracted to 20/20 OU, with a low hyperopic correction. His anterior segments are remarkable only for early nuclear sclerotic changes of both lenses. His IOP is

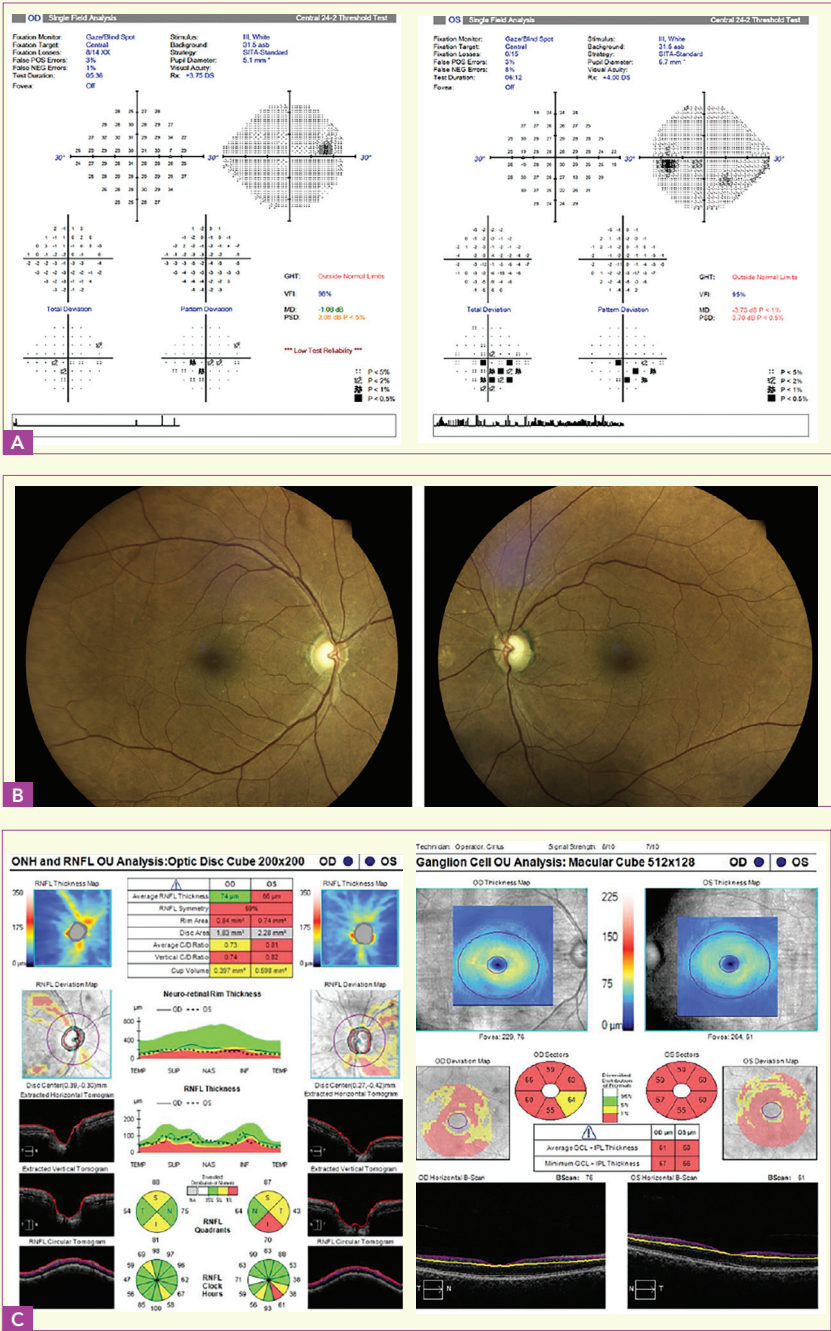


Figure 4. Visual fields (A), optic nerves (B), and retinal nerve fiber layer and macular optical coherence tomography images (C) of the patient presented in Case 3

Images courtesy of Murray Fingeret, OD

17 mm Hg OD and 19 mm Hg OS. His corneas are thick at 600 μ m OU. His angles are open on gonioscopy. **Figure 4** shows his visual fields, optic nerves, and RNFL and macular OCT images.

In the right eye, the disc photograph shows a generous cup, with a small notch superiorly and a narrow RNFL bundle defect just inferior to the superotemporal branch of the central retinal vein. The average superior RNFL thickness is borderline on OCT, and an inferior arcuate scotoma is seen on the visual field. There also appears to be a notch inferiorly, with an RNFL bundle defect; the RNFL OCT is also borderline inferiorly. The macular OCT is globally abnormal. The superior visual field, however, remains intact.

In the left eye, the superior rim of the optic nerve appears to be thin, and RNFL bundle defects are visible both superiorly and inferiorly on the fundus photograph. The RNFL OCT is abnormal inferiorly and borderline superiorly. The visual field shows an inferior arcuate scotoma, and the macular OCT is globally abnormal.

This patient has open-angle glaucoma with normal IOP and visual field loss in both eyes. This open-angle glaucoma might be either NTG or POAG, with IOP reduced because of use of an oral beta blocker for blood pressure control. On a follow-up visit, the IOP remains normal at 16 mm Hg OD and 18 mm Hg OS.

Based on guidance from the Collaborative Normal-Tension Glaucoma Study,^{33,34} a 30% reduction in IOP is set as the therapeutic goal, indicating a target IOP of 12 to 13 mm Hg OU. Generic latanoprost therapy is initiated, and 1 month later, IOP is 14 mm Hg OU. At a recheck 1 week later, IOP is 15 mm Hg OU. Because there was a moderate response to latanoprost, it was continued and the fixed-combination dorzolamide/timolol was added. Target IOP of 12 to 13 mm Hg was achieved and maintained for the next 3 years. Despite this level of IOP control, both the visual field and the OCT demonstrated reproducible changes in both eyes over the 3-year period. The possibility of low OPP was considered, given the patient is on triple therapy for systemic hypertension. Ultimately, on the basis of a study demonstrating the benefits of achieving single-digit IOP levels in eyes progressing at low IOP,⁵⁰ the patient was referred for surgery.

SUMMARY AND TAKE-HOME POINTS

- Intraocular pressure is determined by the balance between aqueous humor production and aqueous humor outflow
- Aqueous humor exits the eye through both the trabecular and uveoscleral outflow pathways
- Intraocular pressure is elevated in glaucomatous eyes primarily because of impairment of aqueous humor outflow through the trabecular outflow pathway
- Two new drugs—LBN and netarsudil—lower IOP by direct actions in the trabecular meshwork to improve trabecular outflow

- o Latanoprostene bunod is an NO-donating form of latanoprost; it lowers IOP by increasing uveoscleral outflow (via latanoprost) and trabecular outflow (via NO)
- o Netarsudil is a Rho kinase inhibitor and a norepinephrine transporter inhibitor; it lowers IOP by increasing trabecular outflow, reducing episcleral venous pressure, and reducing the production rate of aqueous humor
- Normal-tension glaucoma is a common form of POAG in which IOP is in the normal range
- Intraocular pressure reduction effectively lowers the risk of progression in eyes with NTG
- Both LBN and netarsudil effectively lower IOP in eyes with low baseline IOP
- Latanoprostene bunod will be used as a primary agent because of its IOP efficacy, whereas netarsudil will be used as a second-line agent to supplement primary therapy

REFERENCES

1. To CH, Kong CW, Chan CY, Shahidullah M, Do CW. The mechanism of aqueous humour formation. *Clin Exp Optom*. 2002;85(6):335-349.
2. Goel M, Picciani RG, Lee RK, Bhattacharya SK. Aqueous humor dynamics: a review. *Open Ophthalmol J*. 2010;4:52-59.
3. Carreon T, van der Merwe E, Fellman RL, Johnstone M, Bhattacharya SK. Aqueous outflow - a continuum from trabecular meshwork to episcleral veins. *Prog Retin Eye Res*. 2017;57:108-133.
4. Johnson M, McLaren JW, Overby DR. Unconventional aqueous humor outflow: a review. *Exp Eye Res*. 2017;158:94-111.
5. Grant WM. Clinical measurements of aqueous outflow. *AMA Arch Ophthalmol*. 1951;46(2):113-131.
6. Toris CB, Koepsell SA, Yablonski ME, Camras CB. Aqueous humor dynamics in ocular hypertensive patients. *J Glaucoma*. 2002;11(3):253-258.
7. Larsson LI, Rettig ES, Brubaker RF. Aqueous flow in open-angle glaucoma. *Arch Ophthalmol*. 1995;113(3):283-286.
8. Brubaker RF. Flow of aqueous humor in humans [The Friedenwald Lecture]. *Invest Ophthalmol Vis Sci*. 1991;32(13):3145-3166.
9. Cavet ME, Vittitow JL, Impagnatiello F, Ongini E, Bastia E. Nitric oxide (NO): an emerging target for the treatment of glaucoma. *Invest Ophthalmol Vis Sci*. 2014;55(8):5005-5015.
10. Steinhorn BS, Loscalzo J, Michel T. Nitroglycerin and nitric oxide—a rondo of themes in cardiovascular therapeutics. *N Engl J Med*. 2015;373(3):277-280.
11. Palmer RM, Ferrige AG, Moncada S. Nitric oxide release accounts for the biological activity of endothelium-derived relaxing factor. *Nature*. 1987;327(6122):524-526.
12. Becquet F, Courtois Y, Goureau O. Nitric oxide in the eye: multifaceted roles and diverse outcomes. *Surv Ophthalmol*. 1997;42(1):71-82.
13. Nathanson JA, McKee M. Identification of an extensive system of nitric oxide-producing cells in the ciliary muscle and outflow pathway of the human eye. *Invest Ophthalmol Vis Sci*. 1995;36(9):1765-1773.
14. Dismuke WM, Mbadugha CC, Ellis DZ. NO-induced regulation of human trabecular meshwork cell volume and aqueous humor outflow facility involve the BKCa ion channel. *Am J Physiol Cell Physiol*. 2008;294(6):C1378-C1386.
15. Wiederholt M, Thieme H, Stumpff F. The regulation of trabecular meshwork and ciliary muscle contractility. *Prog Retin Eye Res*. 2000;19(3):271-295.

16. Wareham LK, Buys ES, Sappington RM. The nitric oxide-guanylate cyclase pathway and glaucoma. *Nitric Oxide*. 2018;77:75-87.
17. Cavet ME, DeCory HH. The role of nitric oxide in the intraocular pressure lowering efficacy of latanoprostene bunod: review of nonclinical studies. *J Ocul Pharmacol Ther*. 2018;34(1-2):52-60.
18. Weinreb RN, Scassellati Sforzolini B, Vittitow J, Liebmman J. Latanoprostene bunod 0.024% versus timolol maleate 0.5% in subjects with open-angle glaucoma or ocular hypertension: the APOLLO study. *Ophthalmology*. 2016;123(5):965-973.
19. Medeiros FA, Martin KR, Peace J, Scassellati Sforzolini B, Vittitow JL, Weinreb RN. Comparison of latanoprostene bunod 0.024% and timolol maleate 0.5% in open-angle glaucoma or ocular hypertension: the LUNAR study. *Am J Ophthalmol*. 2016;168:250-259.
20. Vyzulta [package insert]. Bridgewater, NJ: Bausch & Lomb Incorporated; 2017.
21. Weinreb RN, Ong T, Scassellati Sforzolini B, Vittitow JL, Singh K, Kaufman PL; VOYAGER Study Group. A randomised, controlled comparison of latanoprostene bunod and latanoprost 0.005% in the treatment of ocular hypertension and open angle glaucoma: the VOYAGER study. *Br J Ophthalmol*. 2015;99(6):738-745.
22. Eveleth D, Starita C, Tressler C. A 4-week, dose-ranging study comparing the efficacy, safety and tolerability of latanoprost 75, 100 and 125 µg/mL to latanoprost 50 µg/mL (Xalatan) in the treatment of primary open-angle glaucoma and ocular hypertension. *BMC Ophthalmol*. 2012;12:9.
23. Kazemi A, McLaren JW, Kopczynski CC, Heah TG, Novack GD, Sit AJ. The effects of netarsudil ophthalmic solution on aqueous humor dynamics in a randomized study in humans. *J Ocul Pharmacol Ther*. 2018;34(5):380-386.
24. Wang RF, Williamson JE, Kopczynski C, Serle JB. Effect of 0.04% AR-13324, a ROCK, and norepinephrine transporter inhibitor, on aqueous humor dynamics in normotensive monkey eyes. *J Glaucoma*. 2015;24(1):51-54.
25. Serle JB, Katz LJ, McLaurin E, et al; ROCKET-1 and ROCKET-2 Study Groups. Two phase 3 clinical trials comparing the safety and efficacy of netarsudil to timolol in patients with elevated intraocular pressure: Rho Kinase Elevated IOP Treatment Trial 1 and 2 (ROCKET-1 and ROCKET-2). *Am J Ophthalmol*. 2018;186:116-127.
26. Business Wire. Aerie Pharmaceuticals reports positive Rocket 4 six-month topline safety and efficacy results for Rhopressa™ (netarsudil ophthalmic solution) 0.02% [press release]. <https://www.businesswire.com/news/home/20170412006000/en/>. Published April 12, 2017. Accessed August 27, 2018.
27. Rhopressa [package insert]. Irvine, CA: Aerie Pharmaceuticals, Inc; 2017.
28. Bacharach J, Dubiner HB, Levy B, Kopczynski CC, Novack GD; AR-13324-CS202 Study Group. Double-masked, randomized, dose-response study of AR-13324 versus latanoprost in patients with elevated intraocular pressure. *Ophthalmology*. 2015;122(2):302-307.
29. Sommer A, Tielsch JM, Katz J, et al. Relationship between intraocular pressure and primary open angle glaucoma among white and black Americans. The Baltimore Eye Survey. *Arch Ophthalmol*. 1991;109(8):1090-1095.
30. Nemesure B, Honkanen R, Hennis A, Wu SY, Leske MC; Barbados Eye Studies Group. Incident open-angle glaucoma and intraocular pressure. *Ophthalmology*. 2007;114(10):1810-1815.
31. Cho HK, Kee C. Population-based glaucoma prevalence studies in Asians. *Surv Ophthalmol*. 2014;59(4):434-447.
32. Greenfield DS, Siatkowski RM, Glaser JS, Schatz NJ, Parrish RK 2nd. The cupped disc. Who needs neuroimaging? *Ophthalmology*. 1998;105(10):1866-1874.
33. Collaborative Normal-Tension Glaucoma Study Group. Comparison of glaucomatous progression between untreated patients with normal-tension glaucoma and patients with therapeutically reduced intraocular pressures. *Am J Ophthalmol*. 1998;126(4):487-497.
34. Collaborative Normal-Tension Glaucoma Study Group. The effectiveness of intraocular pressure reduction in the treatment of normal-tension glaucoma. *Am J Ophthalmol*. 1998;126(4):498-505.
35. Krupin T, Liebmman JM, Greenfield DS, Ritch R, Gardiner S; Low-Pressure Glaucoma Study Group. A randomized trial of brimonidine versus timolol in preserving visual function: results from the Low-Pressure Glaucoma Treatment Study. *Am J Ophthalmol*. 2011;151(4):671-681.
36. Memarzadeh F, Ying-Lai M, Chung J, Azen SP, Varma R; Los Angeles Latino Eye Study Group. Blood pressure, perfusion pressure, and open-angle glaucoma: the Los Angeles Latino Eye Study. *Invest Ophthalmol Vis Sci*. 2010;51(6):2872-2877.
37. Leske MC, Wu SY, Nemesure B, Hennis A. Incident open-angle glaucoma and blood pressure. *Arch Ophthalmol*. 2002;120(7):954-959.
38. Bonomi L, Marchini G, Marraffa M, Bernardi P, Morbio R, Varotto A. Vascular risk factors for primary open angle glaucoma: the Egna-Neumarkt Study. *Ophthalmology*. 2000;107(6):1287-1293.
39. Tielsch JM, Katz J, Sommer A, Quigley HA, Javitt JC. Hypertension, perfusion pressure, and primary open-angle glaucoma. A population-based assessment. *Arch Ophthalmol*. 1995;113(2):216-221.
40. Quigley HA, West SK, Rodriguez J, Munoz B, Klein R, Snyder R. The prevalence of glaucoma in a population-based study of Hispanic subjects: Proyecto VER. *Arch Ophthalmol*. 2001;119(12):1819-1826.
41. Costa VP, Jimenez-Roman J, Carrasco FG, Lupinacci A, Harris A. Twenty-four-hour ocular perfusion pressure in primary open-angle glaucoma. *Br J Ophthalmol*. 2010;94(10):1291-1294.
42. Kawase K, Vittitow JL, Weinreb RN, Araie M; JUPITER Study Group. Long-term safety and efficacy of latanoprostene bunod 0.024% in Japanese subjects with open-angle glaucoma or ocular hypertension: the JUPITER study. *Adv Ther*. 2016;33(9):1612-1627.
43. American Academy of Ophthalmology. *Preferred Practice Pattern®. Primary Open-Angle Glaucoma*. San Francisco, CA: American Academy of Ophthalmology; 2015.
44. Alm A, Camras CB, Watson PG. Phase III latanoprost studies in Scandinavia, the United Kingdom and the United States. *Surv Ophthalmol*. 1997;41(suppl 2):S105-S110.
45. Schwartz GF. Compliance and persistency in glaucoma follow-up treatment. *Curr Opin Ophthalmol*. 2005;16(2):114-121.
46. Newman-Casey PA, Dayno M, Robin AL. Systematic review of educational interventions to improve glaucoma medication adherence: an update in 2015. *Expert Rev Ophthalmol*. 2016;11(1):5-20.
47. Varma R, Tielsch JM, Quigley HA, et al. Race-, age-, gender-, and refractive error-related differences in the normal optic disc. *Arch Ophthalmol*. 1994;112(8):1068-1076.
48. Allingham MJ, Cabrebra MT, O'Connell RV, et al. Racial variation in optic nerve head parameters quantified in healthy newborns by handheld spectral domain optical coherence tomography. *J AAPOS*. 2013;17(5):501-506.
49. Sommer A, Tielsch JM, Katz J, et al. Racial differences in the cause-specific prevalence of blindness in East Baltimore. *N Engl J Med*. 1991;325(20):1412-1417.
50. Iverson SM, Schultz SK, Shi W, Feuer WJ, Greenfield DS. Effectiveness of single-digit IOP targets on decreasing global and localized visual field progression after filtration surgery in eyes with progressive normal-tension glaucoma. *J Glaucoma*. 2016;25(5):408-414.



CE POST TEST QUESTIONS

To obtain COPE CE Credit for this activity, read the material in its entirety and consult referenced sources as necessary.

We offer instant certificate processing and support Green CE. Please take this post test and evaluation online by going to <http://tinyurl.com/manageglaucomaCE>. Upon passing, you will receive your certificate immediately. You must score 70% or higher to receive credit for this activity, and may take the test up to 2 times.

1. Where is aqueous humor produced?
 - a. Pigmented cells of the ciliary processes
 - b. Uveoscleral meshwork
 - c. Nonpigmented cells of the ciliary processes
 - d. Schlemm canal
2. What is the primary pathway for aqueous humor to exit the eye?
 - a. Trabecular outflow pathway
 - b. Vortex veins
 - c. Ciliary processes
 - d. Uveoscleral outflow pathway
3. The trabecular meshwork consists of ____ distinct layer(s).
 - a. 1
 - b. 2
 - c. 3
 - d. 4
4. Components of the uveoscleral pathway include the ciliary body, suprachoroidal space, and _____.
 - a. Ciliary processes
 - b. Episcleral venous system
 - c. Posterior chamber
 - d. Choroid
5. Nitric oxide lowers IOP by:
 - a. Increasing uveoscleral outflow
 - b. Decreasing aqueous humor production
 - c. Relaxing cells in the trabecular meshwork via inhibition of actin-myosin interactions
 - d. Inhibiting the norepinephrine transporter
6. Latanoprostene bunod lowers IOP by:
 - a. Increasing uveoscleral outflow and reducing aqueous humor production
 - b. Increasing uveoscleral and trabecular outflow
 - c. Increasing trabecular outflow and decreasing episcleral venous pressure
 - d. Decreasing aqueous humor production and decreasing uveoscleral outflow
7. In clinical trials, latanoprostene bunod lowered IOP by ____ mm Hg.
 - a. 3.3 to 5.1
 - b. 4.7 to 6.8
 - c. 6.5 to 8.0
 - d. 7.5 to 9.0
8. Common side effects of latanoprostene bunod include:
 - a. Blurred vision and conjunctival hyperemia
 - b. Eye irritation and conjunctival hyperemia
 - c. Corneal verticillata and conjunctival hemorrhages
 - d. Fatigue
9. Netarsudil is an inhibitor of:
 - a. Rho kinase and carbonic anhydrase
 - b. Nitric oxide and norepinephrine transporter
 - c. Nitric oxide and carbonic anhydrase
 - d. Rho kinase and norepinephrine transporter
10. Netarsudil lowers IOP by:
 - a. Increasing trabecular outflow
 - b. Decreasing episcleral venous pressure
 - c. Decreasing aqueous humor production
 - d. All the above
11. In clinical trials, netarsudil lowered IOP by ____ mm Hg.
 - a. 1.4 to 3.5
 - b. 3.3 to 5.1
 - c. 4.7 to 6.7
 - d. 5.5 to 8.0
12. OPP, which might play a role in the pathophysiology of glaucoma, is defined as:
 - A. Systolic blood pressure minus diastolic blood pressure
 - B. Episcleral venous pressure minus IOP
 - C. Nocturnal IOP minus diurnal IOP
 - D. Systemic blood pressure minus IOP
13. Approximately ____ of open-angle glaucoma cases in the United States are of the normal-tension variety.
 - a. 25%
 - b. 50%
 - c. 75%
 - d. 90%
14. Primary open-angle glaucoma can mimic NTG in the setting of _____.
 - a. Iritis
 - b. IOP fluctuations
 - c. Cataract
 - d. Presbyopia
15. Neuroimaging should be considered for patients with suspected NTG who also have _____.
 - a. 20/20 visual acuity
 - b. Optic nerve cupping
 - c. Pigment dispersion syndrome
 - d. Abnormal color vision
16. According to the findings of the Collaborative Normal-Tension Glaucoma Study, what is the therapeutic goal for treating normal-tension glaucoma?
 - a. 20% IOP reduction
 - b. 25% IOP reduction
 - c. 30% IOP reduction
 - d. 40% IOP reduction
17. A patient with newly diagnosed advanced glaucoma has an IOP of 27 mm Hg. The target IOP is set at 16 mm Hg. A trial of a generic prostaglandin analogue achieves an IOP of 20 mm Hg. What is the next best step?
 - a. Accept the current IOP and continue current therapy
 - b. Switch to a different monotherapy
 - c. Add a second drug to the prostaglandin analogue
 - d. Refer the patient for surgery
18. A patient with newly diagnosed early glaucoma has an IOP of 24 mm Hg. The target IOP is set at 18 mm Hg. A trial of a generic prostaglandin analogue achieves an IOP of 22 mm Hg. What is the next best step?
 - a. Accept the current IOP and continue current therapy
 - b. Switch to an alternate monotherapy from a different drug class
 - c. Add a second drug to the prostaglandin analogue
 - d. Refer the patient for surgery
19. With regard to glaucoma evaluation, in what important way do the eyes of people of African descent differ from the eyes of whites?
 - a. They produce more aqueous humor
 - b. They have greater IOP fluctuations
 - c. They have larger optic nerves and optic cups
 - d. They have higher OPP
20. Strategies for improving patient adherence with glaucoma therapy include:
 - a. More face-to-face time with the optometrist and more glaucoma education
 - b. Performing more visual field tests
 - c. Setting a lower target IOP
 - d. Choosing drugs that increase trabecular outflow