

Mandibular Subapical Osteotomies

Paulo Jose Medeiros and Fabio G. Ritto

Armamentarium

#15 Scalpel blade	Handpiece, #701, #702, #703 burs	Obwegeser retractors (up, down, and ramus)
Appropriate sutures	Kocher's forceps	Periosteal elevator
Bite block	Local anesthetic with vasoconstrictor	Smith spreader
Chisels (thin spatula and large ones)	Mallet	Weider retractor
Curved hemostats	Metzenbaum scissors	Wire cutter
Dietrich tissue forceps	Minnesota retractor	Wires (24 and 26 gauge)
Electrocautery	Needle holder	
Frasier suction tip	Obwegeser channel retractor	

History of the Procedure

Surgeries of the alveolar segments were probably the first techniques described to correct occlusal deformities. Kostecka¹ and Wassmund² were the pioneers of the technique, and other surgeons, such as Bell and Dann³ and Kent and Hinds,⁴ established details regarding indications and management. Most important, Bell and Levy,⁵ Castelli et al,⁶ and Hellem and Ostrup⁷ studied the blood supply to the osteotomized segment. Epker⁸ also pointed out some important details that must be taken into consideration to avoid tooth loss and avascular necrosis, which he considered the most devastating complications.

Hofer⁹ and Köle¹⁰ were probably the first to describe the mandibular subapical osteotomy technique. They recommended operating the models before actual surgery to achieve favorable occlusion and to fabricate the surgical splint. Hofer⁹ proposed a technique to treat the prognathism with the incision located in the buccal gingiva. Harming the mental nerve was not a concern, and correction of the occlusion was limited to tilt the alveolar segment. On the other hand, Köle¹⁰ positioned the anterior incision in the vestibule so that the mobilized segment remained covered by mucosa and the nerve remained sound. The posterior portion of the incision was placed over the alveolar ridge and along the lingual gingival margin to the retromandibular triangle, with vertical extension provided medianward. According to the author, this extensive incision permitted elongation of the mobilized mucosa, allowing for protrusion, and not merely tilting, of the osteotomized bone.

In 1974 MacIntosh¹¹ was the first to describe the total mandibular subapical osteotomy. In this description, the author recommended an extraoral approach to perform the vertical bone cut behind the last molar in cases of micrognathia complicated by limited mouth opening. In 1980 Epker and Wolford¹² published a book that presented great improvements on this technique, combining a sagittal osteotomy with the total mandibular subapical osteotomy.

Indications for the Use of the Procedure

Mandibular subapical osteotomies are not the most common choices to treat patients with dentofacial deformity. However, the anterior subapical osteotomy is a very versatile technique that allows the osteotomized segment to be moved in different directions. It is possible to set the anterior segment backward, forward, upward, and downward, depending on the need. Also, this type of osteotomy may be performed along with a bilateral sagittal split osteotomy (BSSO). According to Bell and Legan¹³ and Wolford and Moening,¹⁴ the mandibular anterior subapical osteotomy may be indicated to (1) level the occlusion, (2) produce anteroposterior changes of the osteotomized segment, (3) correct crowding in the lower anterior arch, (4) correct anterior dentoalveolar asymmetries, (5) alter the axial inclination of the anterior teeth, (6) reduce treatment time, and (7) improve treatment stability.

As described by MacIntosh¹¹ in 1974, the total subapical osteotomy of the mandible was indicated primarily to treat

infantile apertognathia. Other indications pointed out by MacIntosh¹¹ included treatment of retrognathia due to relapse of a previous ramus surgery and treatment of condylar agenesis/hypogenesis. Currently, the main indication for this technique is to correct a dentoalveolar retrusion in a “normal” mandible. With this technique, it is possible to correct an overjet discrepancy without affecting the position of the pogonion. However, the technique is extremely harmful to the inferior alveolar neurovascular bundle, often leading to dysesthesia and paresthesia. Furthermore, it poses a threat to the blood supply of the osteotomized bone.¹⁴

Finally, the posterior mandibular subapical osteotomy presents the single indication of repositioning an extruded posterior segment into proper relationship with the remaining occlusion, creating adequate space for esthetic and functional restoration. In the past, this osteotomy had also been indicated to close a dentoalveolar space, in the absence of a molar or premolar tooth, by advancing the mobilized segment. However, with the advance of dental implants, these absences are best treated with implant rehabilitation. Because it is necessary to detach most of the buccal mucosa to expose the bone and because of the tenacious mucosa that lies in the lingual bone in this region, there is a high risk of avascular necrosis. For these reasons, this technique should be mostly avoided.

Limitations and Contraindications

All segmental osteotomies in the maxillary bones share some potential complications, which may be mild, moderate, or severe. As proposed by Epker,⁸ mild complications include periodontal defects, pulp necrosis, infection, and delayed union. Moderate complications may include infection, delayed union, and malunion. Severe complications include nonunion and tooth and/or bone loss.

Because the mandible presents a thick cortical bone, the blood supply may be threatened after soft tissue detachment. Therefore, osteotomies that involve small segments of bone, with one or two teeth mobilized, should be discouraged. Also, because the soft tissue pedicle attached to the mobilized segment is the exclusive blood supply, the more it is mobilized or manipulated surgically and the further it is repositioned, the greater the potential for detachment of the pedicle and thus compromise of its vasculature.¹⁴

The anterior subapical osteotomy is mostly contraindicated when the anterior mandible is short in height. In some cases the apices of the anterior teeth, especially the canines, are close to the inferior border of the mandible, impeding performance of the osteotomy. Even if enough space is available to complete the osteotomy, at least 1 cm of basilar bone should remain to ensure the integrity of the mandible.

TECHNIQUE: Anterior Subapical Osteotomy

STEP 1: Incision

Before the incision is made, the surgeon should inject a local anesthetic with a vasoconstrictor. This reduces both stimulus to the patient and bleeding during surgery. The incision begins toward the lip and usually extends from canine to canine region,

leaving at least 15 mm of mucosa attached to the gingiva. When the mentalis muscle is reached, the muscle is sectioned and the incision is directed to the bone, leaving part of the mentalis muscle attached to the mandible. This permits suturing of the muscle to avoid lip ptosis.

STEP 2: Mucoperiosteal Dissection

Bone is exposed according to how far posteriorly the osteotomy will be extended. Only enough bone to complete the osteotomy is exposed, keeping as much soft tissue attached as possible. This minimizes the risk of avascular complications. In some cases it

might be necessary to expose and dissect the neurovascular bundle so that it is best protected. This can be accomplished by detaching the mucoperiosteum from around the mental foramen and making longitudinal incisions on the periosteum surrounding the nerve.

STEP 3: Osteotomy

It is essential to study the patient's tomograms carefully before performing the osteotomies. The horizontal osteotomy is made at least 5 mm below the teeth apices and should go deep enough to leave just a thin layer of bone in the lingual cortex. Care must be taken not to violate the lingual mucosa. A chisel is then used to finish the osteotomy. These distances can all be measured in the tomogram and then transferred to the surgery. If the vertical osteotomy is performed without tooth extraction, the orthodontist must separate the roots adjacent to the cut before surgery. Like the horizontal osteotomy, the vertical cuts should leave a thin layer of bone in the lingual cortex, and the final separation is

achieved with a thin chisel. If the mental foramen is close to the osteotomy cut, it may be necessary to reposition the neurovascular bundle (Figure 30-1, *A*).

If extractions are planned and the space is closed with posterior positioning of the anterior segment (Figures 30-1, *B-E*), special care must be taken not to remove excessive bone. After the anterior segment has been mobilized and placed to the occlusal splint, final bone interferences are removed. Spending some time removing interferences at this time is safer than trying to remove large amounts of bone initially. Absence of bone between teeth may result either in periodontal defect or in poor bone contact, which may jeopardize bone healing and affect stability.

Continued

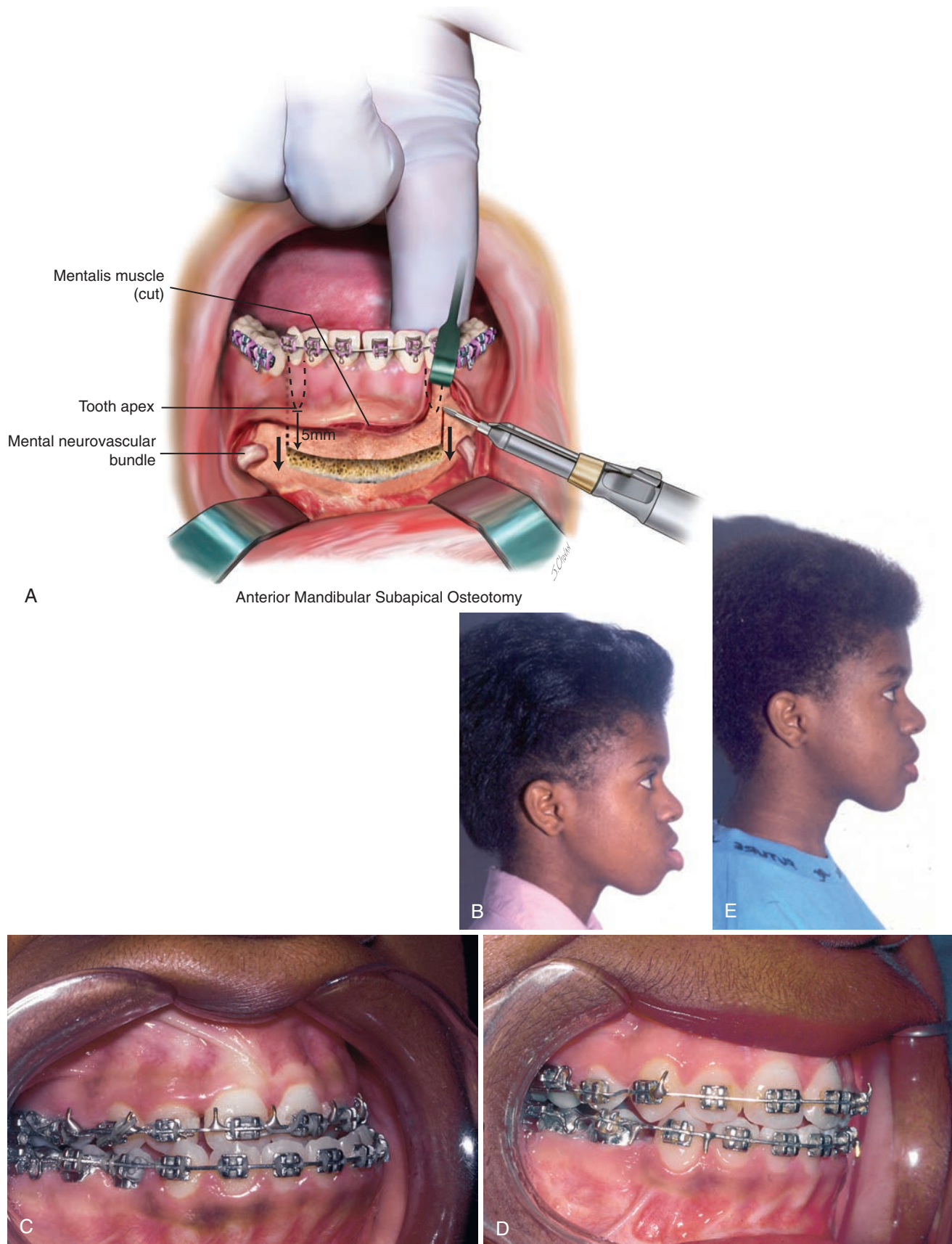
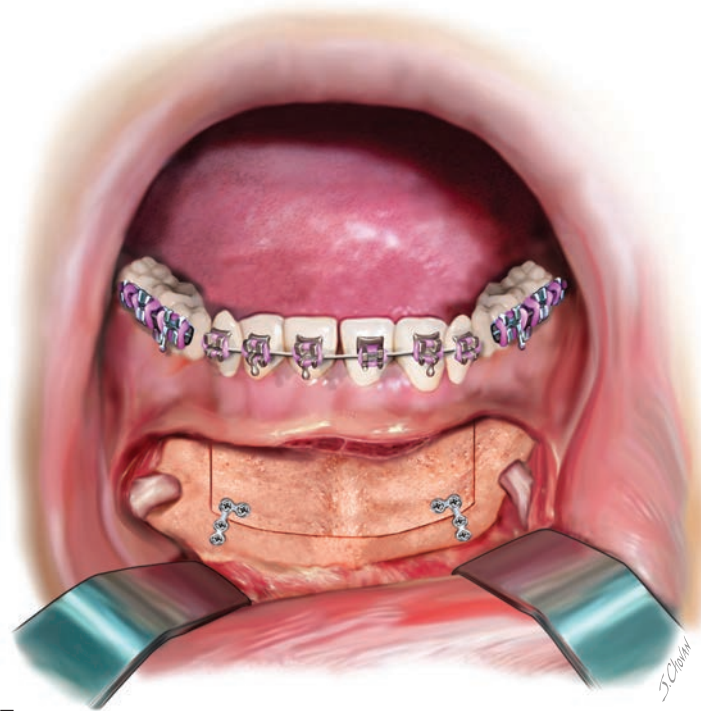


Figure 30-1 **A**, Interdental osteotomy positioning of a finger over the lingual mucosa. **B** to **E**, The patient underwent an anterior subapical osteotomy for posterior repositioning of the anterior segment of the mandible.



F Corrected Curve of Spee

Figure 30-1, cont'd F, Fixation of the osteotomy with two L-shaped plates.

TECHNIQUE: Anterior Subapical Osteotomy—cont'd

STEP 4: Fixation

Although it may be easy to accomplish the anterior subapical osteotomies, fixating the anterior segment to its new position can be quite challenging. This happens because it may be necessary to remove large amounts of interference, especially when the purpose of the surgery is to correct the curve of Spee. After all bone interference has been removed, a prefabricated occlusal splint is placed to recompose the inferior arch. Fixation is then

accomplished with two L-shaped titanium plates of the 1.6-mm system (Figure 30-1, F). In most cases it also is advisable to position a 26-gauge bridge wire around the teeth adjacent to the osteotomy in the cervical region. This controls the tension over the osteotomized segment and allows early removal of the acrylic splint. Removal of the acrylic splint makes the occlusion easier to control and facilitates oral hygiene.

STEP 5: Suture

Closure begins in the muscular layer with suturing of the mentalis muscles. This is very important to avoid labial ptosis. At least three sutures are placed in the muscular tissue. Suturing of the

mucosa must begin by reapproximating the midline, to avoid creating labial asymmetries. The remnant mucosa then is closed with continuous suture. A pressure dressing is applied to hold the lip and soft chin up and is kept in place for 5 to 7 days.

TECHNIQUE: Total Subapical Osteotomy

STEP 1: Incision

Before the incision is made, a local anesthetic with a vasoconstrictor should be injected. This reduces both stimulus to the patient and bleeding during surgery. The anterior part of the

incision is the same as described previously for the anterior subapical osteotomy. This incision is extended posteriorly to the middle of the ascending ramus bilaterally.

STEP 2: Mucoperiosteal Dissection

After the symphysis has been exposed, dissection continues posteriorly to expose the whole body of the mandible. The mental neurovascular bundle is detached from the periosteum with longitudinal incisions through the periosteum. The coronoid process

is almost fully exposed with the aid of a ramus Obwegeser retractor, and the medial periosteum is exposed to reveal the lingula; in this way, the mandibular foramen can be located. As much soft tissue as possible should be kept attached to the lateral part of the ramus.

STEP 3: Osteotomy

Before the osteotomy is performed, it is important to register a vertical reference from the pogonion to a landmark in the maxilla. The whole alveolar process with teeth will be mobilized; therefore, the surgeon must know the vertical position of the mandible so that the final facial height is the same as planned. Careful analysis of the tomogram also is important to measure the height of the inferior alveolar neurovascular bundle in the body of the mandible. In some cases there is a comfortable distance between the nerve and the basilar bone, and the horizontal osteotomy can be performed with minimum risk to the nerve. However, in most cases it is advisable to expose the bundle by removing the external cortex along the canal. This exposure can be safely performed with a #701 bur. One linear osteotomy is made superior and one inferior to the alveolar inferior canal, from the retromolar region to the mental foramen anteriorly. These lines should be parallel to each other and deep enough to cut the buccal cortex. After completion, the osteotomy lines are united with perpendicular osteotomies anteriorly and posteriorly, also through the buccal cortex. Additional perpendicular lines can be made to facilitate the removal of the buccal cortical bone with a chisel to expose the neurovascular bundle (Figure 30-2, A). All the bone removed from the lateral cortex must be kept in a physiologic solution in case grafting is necessary after the segment has been positioned.

When the exposure is complete, the bundle should be released from the canal only if it is in the path of or very close to the osteotomy. Horizontal osteotomies then can be performed either with a bur or a saw, beginning anteriorly in the symphysis and proceeding to the last molar. At least 1 cm of bone should remain in the inferior border to minimize the risk of fracture. While

performing the horizontal cut, the surgeon must place a finger in the floor of the mouth to feel the lingual cortical bone so that the bone can be cut without harming the lingual mucosa. Final osteotomy of the lingual cortex may be accomplished with a chisel (Figure 30-2, B).

Ramus osteotomy begins in the lingual cortex with a horizontal osteotomy, similar to the sagittal ramus osteotomy. After detachment of the coronoid process is complete, a Kocher forceps is used to keep soft tissue retracted. A periosteal elevator is placed subperiosteally to expose the lingula, and a reciprocating saw is used to cut the medial cortex of the ramus just superior and posterior to the lingula and parallel to the occlusal plane. It is important to position the saw at 45-degree angle to the medial surface of the ramus so that it will be easier to cut only the lingual cortex, preserving the buccal cortex. This sagittal cut runs until it meets the subapical cut.

A large chisel is used to lever the distal segment and complete the subapical osteotomy. Excessive force must be avoided so that the inferior border of the mandible remains sound. In the medial ramus, the split may be completed with the aid of a sagittal split Smith spreader. After the distal segment has been mobilized, additional mobilization may be necessary to complete the desired movement. Once the split is complete, a prefabricated acrylic splint is placed to guide the movement.

When this technique was first described by MacIntosh,¹¹ the posterior osteotomy was performed just posterior to the last molar, in a vertical direction. However, this vertical osteotomy carries greater risk to the inferior alveolar neurovascular bundle, either during the bone cut or after mobilization of the segment.

STEP 4: Fixation

After intermaxillary fixation has been performed, with or without a final splint in position, the vertical reference measured at the beginning of the procedure is checked to see whether it matches the preplanned position. Mandibular condyles must be seated in the glenoid fossa without extreme force. This can be accomplished with a tripod support, with the surgeon's thumb positioned over the patient's chin and the first and second fingers over the

mandibular angle bilaterally; the surgeon then pushes the mandible backward and upward until it reaches the preplanned vertical height (Figure 30-2, C).

In a total subapical osteotomy, it is advisable to use a 2-mm plate system because the whole mandible must be secured. One double T-shaped plate is placed in each side of the mandibular body, posterior to the mental foramen, and one L-shaped plate is placed on each side, between the mental foramina (Figure 30-2, D).

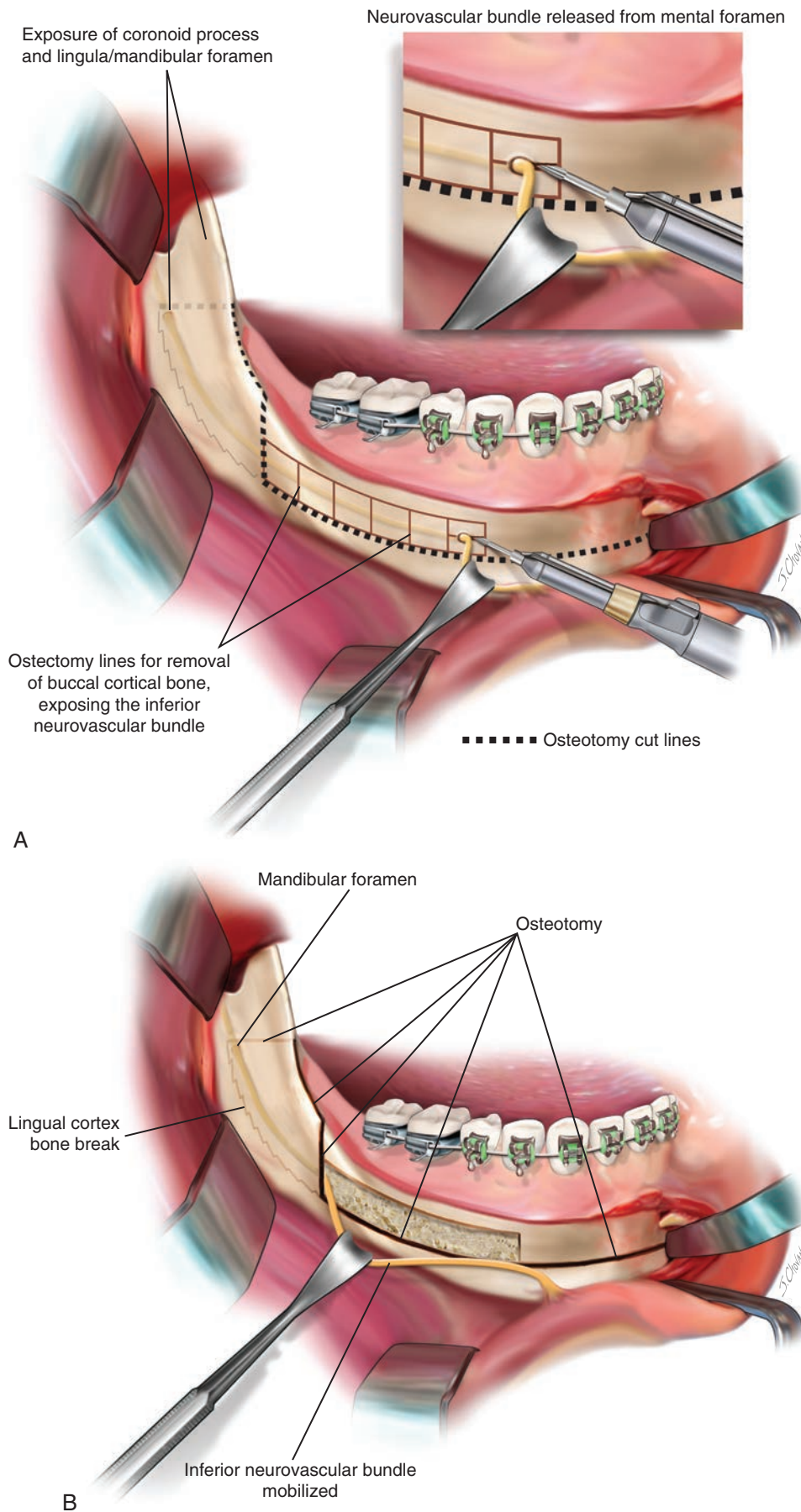
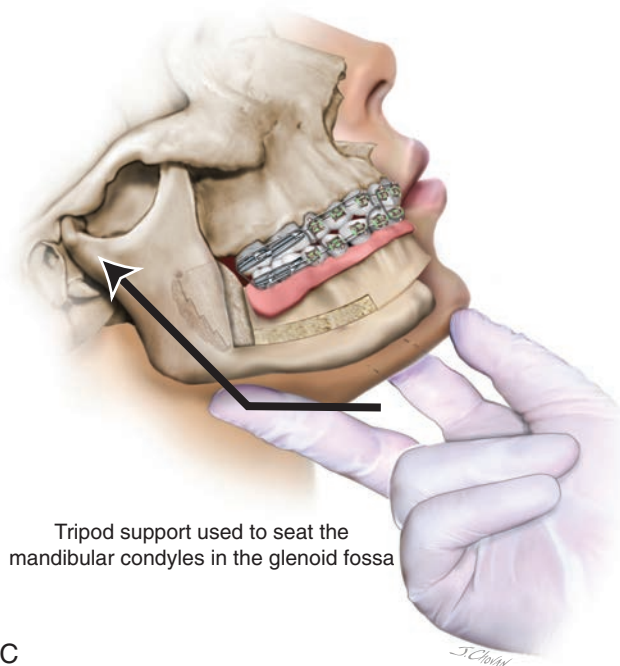
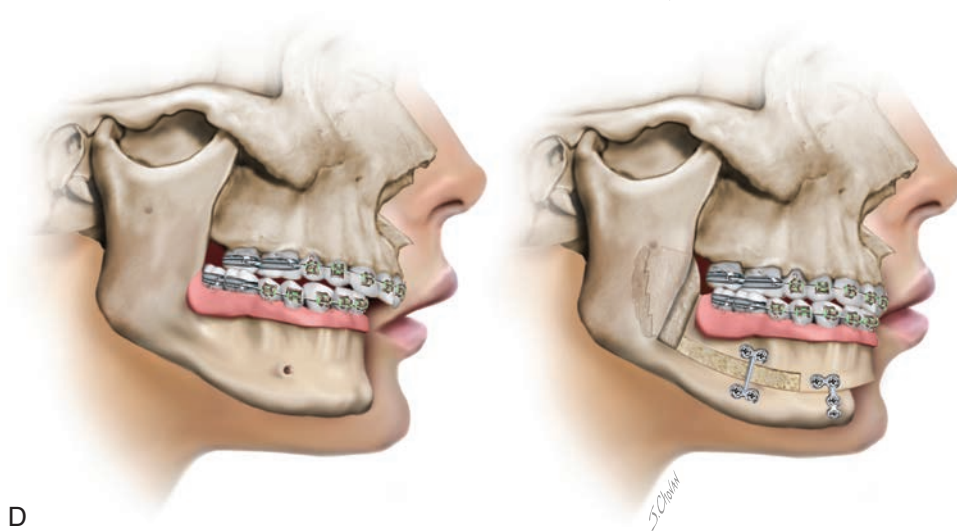


Figure 30-2 **A**, Removal of the labial cortex to visualize the nerve. **B**, Dissection of the nerve out of the canal.



Tripod support used to seat the mandibular condyles in the glenoid fossa

C



D

Figure 30-2, cont'd C, Positioning of the proximal segment, which involves gently pushing the condyles upward and backward. D, Fixation and profile changes.

TECHNIQUE: Total Subapical Osteotomy—cont'd

STEP 5: Suture

Closure begins in the muscular layer with suturing of the mentalis muscles. This is very important to avoid labial ptosis. At least three sutures are placed in the muscular tissue. Suturing of the mucosa must begin with reapproximation of the midline, to avoid creating labial asymmetries. The remnant mucosa is then closed

with continuous suture. If a graft is used, a two-plane suture should be performed, beginning in the muscular layer and finishing with a continuous suture of the mucosa. A pressure dressing is applied in the anterior region to hold the lip and soft chin up and is kept in place for 5 to 7 days.

TECHNIQUE: Posterior Subapical Osteotomy**STEP 1: Incision**

Before the incision is made, a local anesthetic with vasoconstrictor should be injected. This reduces both stimulus to the patient and bleeding during surgery. The incision begins in the mucosa

below the gingiva, leaving at least 10 mm of soft tissue attached to the segment to be mobilized. The incision should be extended anteriorly enough to expose the mental neurovascular bundle, and posteriorly enough to expose the nerve posterior to the last molar.

STEP 2: Mucoperiosteal Dissection

Care must be taken to avoid unnecessary soft tissue detachment from the mobilized segment. This minimizes the risk of avascular

complications. The mental foramen and the inferior border of the mandible are exposed.

STEP 3: Osteotomy

It is essential to study the patient's tomograms carefully before performing the osteotomies. The horizontal osteotomy is made about 5 mm below the teeth apices and should go deep enough to leave just a thin layer of bone in the lingual cortex, to avoid violating the lingual mucosa. A chisel is then used to finish the osteotomy. These distances can all be measured in the tomogram and then transferred to the surgery. If the vertical osteotomy is performed without extraction of teeth, the orthodontist must separate the roots adjacent to the cut before surgery. Like the horizontal cut, the vertical osteotomy should leave a thin layer of bone in the lingual cortex. The final separation is achieved with a thin chisel.

The position of the inferior alveolar neurovascular bundle, determined previously by computed tomography (CT) scan, determines whether the horizontal osteotomy is performed superior or inferior to the canal. In a few cases, enough space is available below the apices to perform the horizontal osteotomy above the canal without risk to the nerve. In most cases, however, it is advisable to expose the neurovascular bundle by removing the lateral cortex. This removal is initiated with a bur, to cut the lateral cortex, and it should be completed with chisels. The cut usually is extended a few millimeters posterior to the last molar to

facilitate the procedure. All the bone removed from the lateral cortex must be kept in a physiologic solution in case grafting is necessary after positioning of the segment.

After this window has been opened and the bundle dissected out the mandible, the horizontal osteotomy can be performed safely. While making the horizontal cut, the surgeon must place a finger in the floor of the mouth to feel the lingual cortical bone, to ensure that it is cut without harming the lingual mucosa. The final osteotomy of the lingual cortex may be accomplished with a chisel.

An anterior vertical cut is made between the roots of adjacent teeth either with a #701 bur in a handpiece or with a sagittal saw. Adjacent teeth must have been previously separated by orthodontic mechanics. A posterior vertical osteotomy is performed at least 5 mm posterior to the last molar. This keeps a large amount of soft tissue attached to the mobilized segment and prevents periodontal defects around the last molar.

The final split may be accomplished by levering the segment with a chisel; care must be taken not to break the inferior border by using excessive force. An additional osteotomy is performed in the fixed portion to accommodate the necessary movement of the mobilized segment (Figure 30-3).

STEP 4: Fixation

Making the posterior subapical osteotomy cut may be difficult, and fixating the mobilized segment in its new position may be even more difficult. This is because interference must be removed to accommodate the segment in its new position, because the main

purpose of this procedure is to intrude the posterior segment. After all bone interference has been removed, a prefabricated occlusal splint is placed to recompose the inferior arch. The fixation is then accomplished with one X-shaped plate of the 2-mm system.

STEP 5: Suture

Suturing may be performed in either one or two planes. If a graft is used, it is preferable to perform two-plane suturing, beginning

in the muscular layer and finishing with a continuous suturing of the mucosa.

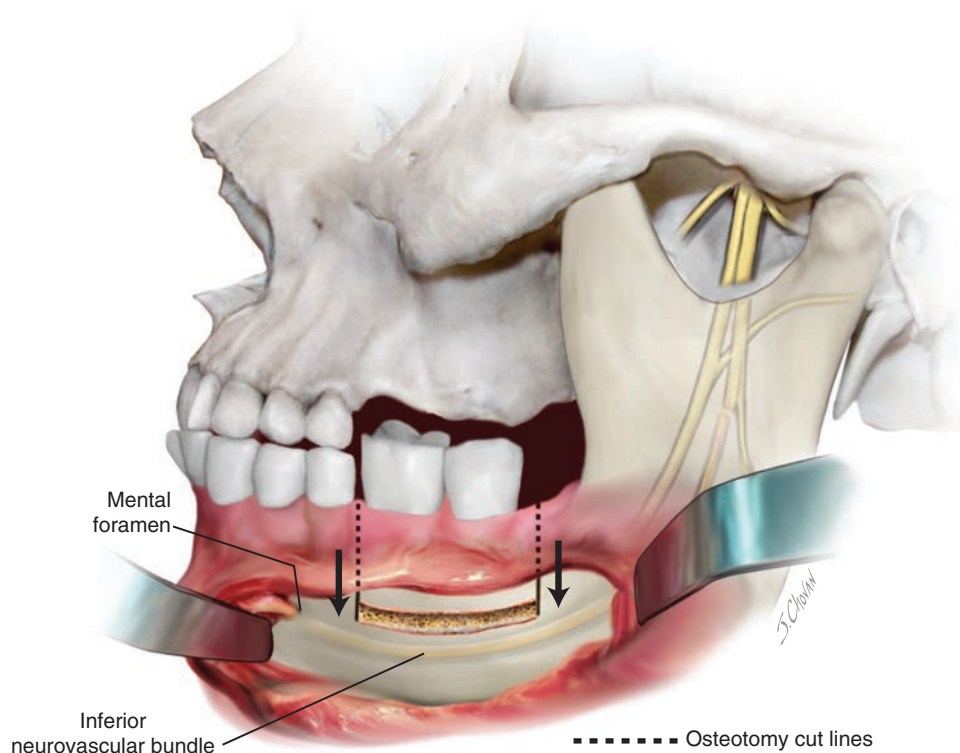


Figure 30-3 Posterior subapical osteotomy to intrude the segment.

ALTERNATIVE TECHNIQUE: Combined Sagittal Split Osteotomy and Reduction Genioplasty

Total mandibular subapical osteotomy has a very specific indication, which is to position the alveolar segment anteriorly while keeping the pogonion in the same position. However, this is a very sensitive technique that poses considerable risk to the inferior alveolar neurovascular bundle. Therefore, in some cases, especially when the inferior alveolar nerve is positioned close to the mandibular inferior border, it is best to perform a sagittal split osteotomy of the mandible for advancement, combined with a genioplasty to set the chin

back. This approach maintains the pogonion in its original position. Some may argue that a setback genioplasty produces an excess of tissue in the submental region, which may be unesthetic. This is not always true, as shown in Figure 30-4, because the pogonion is not retruded in these cases, but rather kept in the presurgical position. If the procedure results in an unesthetic excess of tissue in the submental region, liposuction can be performed to resolve this issue.

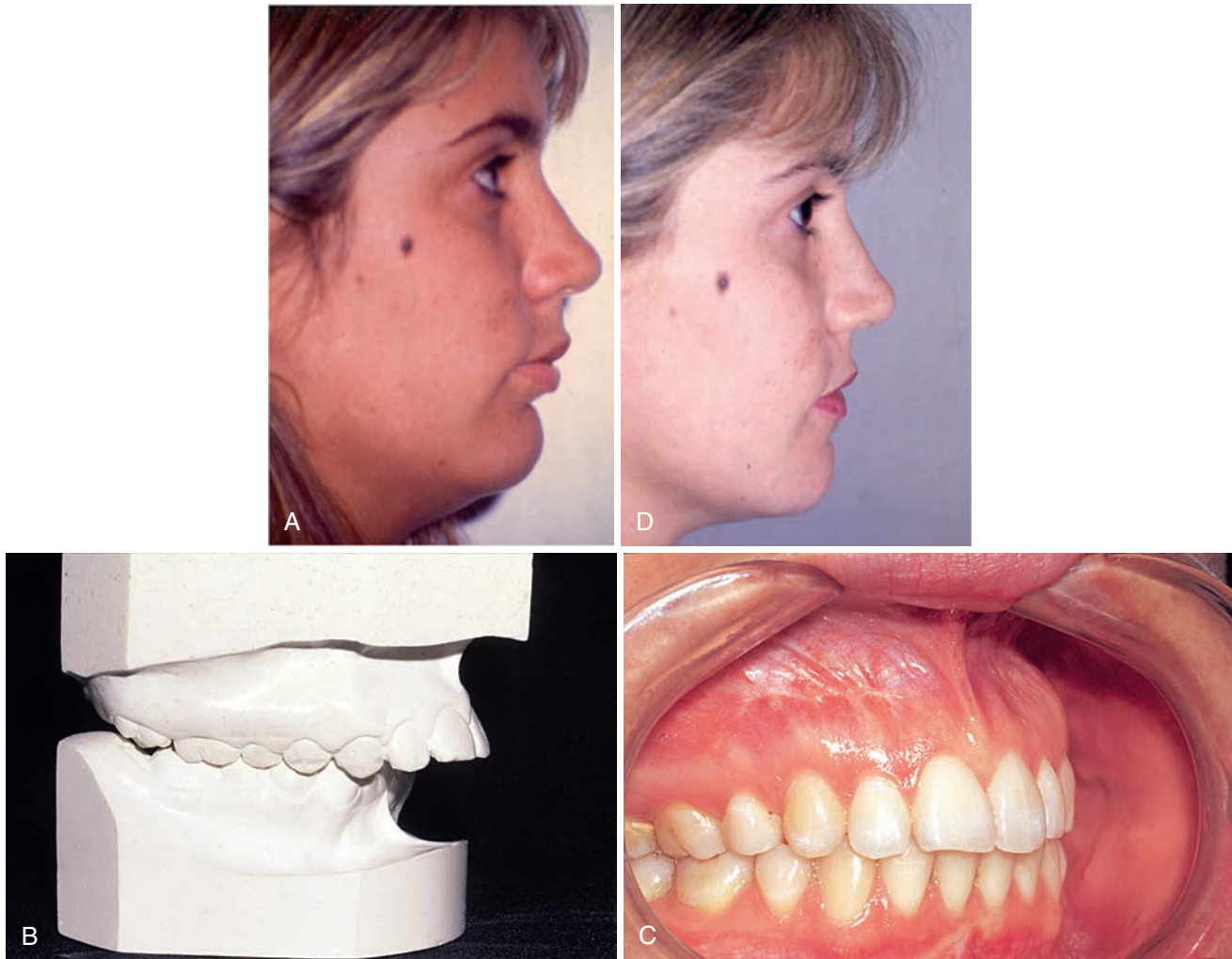

Figure 30-4 A to D, A Class II patient underwent a bilateral sagittal split-ramus osteotomy to advance the mandible, in addition to genioplasty to retrude the chin.

Avoidance and Management of Intraoperative Complications

Several intraoperative complications can arise with mandibular subapical osteotomies.

- **Tooth damage.** There must be adequate space between roots to perform the interdental osteotomy safely. The orthodontist must separate the teeth by 2 to 3 mm, and only a fine chisel should be used in the crestal bone. Also, at least 5 mm of sound bone should be left between teeth apices and the inferior horizontal osteotomy.
- **Nerve damage.** Dissection of the mental nerve from the periosteum facilitates visualization and permits moving of the nerve anteriorly or posteriorly to protect it from the bur during the osteotomy. It is of outmost importance to study the CT scan and measure the distance to the inferior alveolar neurovascular bundle along the path of the osteotomy. It also is important to observe the proximity of the

neurovascular bundle to the buccal or lingual cortical bone during its intraosseous path.

- **Fracture of the inferior border of the mandible.** Although rare, this fracture may occur when the teeth apices are close to the inferior border. Reconstruction plates are best applied to fixate the fractured segments and recompose the inferior border continuity. After repair, surgery continues in the usual sequence.

Postoperative Considerations

Early removal of the occlusal splint should always be the goal. This facilitates oral hygiene and allows more reliable occlusal control by the surgeon. With anterior subapical osteotomies, this can be safely accomplished by using the bridle wire in the tension zone and also by early placement of a continuous orthodontic wire.

References

1. Kostecka F: Surgical correction of protrusion of the lower and upper jaws, *J Am Dent Assoc* 12:362, 1928.
2. Wassmund M: *Frakturen und Luxationen des Gesichtsschädels*, Leipzig, 1927, Hermann Meusser.
3. Bell WH, Dann JJ: Correction of dentofacial deformities by surgery in the anterior part of the jaws, *Am J Orthod* 64:162, 1973.
4. Kent JN, Hinds EC: Management of dental facial deformities by anterior alveolar surgery, *J Oral Surg* 29:13, 1971.
5. Bell WH, Levy BM: Revascularization and bone healing after anterior mandibular osteotomy, *J Oral Surg* 28:196, 1970.
6. Castelli WA, Nasjleti CE, Diaz-Perez R: Interruption of the anterior inferior alveolar flow and its effects on mandibular collateral circulation and dental tissues, *J Dent Res* 54:708, 1975.
7. Hellem S, Ostrup LT: Normal and retrograde blood supply to the body of the mandible in the dog. II, *Int J Oral Surg* 10:31, 1981.
8. Epker BN: Vascular considerations in orthognathic surgery. I. Mandibular osteotomies, *Oral Surg Oral Med Oral Pathol* 57:467, 1984.
9. Hofer O: Operation der prognathie und mikrognathie, *Deutsche Zahn Mund Kieferh* 9:121, 1942.
10. Köle H: Surgical operations on the alveolar ridge to correct occlusal deformities, *Oral Surg Oral Med Oral Pathol* 12:277, 1959.
11. MacIntosh RB: Total mandibular alveolar osteotomy, *J Maxillofac Surg* 4:210, 1974.
12. Epker BN, Wolford LM: Mandibular osteotomies. In Epker BN, Wolford LM, editors: *Dentofacial deformities: surgical-orthodontic correction*, St Louis, 1980, Mosby.
13. Bell WH, Legan HL: Treatment of Class II deep bite by orthodontic and surgical means. *Am J Orthod* 85:1, 1984.
14. Wolford LM, Moenning JE: Diagnosis and treatment planning for mandibular subapical osteotomies with new surgical modifications, *Oral Surg Oral Med Oral Pathol* 68:541, 1989.