

CME MONOGRAPH

Visit <https://tinyurl.com/XXX> for online testing
and instant CME certificate.

EARN CREDITS
CME



CURRENT PERSPECTIVES
Dry Eye Disease Management
FOR IMPROVING PATIENT OUTCOMES

FACULTY

TERRY KIM, MD (CHAIR) • ROSA BRAGA-MELE, MD, MEd, FRCSC
JESSICA CIRALSKY, MD • CHRISTOPHER J. RAPUANO, MD



Original Release: May 1, 2019 • **Expiration:** May 31, 2020

This continuing medical education activity is jointly provided by **New York Eye and Ear Infirmary of Mount Sinai** and MedEdicus LLC.



MedEdicus
LLC

This continuing medical education activity is supported through an unrestricted educational grant from Shire.

Distributed with **EyeNet**

LEARNING METHOD AND MEDIUM

This educational activity consists of a supplement and ten (10) study questions. The participant should, in order, read the learning objectives contained at the beginning of this supplement, read the supplement, answer all questions in the post test, and complete the Activity Evaluation/Credit Request form. To receive credit for this activity, please follow the instructions provided on the post test and Activity Evaluation/Credit Request form. This educational activity should take a maximum of 1.5 hours to complete.

ACTIVITY DESCRIPTION

Dry eye disease (DED) is increasing in prevalence because of an aging population and necessities of modern living (eg, office work and staring at computer screens and other digital devices). Nonetheless, DED remains underdiagnosed and undertreated. It is important to diagnose and treat DED because it can affect daily function, quality of life, and outcomes of cataract and refractive surgery. The desired results of this activity are for ophthalmologists to have a better understanding of the epidemiology and consequences of DED and to use appropriate screening, diagnostic testing, and management approaches.

TARGET AUDIENCE

This educational activity is intended for ophthalmologists.

LEARNING OBJECTIVES

Upon completion of this activity, participants will be better able to:

- Review the prevalence, economic burden, and quality of life burden of DED
- Apply appropriate diagnostic testing for evaluating DED
- Articulate the implications of inflammation in DED on treatment
- Apply evidence of DED treatments for individualizing management of DED in a variety of patient profiles

ACCREDITATION STATEMENT

This activity has been planned and implemented in accordance with the accreditation requirements and policies of the Accreditation Council for Continuing Medical Education (ACCME) through the joint providership of **New York Eye and Ear Infirmary of Mount Sinai** and MedEdicus LLC. The **New York Eye and Ear Infirmary of Mount Sinai** is accredited by the ACCME to provide continuing medical education for physicians.



In July 2013, the Accreditation Council for Continuing Medical Education (ACCME) awarded New York Eye and Ear Infirmary of Mount Sinai "Accreditation with Commendation," for six years as a provider of continuing medical education for physicians, the highest accreditation status awarded by the ACCME.

AMA CREDIT DESIGNATION STATEMENT

The **New York Eye and Ear Infirmary of Mount Sinai** designates this enduring material for a maximum of 1.5 AMA PRA Category 1 Credits™. Physicians should claim only the credit commensurate with the extent of their participation in the activity.

GRANTOR STATEMENT

This continuing medical education activity is supported through an unrestricted educational grant from Shire.

DISCLOSURE POLICY STATEMENT

It is the policy of **New York Eye and Ear Infirmary of Mount Sinai** that the faculty and anyone in a position to control activity content disclose any real or apparent conflicts of interest relating to the topics of this educational activity, and also disclose discussions of unlabeled/unapproved uses of drugs or devices during their presentation(s). **New York Eye and Ear Infirmary of Mount Sinai** has established policies in place that will identify and resolve all conflicts of interest prior to this educational activity. Full disclosure of faculty/planners and their commercial relationships, if any, follows.

DISCLOSURES

Rosa Braga-Mele, MD, MEd, FRCSC, had a financial agreement or affiliation during the past year with the following commercial interests in the form of *Consultant/Advisory Board*: Alcon; and Johnson & Johnson Vision Care, Inc.

Jessica Ciralsky, MD, had a financial agreement or affiliation during the past year with the following commercial interests in the form of *Consultant/Advisory Board*: Allergan; and Shire.

Terry Kim, MD, had a financial agreement or affiliation during the past year with the following commercial interests in the form of *Consultant/Advisory Board*: Actavis; Aerie Pharmaceuticals, Inc; Alcon; Allergan; Avedro, Inc; Avellino Labs; Bausch & Lomb Incorporated; BlephEx; CoDa Therapeutics, Inc; CorneaGen; Kala Pharmaceuticals; NovaBay Pharmaceuticals, Inc; Novartis Pharmaceuticals Corporation; Ocular Therapeutix, Inc; Oculunex Therapeutics, Inc; Omeros Corporation; PowerVision, Inc; Presbyopia Therapies; Shire; Silk Technologies Ltd; Simple Contacts Inc; TearLab Corporation; TearScience; and Valeant; *Ownership Interest (Stock options, or other holdings, excluding diversified mutual funds)*: CorneaGen; Kala Pharmaceuticals; NovaBay Pharmaceuticals, Inc; Ocular Therapeutix, Inc; Omeros Corporation; Simple Contacts Inc; and TearScience.

Christopher J. Rapuano, MD, had a financial agreement or affiliation during the past year with the following commercial interests in the form of *Consultant/Advisory Board*: Allergan; Avedro, Inc; Bio-Tissue; GlaxoSmithKline; Kala Pharmaceuticals; Novartis Pharmaceuticals Corporation; Shire; Sun Ophthalmics; and TearLab Corporation; *Honoraria from promotional, advertising or non-CME services received directly from commercial interests or their Agents (eg, Speakers Bureaus)*: Avedro, Inc; Bio-Tissue; and Shire.

NEW YORK EYE AND EAR INFIRMARY OF MOUNT SINAI PEER REVIEW DISCLOSURE

Angie E. Wen, MD, has no relevant commercial relationships to disclose.

EDITORIAL SUPPORT DISCLOSURES

Cheryl Guttman Krader; Melissa Carter-Ozhan; Cynthia Tornallyay, RD, MBA, CHCP; Kimberly Corbin, CHCP; Barbara Aubel; and Michelle Ong have no relevant commercial relationships to disclose.

DISCLOSURE ATTESTATION

The contributing physicians listed above have attested to the following:

- 1) that the relationships/affiliations noted will not bias or otherwise influence their involvement in this activity;
- 2) that practice recommendations given relevant to the companies with whom they have relationships/affiliations will be supported by the best available evidence or, absent evidence, will be consistent with generally accepted medical practice; and
- 3) that all reasonable clinical alternatives will be discussed when making practice recommendations.

OFF-LABEL DISCUSSION

This CME activity includes discussion of unlabeled and/or investigative uses of drugs. Please refer to the official prescribing information for each drug discussed in this activity for FDA-approved dosing, indications, and warnings.

NEW YORK EYE AND EAR INFIRMARY OF MOUNT SINAI PRIVACY & CONFIDENTIALITY POLICIES

<http://www.nyee.edu/health-professionals/cme/enduring-activities>

CME PROVIDER CONTACT INFORMATION

For questions about this activity, call 212-870-8127.

TO OBTAIN AMA PRA CATEGORY 1 CREDIT™

To obtain AMA PRA Category 1 Credit™ for this activity, read the material in its entirety and consult referenced sources as necessary. Please take this post test and evaluation online by going to <https://tinyurl.com/xxxxxxx>. Upon passing, you will receive your certificate immediately. You must score 70% or higher to receive credit for this activity, and may take the test up to 2 times. Upon registering and successfully completing the post test, your certificate will be made available online and you can print it or file it.

DISCLAIMER

The views and opinions expressed in this educational activity are those of the faculty and do not necessarily represent the views of **New York Eye and Ear Infirmary of Mount Sinai**, MedEdicus LLC, Shire, EyeNet, or the American Academy of Ophthalmology.



FACULTY

TERRY KIM, MD (CHAIR)

Professor of Ophthalmology
Duke University School of Medicine
Chief, Cornea and External Disease Division
Director, Refractive Surgery Service
Duke University Eye Center
Durham, North Carolina

ROSA BRAGA-MELE, MD, MEd, FRCSC

Professor of Ophthalmology
University of Toronto
Director of Cataract Surgery
Kensington Eye Institute
Toronto, Canada

JESSICA CIRALSKY, MD

Associate Professor of Ophthalmology
Weill Cornell Medicine
New York, New York

CHRISTOPHER J. RAPUANO, MD

Professor of Ophthalmology
Sidney Kimmel Medical College
Thomas Jefferson University
Chief, Cornea Service
Wills Eye Hospital
Philadelphia, Pennsylvania

CME REVIEWER FOR NEW YORK EYE AND EAR INFIRMARY OF MOUNT SINAI

ANGIE E. WEN, MD

Assistant Professor of Ophthalmology
New York Eye and Ear Infirmary
of Mount Sinai
New York, New York



CURRENT PERSPECTIVES

Dry Eye Disease Management FOR IMPROVING PATIENT OUTCOMES

EPIDEMIOLOGY AND CHALLENGES OF DRY EYE DISEASE

TERRY KIM, MD

Dry eye disease (DED) is a common condition that often brings patients to the ophthalmologist's office because it can result in significant discomfort and affect visual function. The estimated prevalence of DED reported in a number of studies varies from 3.4% to 48.0%; this wide range can be explained by differences in study populations and the criteria used to define DED (Table 1).¹⁻⁴

Table 1. Estimates of Dry Eye Prevalence

Study	Population Age, years	Prevalence, %
Salisbury Eye Study ¹	≥ 65	14.6
Beaver Dam ¹	≥ 48	14.4
Women's Health Study ¹	≥ 49	7.8
Blue Mountains ¹	≥ 50	16.6
Sumatra (Asian) ¹	≥ 21	27.5
Allergan phone survey ²	≥ 18	48.0
National Health and Wellness Survey ³	18-49	3.4
	≥ 50	11.3
Moon et al ⁴	Children in grades 1-3	4.0
	Children in grades 4-6	9.1

Historically, DED was often regarded as a condition that predominantly affected postmenopausal women. Its prevalence does increase with age and is higher in women than in men⁵⁻⁷; however, DED is also common among men,⁷ and it is increasingly being recognized among younger adults as well as children, a phenomenon that has been attributed to the use of smartphones and screen time with other digital devices.^{3,4}

Dry eye disease is important to diagnose and treat because it can interfere with daily activities—such as the ability to work at a computer, read, and drive at night—and impairs quality of life.⁸⁻¹⁰ The annual economic burden of DED is approximately \$60 billion, factoring in direct health care costs and indirect costs of lost work productivity.^{8,11} Patients might self-treat with over-the-counter artificial tears, but they might also want and need more than palliative therapy.

Research conducted over the past 10 to 15 years has increased knowledge about the pathogenesis of DED, leading to an evolution in its definition and the development of novel diagnostic and treatment modalities that are being incorporated into new algorithms for evaluation and management.¹²⁻¹⁴ A current definition by the Tear Film & Ocular Surface Society Dry Eye WorkShop II describes DED as a multifactorial

disease, in which tear film instability and hyperosmolarity, ocular surface inflammation and damage, and neurosensory abnormalities play etiologic roles.¹⁵ Because inflammation drives a perpetuating vicious cycle leading to progressive ocular surface damage, inflammation control is paramount for effective management of DED.

Of importance to the detection and management of DED are accumulating data that highlight the possibility of discordance between the severity of signs and symptoms in patients with DED and the fact that aqueous-deficient and evaporative dry eye disease exist on a continuum.¹⁵⁻¹⁸ There is an evaporative component in most cases of DED, which is mostly due to meibomian gland dysfunction (MGD).¹⁸

Cases presented in this review highlight the role of iatrogenic causes of DED—including systemic medications, ocular surgery, and contact lens wear—and the importance of identifying and managing DED in patients who are undergoing cataract or laser vision correction surgery. Although technological advances have improved vision outcomes after these procedures, the benefits of these developments can be negated by even minimal disruption of the tear film. Irregularities in the tear film, which is the first refractive interface of the eye, can cause light scatter, degrade image quality, increase higher-order aberrations, and induce distortion that is magnified by a multifocal intraocular lens (IOL).¹⁹⁻²¹ In fact, studies identify dry eye as one of the most common causes among patients who were dissatisfied with their visual outcome after LASIK (laser in situ keratomileusis) or multifocal IOL surgery.^{22,23}

Ocular surface irregularity from DED also affects the accuracy of keratometry, topography, and aberrometry measurements that are used for planning cataract and refractive surgery.^{21,24} Consequently, untreated dry eye might lead to unnecessary exclusion of patients from receiving a multifocal IOL, improper IOL selection in terms of asphericity or power, planning for astigmatic correction when it is not needed, incorrect alignment of a toric IOL, and performing a lens exchange or refractive enhancement as a secondary procedure. In addition, increased bacterial load in patients with lid margin disease is a risk factor for postoperative endophthalmitis.²⁵ The following case discussions provide insights on approaches for evaluating and managing DED in scenarios that might be encountered in clinical practice.

CASE 1: DRY EYE AND CATARACT SURGERY

FROM THE FILES OF ROSA BRAGA-MELE, MD, MED, FRCSC

A 59-year-old man presented complaining of fluctuating vision and eyestrain throughout the day, along with glare around lights when driving at night. He was an attorney and wanted to be able to see without glasses, especially for near vision.

The patient had mild hypertension that was controlled with medications. He was recently diagnosed with type 2 diabetes mellitus, had environmental allergies, and was a smoker. He was previously diagnosed with cataracts that have been worsening over the past 1 to 2 years.

Findings on examination were best-corrected visual acuity (BCVA) 20/30 OD and 20/40 OS, and manifest refraction $-0.25 +1.00 \times 90$ OD and $-0.50 +1.00 \times 90$ OS, with $+2.00$ add OU for reading. It was not possible to obtain a stable reading with autorefractor. Keratometry values measured with a manual keratometer, optical biometer, and Placido disc topographer differed. The topographer identified irregular astigmatism, and the rings image showed irregular mires and areas of dropout (Figure 1). Further examination showed the patient had mild blepharitis and meibomianitis, irregular cornea staining with fluorescein, and a tear breakup time (TBUT) < 5 seconds. No other abnormalities were identified on the ocular examination.

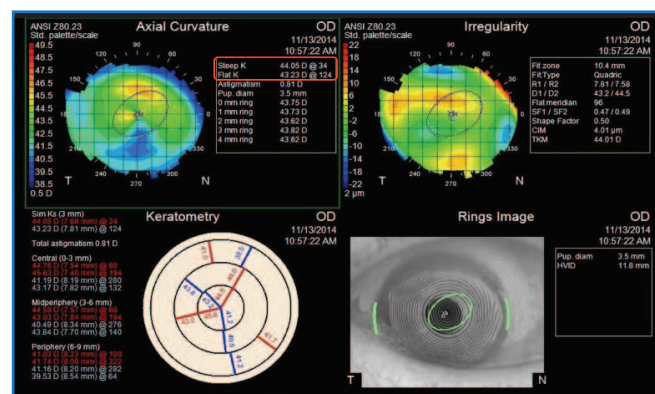


Figure 1. Topography image shows irregular astigmatism, with oval Placido disc indicative of dry eye

Discussion

Dr Braga-Mele: Dry eye disease was my suspected diagnosis according to the clinical findings, and an irregular and unstable tear film could be contributing to the patient's problems with fluctuating vision and glare. Refractive cataract surgery, however, has led me to look carefully at the cornea for other types of ocular surface disease (OSD) and at the retina to identify pathologies that might need to be addressed preoperatively or that would exclude a patient from receiving a multifocal IOL.

All patients requiring cataract surgery should be evaluated for DED, regardless of whether they have typical symptoms of DED. When patients with a cataract have DED, they might complain about fluctuating vision rather than dryness or foreign body sensation. Furthermore, a high percentage of patients with objective evidence of DED are asymptomatic.^{26,27}

Dr Kim: In the PHACO (Prospective Health Assessment of Cataract Patients' Ocular Surface) study, 77% of 272 eyes had abnormal corneal fluorescein staining, but approximately 60% of 136 patients had never complained of a foreign body sensation.²⁶ Another recent study found that among 46 patients presenting for cataract surgery who had minimal to no symptoms of DED, 85% had an abnormal tear osmolarity test result or a positive matrix metalloproteinase-9 (MMP-9) assay.²⁷

Lack of agreement in preoperative keratometry measurements should raise suspicion for DED. How common is that finding in your cataract surgery population?



Dr Ciralsky: I estimate that I find lack of agreement in keratometry values in approximately 15% to 20% of patients if I consider only the group that presents without an existing diagnosis of DED.

Dr Braga-Mele: I also see lack of agreement in keratometry values in probably 15% to 20% of patients. Irregular topographic astigmatism, the presence of hot spots or flat spots on topography, an irregularly shaped or smudgy Placido disc image, or a > 1-D interocular difference in the average K values should also raise suspicion of OSD. A careful slit-lamp examination and evaluation of anterior topography are essential to distinguish true from “faux” astigmatism. Other signs of DED include ocular surface staining with vital dyes, tear osmolarity > 308 mOsm/L or > 8 to 10 mOsm/L interocular difference, abnormal lipid layer thickness and/or instability, and a positive MMP-9 assay.^{28,29}

Case Continued

The patient was diagnosed with DED associated with mild blepharitis and meibomianitis. Diabetes, antihypertensive medication, smoking, and work-related eye strain were considered contributing factors.

Dr Braga-Mele: Optimizing the ocular surface preoperatively in patients requiring cataract surgery is critical for obtaining accurate keratometry results and a stable tear film that is needed for good vision. In addition, cataract surgery can worsen dry eye, and the risk can be greater after a femtosecond laser-assisted procedure than after conventional cataract surgery.³⁰

Management of DED requires a multimodal approach that includes consideration of exogenous factors—including diet and environment—and the effects of medications and systemic diseases. Therefore, it might be necessary to work with the patient’s internist or other treating physicians to address those issues.

Treatments for DED include over-the-counter artificial tears, preferably preservative-free products because benzalkonium chloride can worsen dry eye.¹² I start a topical agent to control inflammation, either cyclosporine or lifitegrast. In a study of 14 patients undergoing bilateral cataract surgery with implantation of a multifocal IOL, eyes treated with cyclosporine, 0.05%, for 1 month before surgery and 2 months postoperatively had significantly better outcomes for distance uncorrected visual acuity (UCVA), corneal and conjunctival staining, contrast sensitivity, and TBUT than fellow eyes treated with artificial tears twice daily.³¹ In addition, a significantly higher percentage of patients preferred the cyclosporine-treated eye than the control eye (57.1% vs 14.3%; $P = .007$). I tend to prescribe topical lifitegrast, however, because it has been associated with significant improvements in DED signs and symptoms after 2 weeks.^{32–34} I also use a short course of a topical corticosteroid in conjunction with topical lifitegrast or cyclosporine to control burning and stinging that can occur early with those medications. A topical corticosteroid also accelerates optimization of the ocular surface.^{35,36}

I prescribe erythromycin, 0.5%, ointment and recommend in-office meibomian gland expression for patients with

blepharitis/meibomianitis. For patients with rosacea, I prescribe doxycycline 100 mg at bedtime for 6 weeks and refer them to a dermatologist.

Dr Ciralsky, how do you treat MGD?

Dr Ciralsky: My approach depends on the severity of the disease, but I start by recommending warm compresses and baby shampoo scrubs. I often perform manual lid expression as well. I often prescribe low dose doxycycline for more moderate disease, typically at a dosage of 50 mg daily. I see the patients back again after 1 month, but in my experience, it might take as long as 3 months to see sufficient improvement. I also like to prescribe topical azithromycin for mild-to-moderate disease, but it has been difficult to obtain recently because of national shortages. I am using topical erythromycin or polymyxin B/bacitracin ointment at bedtime as alternatives. In more severe cases, I consider using thermal pulsation therapy.

Dr Rapuano: I prefer the commercial lid scrubs for cleansing because I think they work better than baby shampoo. I also start with warm compresses and azithromycin gel drops if it is available, or else erythromycin ointment. If there is not sufficient improvement, and especially if I see lid telangiectasia, I add oral doxycycline and start with 100 mg daily for 2 days and then decrease the dose to 50 mg daily for 2 to 4 weeks. I also use in-office thermal pulsation therapy, although it does not work well in some patients.

Dr Kim: I want to emphasize that MGD is very common. In a study of 224 patients with DED, 86% had signs of MGD.¹⁸ I think, however, that MGD is often overlooked. Evaluation of the lid margins and the quality and quantity of meibum should be part of the ophthalmic examination for DED. The assessment can be done quickly at the slit lamp by using a cotton-tipped applicator to push on the lower lids or with meibography, which has been a game changer for me both for identifying gland dilation and frank dropout and for educating patients about their disease (**Figure 2**). I find that once patients understand their condition, they are more likely to comply with therapy.

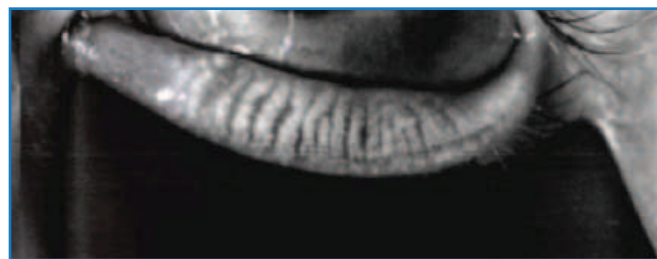


Figure 2. [Design: Please leave short space for caption TK.]
XXXXXXXXXXXXXXXXXXXXXXXXXXXX

Image courtesy of Jessica Ciralsky, MD

I also have had varying success with thermal pulsation therapy for MGD, but I am finding better results combining it with mechanical debridement of the lid margin, or microblepharoexfoliation. I have noticed that the eyes of patients with MGD might not look inflamed, but they can test positive with the MMP-9 assay, which is a marker of

inflammation. Therefore, I prescribe anti-inflammatory treatment. I also prefer lifitegrast over cyclosporine to optimize the ocular surface prior to cataract surgery because of evidence from clinical trials showing lifitegrast improved symptoms in some patients as soon as 2 weeks.^{33,34}

Dr Braga-Mele: How long do you treat patients with DED before reassessing their suitability for surgery?

Dr Ciralsky: I typically repeat the testing at monthly intervals until I can get a quality topography image and agreement in K readings.

Dr Rapuano: I reevaluate patients at 4- to 6-week intervals, depending on the severity of DED.

Dr Braga-Mele: I usually have patients return every 4 weeks until the topography is good.

Case Conclusion

The patient started treatment for DED with preservative-free artificial tears every 4 hours and loteprednol etabonate gel, 0.5%, twice daily. When he returned for evaluation after 6 weeks, topography no longer showed astigmatism.

The patient underwent cataract surgery with a monofocal aspheric IOL and achieved 20/20 UCVA. He was instructed to continue treatment for DED after cataract surgery.

CASE 2: DRY EYE AND REFRACTIVE SURGERY

FROM THE FILES OF JESSICA CIRALSKY, MD

A 31-year-old woman presented with complaints of intermittent blurry vision, ocular redness at the end of the day, and itchy eyes. She stated that she was wearing glasses because her symptoms made wearing soft contact lenses intolerable, but her symptoms persisted even after discontinuing contact lens wear. She wanted to be evaluated for LASIK or some form of refractive surgery because she did not want to wear glasses.

The patient was an attorney who spent many hours in front of a computer screen. She had a history of seasonal allergies in the spring that she treated with sporadic use of over-the-counter cetirizine. Currently, she has been using an over-the-counter topical vasoconstrictor daily to alleviate her red eyes.

On examination, her BCVA was 20/20 OU and refraction was -2.50 +0.75 × 90 OU. Slit-lamp examination revealed trace punctate epithelial erosions and mild blepharitis OU. The dilated fundus examination result was normal.

Discussion

Dr Ciralsky: When patients tell me they are interested in refractive surgery, I often start by asking, “Why now?” I ask this question because I want to know if contact lens intolerance is the main reason they are seeking laser vision correction. Dry eye is 1 possible etiology for contact lens intolerance that has implications for surgical decision-making.

The intermittent blurry vision and contact lens intolerance in this patient might be signs of DED. I measure tear film

osmolarity as an initial screen for DED in all patients being considered for refractive surgery and perform the MMP-9 assay if I suspect DED.

Dr Rapuano: I sometimes use the point-of-care tests for initial evaluation of refractive surgery patients, especially if I have any concern regarding DED. Fluorescein staining was already done in this patient, but lissamine green staining detects dry eye earlier.^{37,38} I used to use rose bengal, but it is more painful than lissamine green²⁸; rose bengal is also more expensive and difficult to obtain. Topography is also important, which would be obtained routinely in any refractive surgery candidate. I think that a Schirmer test is informative only if the result is very low— ≤ 2 mm—or if it is very high—perhaps > 25 mm—assuming the test was done properly.

Dr Braga-Mele: The Schirmer test result can be normal in a patient who has DED if the disease is associated with MGD.

Case Continued

Central corneal thickness and topography were normal. Lissamine green staining and MMP-9 were both negative OU, Schirmer test score was 9 mm/5 min OU, TBUT was 8 seconds OU, and tear film osmolarity was 295 mOsm/L OD and 299 mOsm/L OS.

Dr Ciralsky: Considering the patient’s refraction, topography, and dry eye diagnostic test results, which showed only borderline abnormal results for the Schirmer score and TBUT, I would consider the patient a suitable candidate for LASIK. Her lifestyle behaviors and the fact that she is symptomatic, however, were red flags for me because all laser refractive surgery procedures can cause or exacerbate dry eye, and tear dysfunction can underlie chronic patient discomfort after surgery.³⁹

What are your thoughts about proceeding with LASIK in this patient?

Dr Braga-Mele: Dry eye can be exacerbated after LASIK, and the problem can persist for years. Management of dry eye before surgery can help mitigate problems postoperatively, but patients still need to be informed about the potential for worsening because this can affect their decision to undergo surgery.

Dr Rapuano: Diagnosing and managing DED before surgery is important so that the patient does not blame the surgeon for DED problems postoperatively. Because dry eye affects the measurements that are used for surgical planning, preoperative management of DED is also important for optimizing outcomes.

Dr Kim: I would worry about LASIK in this patient. With her history of allergy, she can be at increased risk for flap dislocation from eye rubbing.

Dr Ciralsky: How would you manage this patient?

Dr Braga-Mele: It is always important to look at the whole patient and think about the possible causes of dry eye. For example, I would consider whether this 31-year-old woman is having so much trouble with dry eye because of lifestyle

choices or if her dry eye might be associated with some other condition, such as rosacea or an autoimmune collagen vascular disease.

Dr Rapuano: I would tell her to stop using the vasoconstrictor drops and warn her about the potential for rebound redness. I would start topical anti-inflammatory treatment and preservative-free artificial tears and treat the blepharitis. In addition, I would let her know that she might need more intensive treatment for DED when using an oral antihistamine.

Dr Kim: In my experience, digital screen time is an important contributor to DED in the refractive surgery patient population. There is no harm in starting this patient on a topical anti-inflammatory medication—either lifitegrast or cyclosporine—and a short course of corticosteroid treatment could be considered to achieve more rapid improvement of her ocular surface before surgery.

I would not schedule surgery during the spring and/or fall allergy season. I would recommend she use a topical dual antihistamine/mast cell stabilizer to treat her ocular allergy symptoms and see if that could reduce her need for an oral antihistamine.

Are you using omega-3 fatty acid supplements to treat DED?

Dr Braga-Mele: Anecdotal evidence suggests that some patients feel better after using omega-3 fatty acids. I am not recommending them, however, because the DREAM study found no differences between outcomes of patients receiving omega-3 fatty acids and those of the placebo-treated control group.⁴⁰

Dr Rapuano: In the DREAM study, both the placebo group, which was being treated with olive oil, and the omega-3 group had significant improvements from baseline in their Ocular Surface Disease Index scores and objective tests of DED.⁴⁰ In my experience, some patients feel omega-3 supplements help and others do not. I never strongly recommended using omega-3 supplements, and I am less inclined to suggest it now because of the DREAM study.

Dr Kim: The olive oil used in the DREAM study could be considered an active control. Because I think omega-3 supplements have little to no downside, I am still using them and recommend that patients get a product in which the omega-3 fatty acids are in the re-esterified triglyceride form, which is what was used in the DREAM study.

Dr Ciralsky: I am not recommending that any patients start using an omega-3 supplement, but I also do not recommend that patients stop if they are already using a supplement and doing well.

Do you think a particular laser refractive surgical procedure is preferred for this patient?

Dr Kim: Although I do not do SMILE (small incision lenticule extraction), I think it might be preferred because it seems to cause fewer problems with dry eye than do LASIK or photorefractive keratectomy (PRK).⁴¹⁻⁴³ Many patients ask for LASIK because they know someone who has had it. If you are recommending a different procedure, it is important to explain

the relative pros and cons so that patients have proper expectations and can make an informed decision.

Dr Rapuano: I predominantly do PRK, and would recommend it for this patient. I believe that LASIK is an acceptable choice if the ocular surface has been optimized and if it is the patient's preference.

Dr Ciralsky: I also prefer PRK in patients with DED because in my experience, it causes fewer problems with dry eye than does LASIK. According to results of some studies, however, there might not be much of a difference between the 2 procedures after a longer follow-up to 6 or 12 months.^{44,45}

I do not have personal experience with SMILE. In theory, SMILE might cause less dry eye than LASIK because there is less corneal nerve severance with SMILE. A meta-analysis found that dry eye is less severe or less persistent after SMILE than after LASIK.⁴¹

Case Continued

The patient was started on warm compresses and a baby shampoo scrub for treatment of her mild blepharitis, along with a 10-day course of a topical corticosteroid followed by lifitegrast for 2 months. She was counseled about limiting her use of oral antihistamines and the topical vasoconstrictor; encouraged to see an allergist and to use topical nasal sprays and ophthalmic medications for her allergy symptoms; and educated on strategies for limiting computer vision syndrome.

Dr Kim: What has been your initial experience with lifitegrast?

Dr Braga-Mele: Just as cyclosporine, lifitegrast does not work in every patient. I estimate it is effective in 85% to 90% of patients, and I see improvement in the ocular surface within 2 to 3 months vs 3 to 6 months with cyclosporine. Lifitegrast, as does cyclosporine, can cause burning.^{33,34} Adding a corticosteroid when starting lifitegrast seems to improve tolerability.

Dr Ciralsky: I have had good results using lifitegrast in patients with mild-to-moderate DED, whereas nothing seems to work for my patients with very severe disease. Overall, lifitegrast has been very well tolerated. The 3 most common side effects I see in patients started on lifitegrast are blurred vision, abnormal taste (dysgeusia), and burning. I inform patients about the potential for these adverse events. I have not had anyone stop treatment because of problems with either blurring or abnormal taste, which improves with time. I estimate that approximately 2% of patients stop treatment because of severe burning.

Dr Rapuano: Burning is the biggest issue with lifitegrast I see in patients. It is not common, but it occurs in more than 2% of patients in my experience, and it can cause patients to stop treatment. I estimate that approximately 10% of patients experience blurred vision (that clears after 5 to 10 minutes), something that does not happen with cyclosporine; therefore, I tell patients to use lifitegrast before breakfast so that any blurring is gone by the time they have to drive to work. I was concerned that patients would not tolerate the dysgeusia, but I caution all my patients about the potential for a metallic taste; none of them have stopped treatment because of it.

Case Conclusion

The patient's dry eye test results improved. She underwent PRK without mitomycin C and continued lifitegrast for 3 months postoperatively. At her 1-year follow-up, the patient had 20/20 UCVA, no significant DED, and was happy.

CASE 3: DRY EYE AND SJÖGREN SYNDROME

FROM THE FILES OF CHRISTOPHER J. RAPUANO, MD

A 72-year-old woman presented in 2010 complaining about irritation, with burning and dryness in both eyes that began years ago and had worsened over the past 6 months. Her vision had also worsened. She had cataracts in both eyes; was using artificial tears with and without preservatives as needed; wore 2 sets of moisture goggles; and had tried topical cyclosporine emulsion, 0.05%, but stopped using it.

The patient had hypertension that was being treated with hydrochlorothiazide. Findings on examination were BCVA 20/60 OU, intraocular pressure 17 mm Hg OU, mild-to-moderate blepharitis/MGD, moderate diffuse superficial punctate keratopathy and fine filaments OU (**Figure 3**), TBUT 1 to 2 seconds OU, and moderate nuclear sclerotic cataract OU. Her fundus examination result was normal.

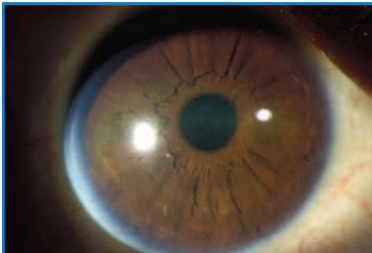
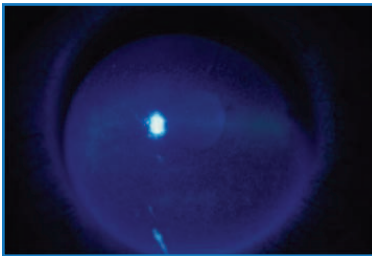


Figure 3. [Design: Please leave short space for caption TK.]
XXXXXXXXXXXXXXXXXXXX
XXXXXXXXXXXX



Dr Rapuano: What additional history questions would you consider asking?

Dr Ciralsky: Her low TBUT and use of moisture goggles make me worry that her ocular surface dryness is related to Sjögren syndrome or another collagen vascular disease. I would ask her if she has any systemic symptoms, such as dry mouth or joint pain. I would also like to know more about her experience with cyclosporine. When cyclosporine “fails”, I want to know if the patient failed to improve after an adequate trial or stopped using it early on because of stinging and burning.

Dr Rapuano: I asked about the cyclosporine, and the patient said she used it for a couple of weeks and stopped because she did not like it.

Case Continued

Further workup showed a Schirmer test score of 4 mm/5 min OD and 6 mm/5 min OS and tear osmolality of 304 mOsm/L OD and 315 mOsm/L OS.

Dr Rapuano: The low Schirmer scores, tear osmolality in the left eye, and intereye difference exceeding 8 to 10 mOsm/L are signs of dry eye.^{28,29}

Is there any other testing you would do?

Dr Ciralsky: I would want to do the MMP-9 assay and possibly meibography to assess her meibomian glands.

Dr Kim: I would consider serology to rule out Sjögren syndrome.

Dr Braga-Mele: You might also refer the patient to a rheumatologist for evaluation of an underlying systemic disorder.

Dr Rapuano: Those are all great ideas. Sjögren syndrome is a multisystem autoimmune disorder in which dry eye and dry mouth are early manifestations.⁴⁶ Patients with Sjögren syndrome might therefore first present to an ophthalmologist, but underreferral of patients with dry eye is an issue leading to underdiagnosis of Sjögren syndrome.⁴⁷

Sjögren syndrome–related dry eye is caused by lacrimal gland destruction, but patients with Sjögren syndrome have also been found to have increased meibomian gland destruction relative to patients with non-Sjögren dry eye.⁴⁸ Sjögren syndrome is a chronic progressive disease that is also associated with arthritis; kidney and pulmonary involvement; and increased risks of cardiovascular events, cerebrovascular events, lymphoma, and non-Hodgkin lymphoma.⁴⁶ Affected patients suffer a significant negative effect on quality of life. Early diagnosis of Sjögren syndrome is important to allow for appropriate surveillance and care, including intervention to limit morbidity.

Traditional serology testing for Sjögren syndrome using assays for anti-Sjögren syndrome-related antigen A/Ro, anti-Sjögren syndrome-related antigen B/La, rheumatoid factor, and antinuclear antigen can miss the diagnosis at an early disease stage.⁴⁶ A newer blood test for Sjögren syndrome measures the 4 traditional biomarkers plus 3 novel biomarkers that are autoantibodies to proteins specific to the salivary and lacrimal glands: salivary gland protein-1, parotid secretory protein, and carbonic anhydrase VI.⁴⁶ Although further study is needed, there is some evidence that the newer blood test might provide earlier diagnosis of Sjögren syndrome.⁴⁹

Sjögren syndrome has a prevalence of approximately 1.0% and develops primarily in women, typically in the 45- to 55-year-old age range.⁴⁶ If I suspect Sjögren syndrome because of severe dry eye, I ask about dry mouth, nasal or vaginal dryness, and back or joint pain.

My approach to treating this patient with Sjögren syndrome would include preservative-free artificial tears, ideally a thicker gel-type formulation during the day and an ointment at night or the cellulose cul-de-sac inserts. For anti-inflammatory treatment, she could try either cyclosporine ophthalmic

emulsion, 0.05%, again, the newer cyclosporine ophthalmic solution, 0.09%, or lifitegrast, 5%. Inserting punctal plugs is also reasonable. Short-term use of a topical corticosteroid could also be considered, especially in patients with evidence of active inflammation, mainly to “jump-start” the treatment. In addition, I would start an antibiotic ointment for her lid disease and speak with the physician who prescribed the hydrochlorothiazide about possibly changing her antihypertensive medication. If additional treatment for dry eye is needed, options include serum tears, punctal cautery, a scleral lens, and platelet rich plasma injections, which I, personally, have never used.

What treatment would you recommend for this patient?

Dr Kim: I am aggressive in treating Sjögren syndrome-related DED. As acute intervention to rehabilitate the ocular surface, I would consider placing an amniotic membrane and, ultimately, partial lateral tarsorrhaphy.

I would remove the filaments using a jeweler’s forceps because they can cause a lot of irritation. I would also start topical acetylcysteine, which might prevent recurrence of the filaments because of its mucolytic activity.⁵⁰

Dr Ciralsky: I often start patients who have significant ocular surface damage on a topical corticosteroid because I find it accelerates symptomatic improvement. Even though the patient we are discussing did not have an adequate trial with cyclosporine, perhaps she would do better with something different, so I would probably start lifitegrast. I would hold off on placing punctal plugs until the inflammation is controlled because I would not want to trap inflammatory mediators on the ocular surface. I agree that because she has severe DED, this patient is probably going to need more advanced treatments that might include serum tears and even a scleral lens. Like natural tears, serum tears contain proteins, epitheliotropic factors, neurotrophic factors, and other mediators to provide anti-inflammatory activity and support healing.¹² In my own practice, I have found a scleral lens to be a game changer in terms of treatment for patients with end-stage DED.

I would also remove the filaments, and then place a bandage contact lens on the eye while the surface heals. It is important to be aware, however, that the bandage contact lens can dry out if the ocular surface is very dry, and this can lead to problems of its own.

Dr Kim: We are fortunate to have a host of scleral lenses that can help with OSD and improve vision quality for patients with severe DED.

Dr Rapuano: I find that we have to be very careful with bandage soft contact lenses in patients with dry eye because

they can get ulcers rather quickly. I agree that scleral lenses can be extremely helpful for some patients.

Case Conclusion

The patient continued to use her moisture goggles. She was started on cyclosporine emulsion, 0.05%, and an antibiotic ointment and changed to a preservative-free ocular lubricant gel.

The patient was doing well on this treatment and achieved BCVA of 20/25 OU after undergoing cataract surgery. Her condition remained stable for several years, but when it began to progress, she had permanent partial lateral tarsorrhaphy and was started on serum tears and lifitegrast in addition to the cyclosporine.

Dr Rapuano: Oral pilocarpine and oral cevimeline have been reported to improve dry eye in patients with Sjögren syndrome.^{51,52} In my experience, however, these 2 agents improve dry mouth more than dry eye.

Do you prescribe oral secretagogue treatment for patients with Sjögren syndrome?

Dr Ciralsky: I leave decisions on systemic treatment to the rheumatologist. My patients who are using oral pilocarpine or oral cevimeline report that it helps dry eye and dry mouth.

Dr Kim: I typically do not prescribe oral secretagogues because they can cause a lot of bothersome side effects, but I also leave decisions on their use and that of immunosuppressants to the rheumatologists.

Dr Rapuano, do you have concerns about safety when using cyclosporine and lifitegrast in combination?

Dr Rapuano: I tell patients that it might or might not be helpful to use both medications, and that I do not expect a miracle cure. I have quite a few patients on the combination and have not seen issues related to adverse events. The biggest problem has been obtaining insurance coverage for both medications.

Dr Ciralsky: I see many patients with graft-vs-host disease. In those patients and in others with severe DED, I consider adding a second anti-inflammatory medication once they improve on the first drug. In my experience, patients might get some modest benefit from the additional medication. I have not seen any interactions or safety problems when using the 2 medications in combination.

Dr Braga-Mele: I have not used lifitegrast in combination with cyclosporine. I cannot think of a potential mechanism for an adverse interaction that would prevent me from doing so, but I would not expect a large additive benefit because lifitegrast and cyclosporine act on the same arm of the inflammatory process.



TAKE-HOME POINTS

Screen patients undergoing cataract or refractive surgery to identify DED.

- Use objective diagnostic tests because patients with DED can be asymptomatic

Optimize the ocular surface before planning cataract or refractive surgery and maintain treatment for DED postoperatively.

- Dry eye disease reduces the accuracy of measurements used in planning these procedures; reduces visual quality and quantity preoperatively and postoperatively; and is worsened by cataract and laser vision-correction surgery

Treatment for DED requires a multimodal approach that considers severity, the presence of inflammation, modifiable exogenous factors, and DED type (aqueous deficient and/or evaporative).

Sjögren syndrome is a chronic, progressive multisystem autoimmune disorder.

- Ophthalmologists need to recognize that dry eye is an early manifestation of Sjögren syndrome because early diagnosis and treatment of the disease can limit its sequelae
- A newer diagnostic blood test might allow for diagnosis when the disease is at an early stage
- Management of Sjögren syndrome-related DED requires aggressive treatment

REFERENCES

1. The epidemiology of dry eye disease: report of the Epidemiology Subcommittee of the International Dry Eye WorkShop (2007). *Ocul Surf.* 2007;5(2):93-107.
2. New Allergan survey shows 48% have dry eye symptoms. News from the American Optometric Association Web site. <https://newsfromaoa.wordpress.com/2011/11/06/new-allergan-survey-shows-48-have-dry-eye-symptoms/>. Published November 6, 2011. Accessed March 8, 2019.
3. Farrand KF, Fridman M, Stillman IO, Schaumberg DA. Prevalence of diagnosed dry eye disease in the United States among adults aged 18 years and older. *Am J Ophthalmol.* 2017;182:90-98.
4. Moon JH, Kim KW, Moon NJ. Smartphone use is a risk factor for pediatric dry eye disease according to region and age: a case control study. *BMC Ophthalmol.* 2016;16(1):188.
5. Moss SE, Klein R, Klein BE. Prevalence of and risk factors for dry eye syndrome. *Arch Ophthalmol.* 2000;118(9):1264-1268.
6. Schaumberg DA, Sullivan DA, Buring JE, Dana MR. Prevalence of dry eye syndrome among US women. *Am J Ophthalmol.* 2003;136(2):318-326.
7. Schaumberg DA, Dana R, Buring JE, Sullivan DA. Prevalence of dry eye disease among US men: estimates from the Physicians' Health Studies. *Arch Ophthalmol.* 2009;127(6):763-768.
8. Nelson JD, Helms H, Fiscella R, Southwell Y, Hirsch JD. A new look at dry eye disease and its treatment. *Adv Ther.* 2000;17(2):84-93.
9. Schiffman RM, Walt JG, Jacobsen G, Doyle JJ, Lebovics G, Sumner W. Utility assessment among patients with dry eye disease. *Ophthalmology.* 2003;110(7):1412-1419.
10. Buchholz P, Steeds CS, Stern LS, et al. Utility assessment to measure the impact of dry eye disease. *Ocul Surf.* 2006;4(3):155-161.
11. Uchino M, Schaumberg DA. Dry eye disease: impact on quality of life and vision. *Curr Ophthalmol Rep.* 2013;1(2):51-57.
12. Jones L, Downie LE, Korb D, et al. TFOS DEWS II Management and Therapy report. *Ocul Surf.* 2017;15(3):575-628.
13. Milner MS, Beckman KA, Luchs JJ, et al. Dysfunctional tear syndrome: dry eye disease and associated tear film disorders - new strategies for diagnosis and treatment. *Curr Opin Ophthalmol.* 2017;27(suppl 1):3-47.
14. Kim T. Paper presented at: 2018 American Society of Cataract and Refractive Surgery/American Society of Ophthalmic Administrators Symposium & Congress; April 13-17, 2018; Washington, DC.
15. Craig JP, Nichols KK, Akpek EK, et al. TFOS DEWS II Definition and Classification report. *Ocul Surf.* 2017;15(3):276-283.
16. Sullivan BD, Crews LA, Messmer EM, et al. Correlations between commonly used objective signs and symptoms for the diagnosis of dry eye disease: clinical implications. *Acta Ophthalmol.* 2014;92(2):161-166.
17. Nichols KK, Nichols JJ, Mitchell GL. The lack of association between signs and symptoms in patients with dry eye disease. *Cornea.* 2004;23(8):762-770.
18. Lemp MA, Crews LA, Bron AJ, Foulks GN, Sullivan BD. Distribution of aqueous-deficient and evaporative dry eye in a clinic-based patient cohort: a retrospective study. *Cornea.* 2012;31(5):472-478.
19. Tutt R, Bradley A, Begley C, Thibos LN. Optical and visual impact of tear break-up in human eyes. *Invest Ophthalmol Vis Sci.* 2000;41(13):4117-4123.
20. Goto E, Yagi Y, Matsumoto Y, Tsubota K. Impaired functional visual acuity of dry eye patients. *Am J Ophthalmol.* 2002;133(2):181-186.



REFERENCES (CONTINUED)

21. Montés-Micó R. Role of the tear film in the optical quality of the human eye. *J Cataract Refract Surg.* 2007;33(9):1631-1635.
22. Levinson BA, Rapuano CJ, Cohen EJ, Hammersmith KM, Ayres BD, Laibson PR. Referrals to the Wills Eye Institute Cornea Service after laser in situ keratomileusis: reasons for patient dissatisfaction. *J Cataract Refract Surg.* 2008;34(1):32-39.
23. Woodward MA, Randleman JB, Stulting RD. Dissatisfaction after multifocal intraocular lens implantation. *J Cataract Refract Surg.* 2009;35(6):992-997.
24. Epitropoulos AT, Matossian C, Berdy GJ, Malhotra RP, Potvin R. Effect of tear osmolarity on repeatability of keratometry for cataract surgery planning. *J Cataract Refract Surg.* 2015;41(8):1672-1677.
25. Vaziri K, Schwartz SG, Kishor K, Flynn HW Jr. Endophthalmitis: state of the art. *Clin Ophthalmol.* 2015;9:95-108.
26. Trattler WB, Majmudar PA, Donnenfeld ED, McDonald MB, Stonecipher KG, Goldberg DF. The Prospective Health Assessment of Cataract Patients' Ocular Surface (PHACO) study: the effect of dry eye. *Clin Ophthalmol.* 2017;11:1423-1430.
27. Gupta PK, Drinkwater OJ, VanDusen KW, Brissette AR, Starr CE. Prevalence of ocular surface dysfunction in patients presenting for cataract surgery evaluation. *J Cataract Refract Surg.* 2018;44(9):1090-1096.
28. Wolffsohn JS, Arita R, Chalmers R, et al. TFOS DEWS II Diagnostic Methodology report. *Ocul Surf.* 2017;15(3):539-574.
29. TearLab Corporation. TearLabTM Osmolarity System: Clinical Utility Guide. <https://www.tearlab.com/pdfs/TearLab%20Clinical%20Utility%20Guide.pdf>. Accessed March 8, 2019.
30. Yu Y, Hua H, Wu M, et al. Evaluation of dry eye after femtosecond laser-assisted cataract surgery. *J Cataract Refract Surg.* 2015;41(12):2614-2623.
31. Donnenfeld ED, Solomon R, Roberts CW, Wittppenn JR, McDonald MB, Perry HD. Cyclosporine 0.05% to improve visual outcomes after multifocal intraocular lens implantation. *J Cataract Refract Surg.* 2010;36(7):1095-1100.
32. Sheppard JD, Torkildsen GL, Lonsdale JD, et al; OPUS-1 Study Group. Lifitegrast ophthalmic solution 5.0% for treatment of dry eye disease: results of the OPUS-1 phase 3 study. *Ophthalmology.* 2014;121(2):475-483.
33. Tauber J, Karpecki P, Latkany R, et al; OPUS-2 Investigators. Lifitegrast ophthalmic solution 5.0% versus placebo for treatment of dry eye disease: results of the randomized phase III OPUS-2 study. *Ophthalmology.* 2015;122(12):2423-2431.
34. Holland EJ, Luchs J, Karpecki PM, et al. Lifitegrast for the treatment of dry eye disease: results of a phase III, randomized, double-masked, placebo-controlled trial (OPUS-3). *Ophthalmology.* 2017;124(1):53-60.
35. Avunduk AM, Avunduk MC, Varnell ED, Kaufman HE. The comparison of efficacies of topical corticosteroids and nonsteroidal anti-inflammatory drops on dry eye patients: a clinical and immunocytochemical study. *Am J Ophthalmol.* 2003;136(4):593-602.
36. Pflugfelder SC, Maskin SL, Anderson B, et al. A randomized, double-masked, placebo-controlled, multicenter comparison of loteprednol etabonate ophthalmic suspension, 0.5%, and placebo for treatment of keratoconjunctivitis sicca in patients with delayed tear clearance. *Am J Ophthalmol.* 2004;138(3):444-457.
37. Uchiyama E, Aronowicz JD, Butovich IA, McCulley JP. Pattern of vital staining and its correlation with aqueous tear deficiency and meibomian gland dropout. *Eye Contact Lens.* 2007;33(4):177-179.
38. Cunningham DN, Whitley WO. The how and why of diagnosing dry eye. *Rev Optometry.* <https://www.reviewofoptometry.com/article/the-how-and-why-of-diagnosing-dry-eye>. Published March 15, 2016. Accessed March 8, 2019.
39. Nettune GR, Pflugfelder SC. Post-LASIK tear dysfunction and dysesthesia. *Ocul Surf.* 2010;8(3):135-145.
40. Asbell PA, Maguire MG, Pistilli M, et al; Dry Eye Assessment and Management Study Research Group. n-3 fatty acid supplementation for the treatment of dry eye disease. *N Engl J Med.* 2018;378(18):1681-1690.
41. Kobashi H, Kamiya K, Shimizu K. Dry eye after small incision lenticule extraction and femtosecond laser-assisted LASIK: meta-analysis. *Cornea.* 2017;36(1):85-91.
42. Denoyer A, Landman E, Trinh L, Faure JF, Auclin F, Baudouin C. Dry eye disease after refractive surgery: comparative outcomes of small incision lenticule extraction versus LASIK. *Ophthalmology.* 2015;122(4):669-676.
43. Schallhorn JM, Pelouskova M, Oldenburg C, et al. Effect of gender and procedure on patient-reported dry eye symptoms after laser vision correction. *J Refract Surg.* 2019;35(3):161-168.
44. Lee JB, Ryu CH, Kim J, Kim EK, Kim HB. Comparison of tear secretion and tear film instability after photorefractive keratectomy and laser in situ keratomileusis. *J Cataract Refract Surg.* 2000;26(9):1326-1331.
45. Murakami Y, Manche EE. Prospective, randomized comparison of self-reported postoperative dry eye and visual fluctuation in LASIK and photorefractive keratectomy. *Ophthalmology.* 2012;119(11):2220-2224.
46. Beckman KA, Luchs J, Milner MS, Ambrus JL Jr. The potential role of early biomarker testing as part of a modern, multidisciplinary approach to Sjögren's syndrome diagnosis. *Adv Ther.* 2017;34(4):799-812.
47. Bunya VY, Fernandez KB, Ying GS, et al. Survey of ophthalmologists regarding practice patterns for dry eye and Sjogren syndrome. *Eye Contact Lens.* 2018;44(suppl 2):S196-S201.
48. Zang S, Cui Y, Cui Y, Fei W. Meibomian gland dropout in Sjögren's syndrome and non-Sjögren's dry eye patients. *Eye (Lond).* 2018;32(11):1681-1687.
49. De Langhe E, Bossuyt X, Shen L, Malyavantham K, Ambrus JL, Suresh L. Evaluation of autoantibodies in patients with primary and secondary Sjogren's syndrome. *Open Rheumatol J.* 2017;11:10-15.
50. Koh JW, Yang YR. Topical N-acetylcysteine on patients with refractory filamentary keratitis. *Acta Ophthalmologica.* 2016;94(S256).
51. Vivino FB, Al-Hashimi I, Khan Z, et al. Pilocarpine tablets for the treatment of dry mouth and dry eye symptoms in patients with Sjögren syndrome: a randomized, placebo-controlled, fixed-dose, multicenter trial. P92-01 Study Group. *Arch Intern Med.* 1999;159(2):174-181.
52. Ono M, Takamura E, Shinozaki K, et al. Therapeutic effect of cevimeline on dry eye in patients with Sjögren's syndrome: a randomized, double-blind clinical study. *Am J Ophthalmol.* 2004;138(1):6-17.

For instant processing, complete the CME Post Test online at
<https://tinyurl.com/XXXXXXXXXXXXXXXXXXXX>



CME POST TEST QUESTIONS

To obtain AMA PRA Category 1 Credit™ for this activity, complete the CME Post Test and course evaluation online at <https://tinyurl.com/XXXXXXXXXXXXXXXXXXXX>. Upon successful completion of the post test and evaluation, you will be able to generate an instant certificate of credit.

See detailed instructions under **To Obtain AMA PRA Category 1 Credit™** on page 2.

- Increasing prevalence of DED in younger adults is thought to be associated with:
 - Digital device use
 - Genetic predisposition
 - Increasing allergy prevalence
 - More time spent indoors
- Which finding would lead to treatment of DED with an anti-inflammatory agent?
 - Low tear osmolality
 - Schirmer score of 10 mm/5 min
 - Positive MMP-9 test
 - TBUT of 10 seconds
- Which tear osmolality test result (OD/OS) should raise suspicion for DED?
 - 282/285 mOsm/L
 - 300/307 mOsm/L
 - 294/306 mOsm/L
 - 305/306 mOsm/L
- Corneal topography in a patient with DED can show _____.
 - Faux astigmatism
 - Irregular astigmatism
 - Irregular mires
 - All the above
- In the Tear Film & Ocular Surface Society Dry Eye WorkShop II definition of DED, which of the following is NOT mentioned as having an etiologic role?
 - Aqueous deficiency
 - Neurosensory abnormalities
 - Ocular surface inflammation
 - Tear film hyperosmolality
- DED is reported to worsen after cataract surgery _____.
 - Only in patients having arcuate keratotomy
 - Only if it was not treated prior to surgery
 - More with femtosecond-assisted cataract surgery than with conventional phacoemulsification
 - More with conventional phacoemulsification than with femtosecond-assisted cataract surgery
- A patient seeking spectacle independence for distance after cataract surgery presents with complaints of blurry vision. Topography shows 1.5 D of regular astigmatism, and the patient has a positive MMP-9 test. Which is the most appropriate course of action?
 - Proceed with the surgery with a plan to implant an aspheric monofocal IOL with limbal relaxing incisions
 - Proceed with the surgery with a plan to use a toric IOL
 - Conduct further diagnostic testing
 - Start a topical nonsteroidal anti-inflammatory drug to reduce inflammation from the DED and have the patient return in 1 week
- A patient complains of ocular discomfort and blurry vision and has 2+ corneal staining, mildly altered meibum, tear osmolality > 300 mOsm/L OU, and a positive MMP-9 test OU. Which treatment regimen is most appropriate?
 - Artificial tears and punctal occlusion
 - Artificial tears and oral omega-3 fatty acid supplementation
 - Artificial tears and lid hygiene
 - Artificial tears, lid hygiene and lifitegrast, 5% or cyclosporine, 0.05% or 0.09%
- In the DREAM study, what was the effect of treatment with omega-3 fatty acids in patients with DED?
 - No benefit compared with artificial tears
 - No benefit compared with olive oil
 - Improved DED only in those with DED related to MGD
 - Improved symptoms of DED (Ocular Surface Disease Index scores), but not objective signs
- A 35-year-old woman wearing glasses to correct her low myopic astigmatism decides she would like to have refractive surgery so that she could see better without glasses when playing golf and tennis. On examination, she has mild MGD, rosacea, and punctate epithelial erosions. She starts treatment with lid hygiene, artificial tears, and doxycycline, and after 2 months, her ocular surface is improved. Which approach might give her the best refractive and functional results while minimizing the potential for problems with dry eye?
 - Contact lens monovision
 - LASIK with a wavefront-optimized technique
 - Refractive lens exchange with a multifocal toric IOL
 - SMILE

