



VENTANA PD-L1 (SP142) Assay

Interpretation Guide for Triple-Negative Breast Carcinoma (TNBC)

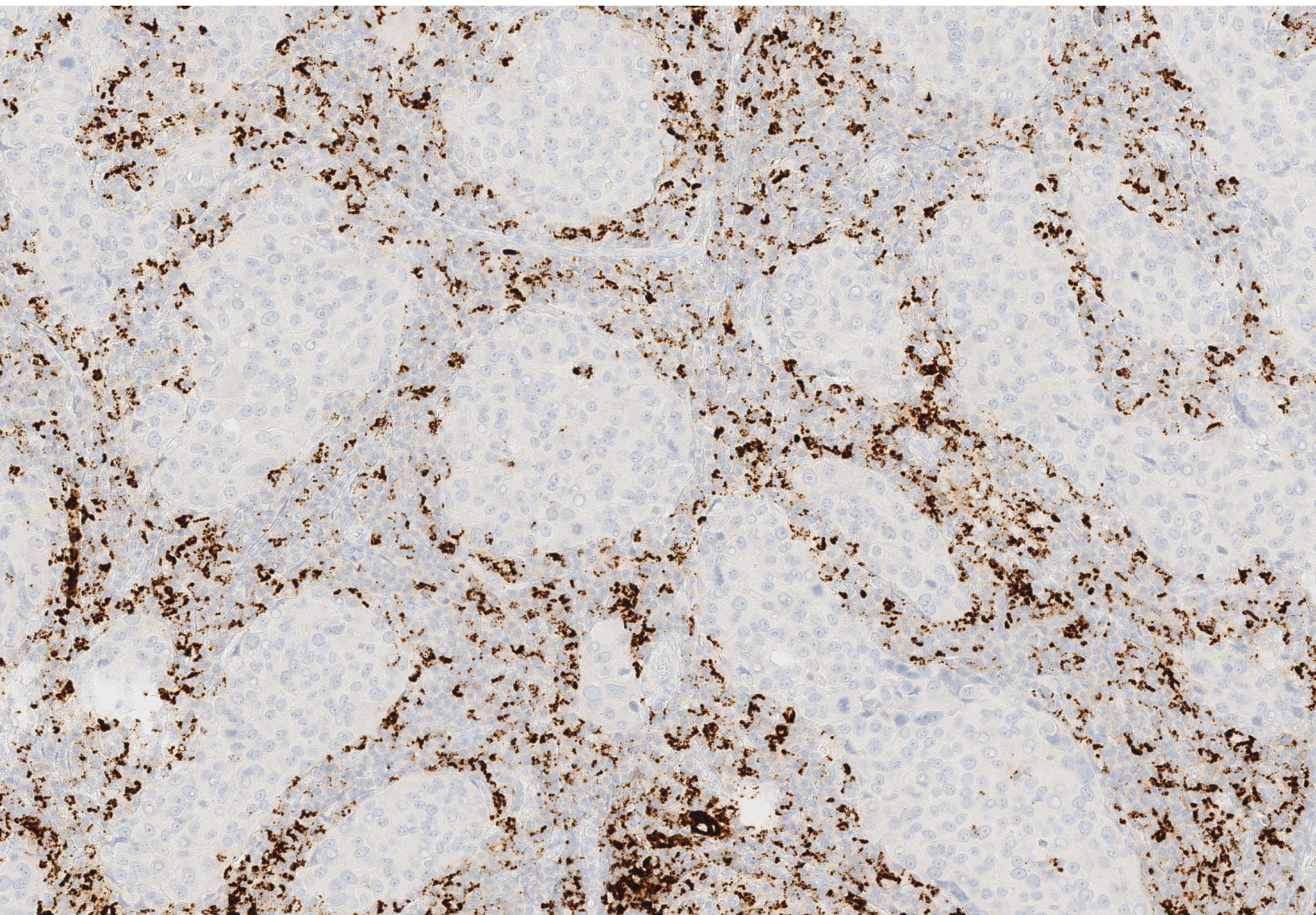


Table of Contents

Introduction	1
<hr/>	
Intended Use	3
<hr/>	
Intended Use of product	3
Purpose of Interpretation Guide	3
<hr/>	
Clinical Evaluation	4
<hr/>	
Staining Overview	4
Staining Characteristics	5
IC Staining	5
Differentiation of IC from TC Staining	8
Scoring Algorithm	10
Scoring Method	12
Controls	15
Specimen Workflow	17
<hr/>	
Reference Images	19
<hr/>	
Example Cases: IC < 1% IC	21
Example Cases: IC ≥ 1% IC	26
Challenging Cases	32
Staining Artifacts	39
<hr/>	
Impact of Pre-analytical Conditions on VENTANA PD-L1 (SP142) Assay	42
<hr/>	
Acceptable Fixation Conditions to Achieve Optimal Staining Results	42
Cut Slide Stability	43
<hr/>	
References	44
<hr/>	

Introduction

VENTANA PD-L1 (SP142) Assay is an immunohistochemical assay utilizing an anti-PD-L1 rabbit monoclonal primary antibody to recognize the PD-L1 protein. This assay was co-developed by Roche/Ventana Medical Systems, Inc. (Ventana) and Roche/Genentech to identify patients with locally advanced or metastatic triple-negative breast carcinoma (TNBC) who are most likely to respond to treatment with TECENTRIQ® (atezolizumab).

TNBC is characterized by the absence of immunostaining for estrogen receptor (ER), progesterone receptor (PR), and human epidermal growth factor receptor 2 (HER2). Overall, approximately 15%–20% of breast cancers are classified as TNBC. TNBCs are more likely to have aggressive features, such as a high proliferative rate, and exhibit an invasive phenotype. Patients with metastatic TNBC exhibit a poor clinical outcome, generally with rapid progression and a median overall survival (OS) of less than 1 year.¹

PD-L1 is a transmembrane protein that downregulates immune responses through binding to its two receptors programmed death-1 (PD-1) and B7.1 (Figure 1). PD-1 is an inhibitory receptor expressed on T cells following T-cell activation, which is sustained in states of chronic stimulation such as in chronic infection or cancer.² Ligation of PD-L1 with PD-1 inhibits T-cell proliferation, cytokine production, and cytolytic activity, leading to the functional inactivation or exhaustion of T cells. B7.1 is a molecule expressed on antigen presenting cells and activated T cells. PD-L1 binding to B7.1 on T cells and antigen presenting cells can mediate downregulation of immune responses, including inhibition of T-cell activation and cytokine production.³ PD-L1 expression has been observed in immune cells and tumor cells.^{4,5} Aberrant expression of PD-L1 on tumor cells has been reported to impede anti-tumor immunity, resulting in immune

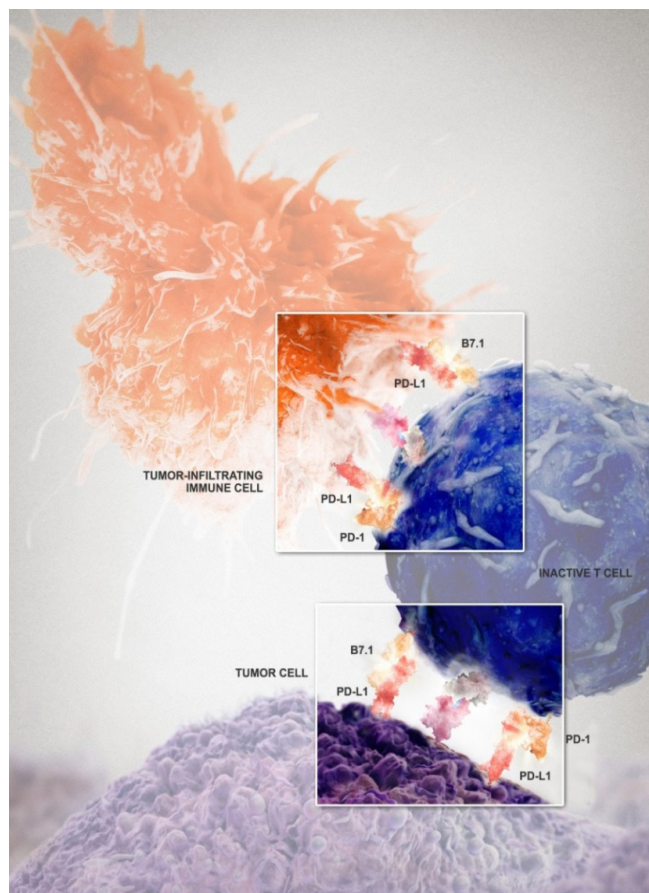


Figure 1: PD-L1 pathway

evasion.² Therefore, interruption of the PD-L1/PD-1 pathway represents an attractive strategy to reinvigorate tumor-specific T-cell immunity suppressed by the expression of PD-L1 in the tumor microenvironment. Targeting the PD-L1 pathway with atezolizumab has demonstrated activity in patients with advanced malignancies who have failed standard-of-care therapies, including patients with TNBC.⁶

Intended Use

Intended Use of product

Refer to the corresponding VENTANA PD-L1 (SP142) Assay package insert for the detailed intended use of this product including cutoffs and the associated indications.

Note: Use of this diagnostic with indicated therapies may not be approved in all countries. Please consult your local Roche representative for local approvals.

Purpose of Interpretation Guide

This guide is intended to:

- Provide pathologists with a tool to facilitate the clinical evaluation of formalin-fixed, paraffin-embedded (FFPE) TNBC sections stained with VENTANA PD-L1 (SP142) Assay in accordance with the proposed product labeling.
- Provide photographic images that illustrate the staining patterns that may result from staining of TNBC tissues with the VENTANA PD-L1 (SP142) Assay.
- Provide example images of challenging cases to provide guidance in their evaluation.
- Provide guidance in using a human benign tonsil-positive control tissue which serves as a tissue control when stained with the VENTANA PD-L1 (SP142) Assay.

Clinical Evaluation

Staining Overview

Immunohistochemical (IHC) staining with VENTANA PD-L1 (SP142) Assay demonstrates staining in tumor-infiltrating immune cells (IC) (Figure 2) and occasionally in tumor cells (TC) (Figure 3). Detailed staining characteristics are described in the Staining Characteristics section.

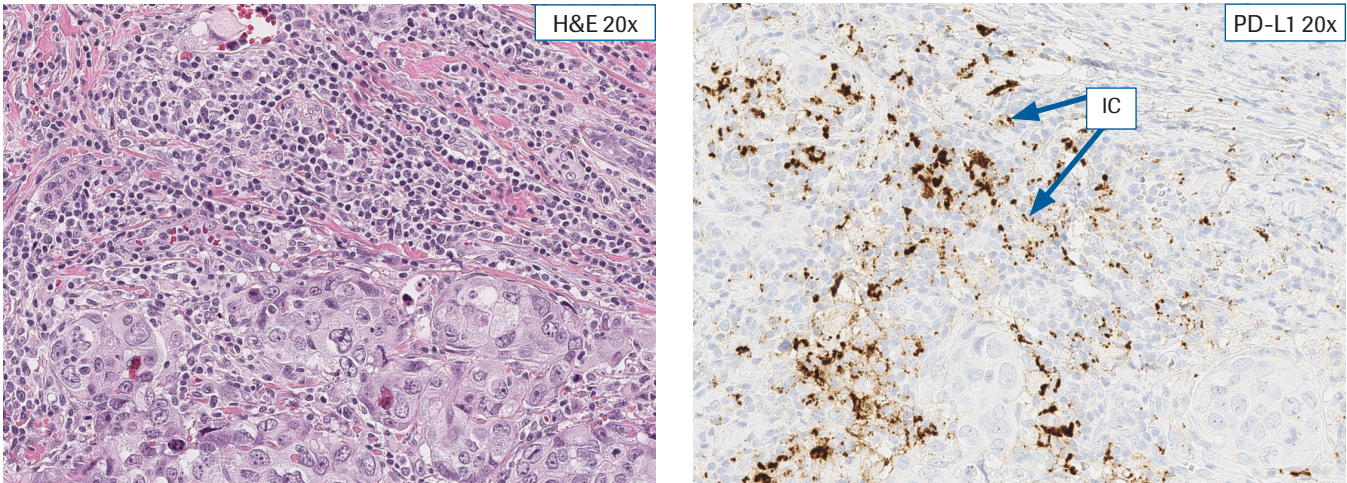


Figure 2: TNBC tissue showing dark brown punctate and linear IC staining.

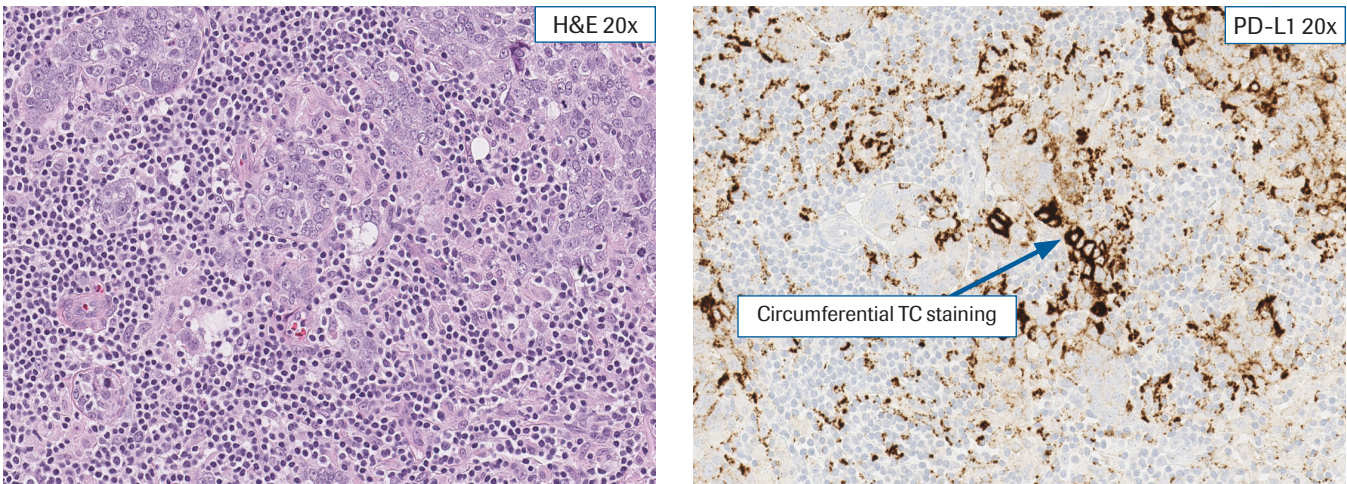


Figure 3: TNBC tissue showing moderate to strong circumferential TC membrane staining.

Staining Characteristics

PD-L1 staining with VENTANA PD-L1 (SP142) Assay in TNBC tissues demonstrates staining in IC (Figure 4 - Figure 8) as well as in TC (Figure 9 - Figure 11). The images in this interpretation guide are snapshots from scanned slides.

A graphical representation of VENTANA PD-L1 (SP142) Assay-labeled IC is provided in the Reference Images section of this interpretation guide. The isotype-matched Rabbit Monoclonal Negative Control Ig is used to evaluate the presence of background in test samples and establish a staining intensity baseline.

IC Staining

IC are immune cells present in the intratumoral and contiguous peritumoral stroma. VENTANA PD-L1 (SP142) Assay stain highlights a heterogeneous population of immune cells; the majority of which are morphologically consistent with lymphocytes, macrophages, dendritic cells, and granulocytes.

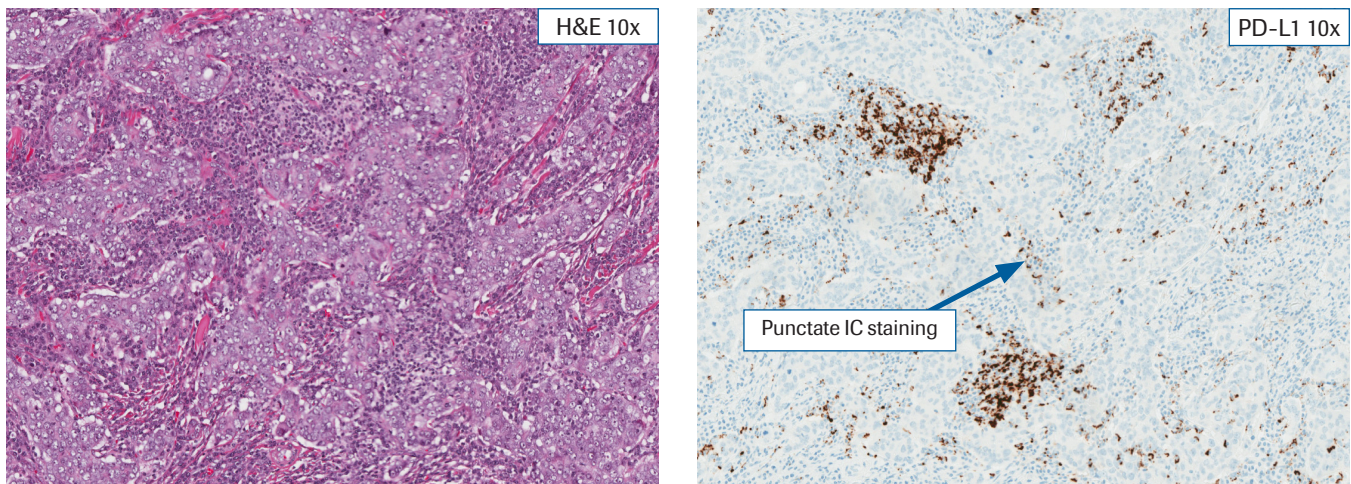


Figure 4: Immune cells often show dark brown punctate or linear staining which is the predominant IC staining pattern observed in the majority of tissues.

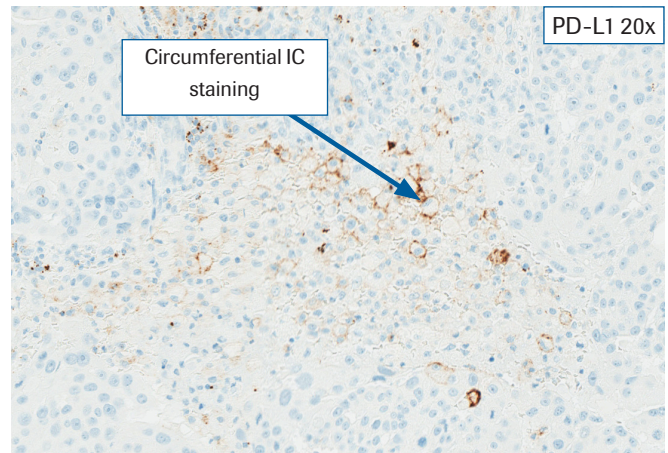
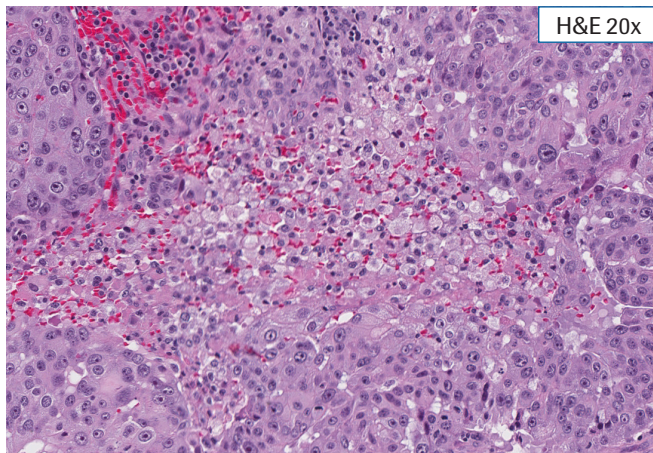


Figure 5: Occasionally, circumferential IC membrane staining is also observed, especially in cells that are morphologically consistent with macrophages and/or dendritic cells.

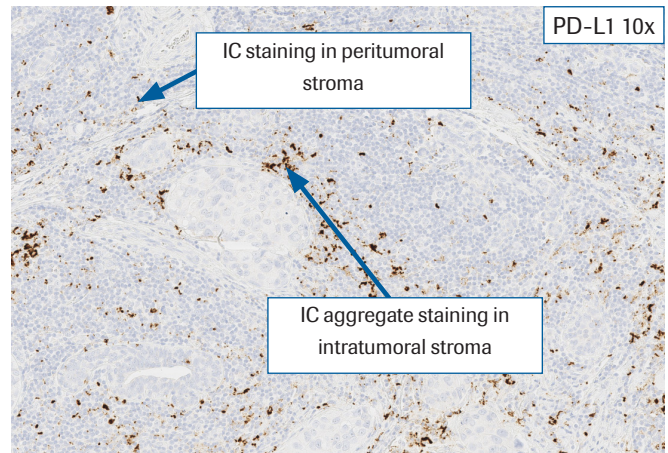
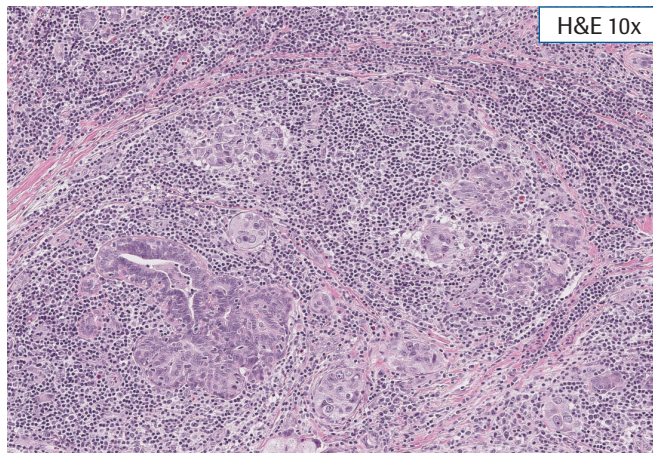


Figure 6: IC staining is often seen as aggregates whether in intratumoral or peritumoral stroma (invasive margin), or in both locations.

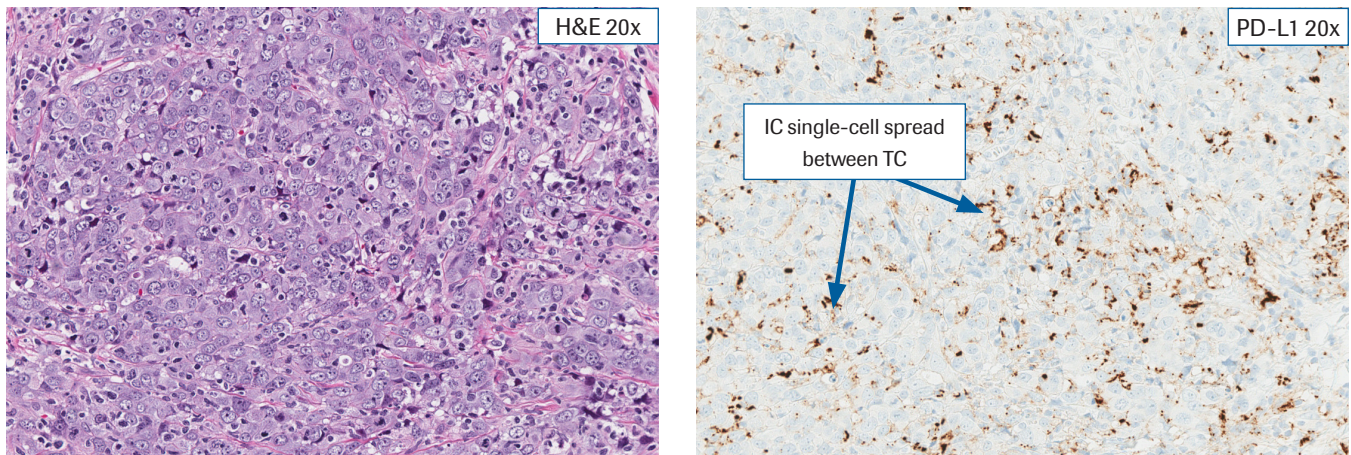


Figure 7: Occasionally, IC staining is also observed in the form of focal or diffuse intratumoral scattered single-cells or small aggregates dispersed among TC.

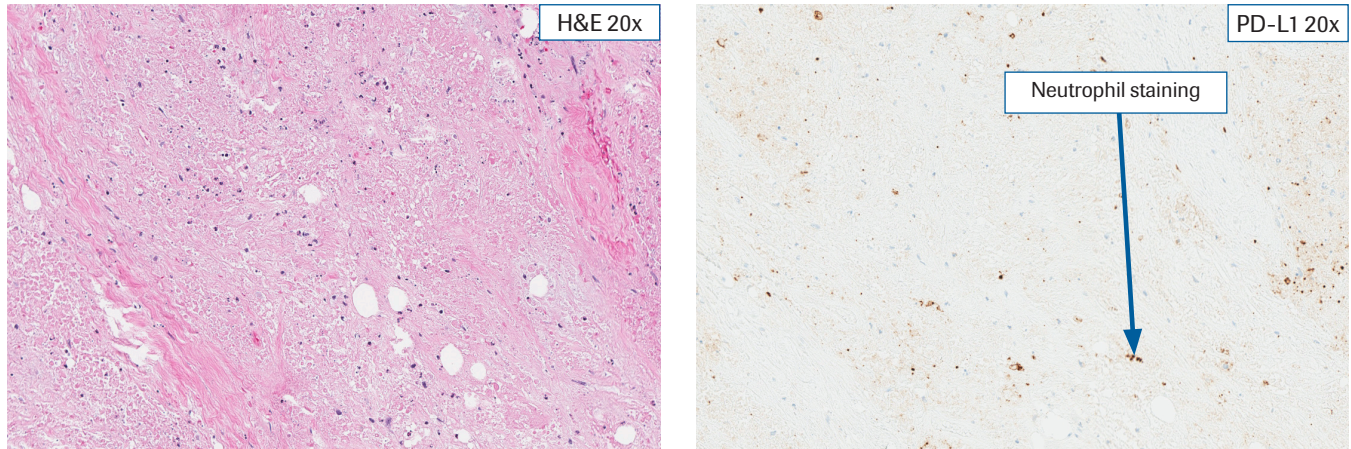


Figure 8: Rarely, IC staining can be observed as fine punctate membrane staining along with diffuse granular staining in neutrophils. Neutrophil staining can be seen dispersed among tumor cells, in the intratumoral or peritumoral stroma or as aggregates. Neutrophils in blood and serum can stain similar to neutrophils in stroma. Neutrophil staining in blood and serum or blood vessels should not be included in scoring. Neutrophilic debris, also necrotic debris, can show PD-L1 staining and should be excluded from scoring. Only when neutrophils are present in the stroma they should be included in scoring.

Differentiation of IC from TC Staining

TC staining is occasionally observed in TNBC. IC staining can be observed in association with TC staining, but when present, may interfere with IC scoring. Whenever TC staining is present, distinction of IC requires H&E examination for evaluation of presence and amount of IC and high power visualization of PD-L1-stained slide.

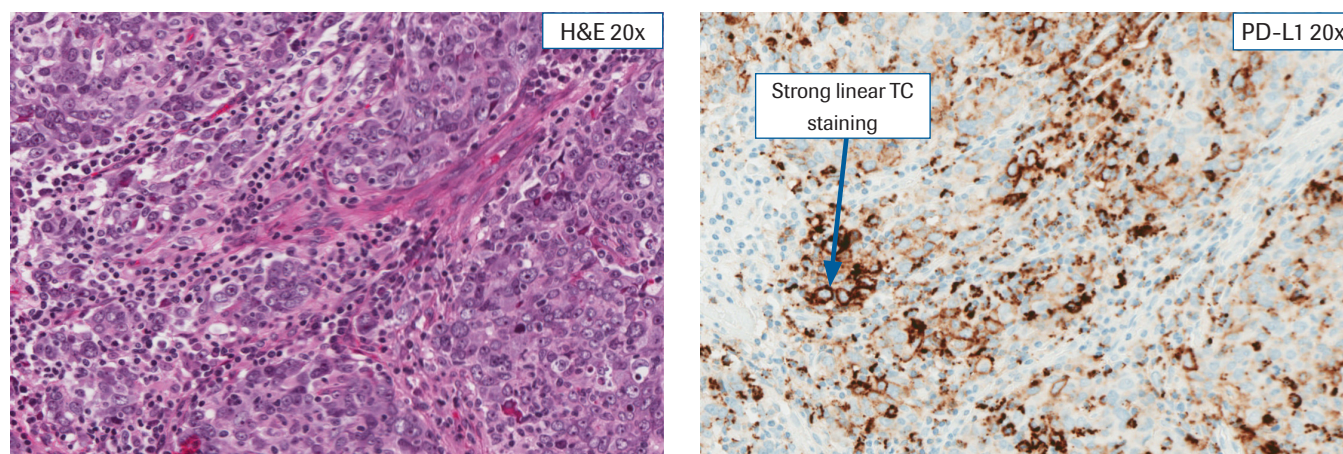


Figure 9: TC can exhibit moderate to strong and partial or complete circumferential membrane staining. When TC show strong linear membrane staining and there are no identifiable IC among the tumor cell groups, evaluate the stroma and where possible, the TC groups for IC staining.

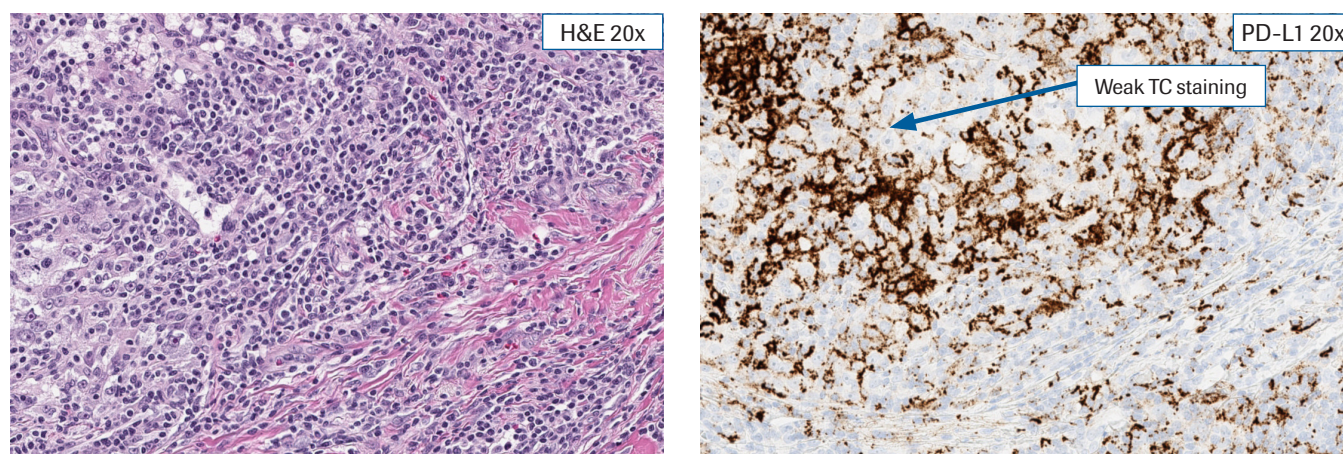


Figure 10: Sometimes weak membrane TC staining is observed which requires high power visualization for confirmation. When there is weak to moderate TC staining with interspersed dark staining IC, and H&E shows IC within TC groups, evaluate both TC groups and stroma for IC staining.

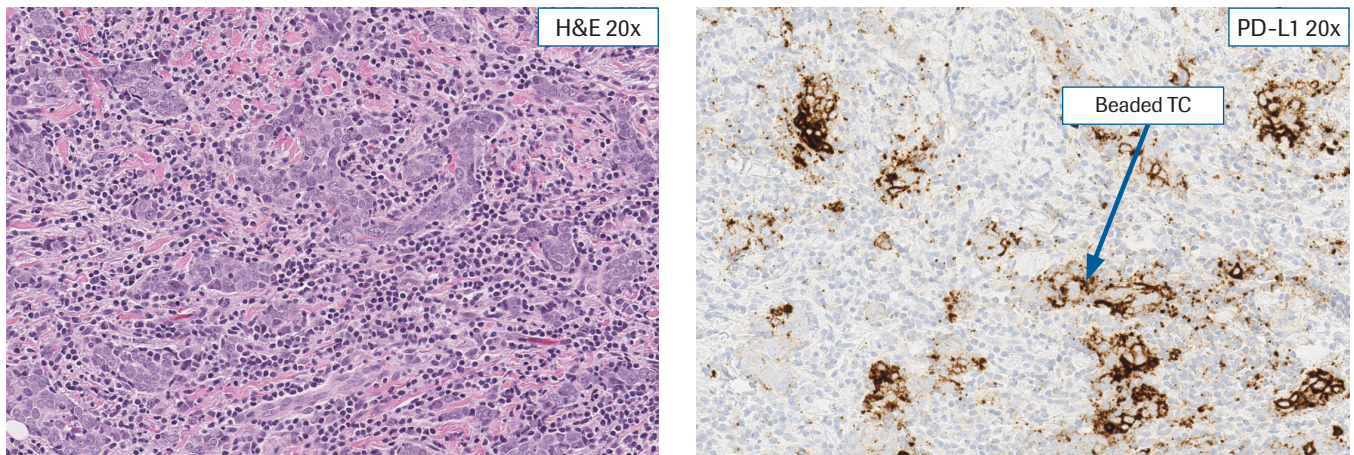


Figure 11: When TC staining is dark and granular or beaded and the H&E slide shows tumor-infiltrating immune cells among TC, evaluate IC staining in both tumor cell regions as well as stroma. This particular scenario might require careful examination at high power to assign the visualized staining to IC or TC. Linear staining in association with TC should be attributed to TC staining. Punctate staining should be attributed to IC staining.

Scoring Algorithm

Evaluating VENTANA PD-L1 (SP142) Assay in TNBC:

TNBC tissue samples obtained from resections, and core needle biopsies from both primary and metastatic sites are acceptable. Cytology samples and decalcified bone specimens are unacceptable due to lack of validation studies. TNBC tissue is considered adequate for VENTANA PD-L1 (SP142) Assay evaluation if it contains at least 50 viable tumor cells with associated stroma. Each case is stained with VENTANA PD-L1 (SP142) Assay and a matched negative reagent control (NRC), Rabbit Monoclonal Negative Control Ig. Tumor-infiltrating immune cells (IC) labeled with VENTANA PD-L1 (SP142) Assay are evaluated for presence or absence of the DAB signal. The matched NRC-stained slide is used to assess non-specific background staining and degree of background staining known to occur due to specific tissue elements.

NOTE: OptiView DAB IHC Detection Kit and OptiView Amplification Kit are the only detection reagents that are recommended for use with the VENTANA PD-L1 (SP142) Assay.

The scoring algorithm for VENTANA PD-L1 (SP142) Assay in TNBC is provided below in Table 1. Representative cases are discussed in the Reference Images section.

Tumor-infiltrating immune cells (IC) are scored as the proportion of tumor area that is occupied by PD-L1 staining IC of any intensity. A specimen should be considered to have PD-L1 expression if the specimen exhibits $\geq 1\%$ IC. If the specimen contains PD-L1 staining of any intensity in IC occupying $\geq 1\%$ of tumor area, the case will be assigned a PD-L1 expression level of $\geq 1\%$ IC. Tumor-infiltrating immune cells (IC) are immune cells present in the intratumoral and contiguous peritumoral stroma that include lymphocytes, macrophages, and cells with dendritic or reticular morphology. A PD-L1 expression level assessment will be given for each case according to the criteria in Table 1. Table 2 lists the IC interpretation criteria.

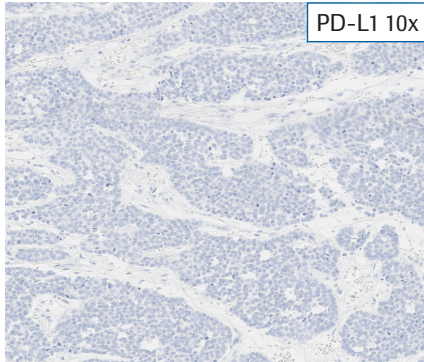
Table 1: VENTANA PD-L1 (SP142) Assay Scoring Algorithm for Triple-Negative Breast Carcinoma

Criteria/Characteristics	PD-L1 Expression
Absence of any discernible PD-L1 staining OR Presence of discernible PD-L1 staining of any intensity in tumor-infiltrating immune cells covering < 1% of tumor area occupied by tumor cells, associated intratumoral, and contiguous peritumoral stroma	< 1% IC
Presence of discernible PD-L1 staining of any intensity in tumor-infiltrating immune cells covering $\geq 1\%$ of tumor area occupied by tumor cells, associated intratumoral, and contiguous peritumoral stroma	$\geq 1\%$ IC

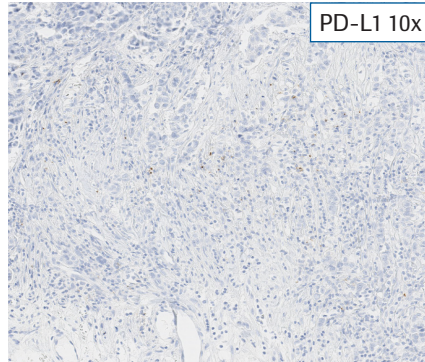
Table 2: Tumor-infiltrating Immune Cell (IC) Interpretation Criteria

Attributes	Descriptions
Type of cells showing staining	Lymphocytes, macrophages, dendritic cells, and granulocytes
Type of cells included in scoring	Lymphocytes, macrophages, dendritic cells, and granulocytes
Pattern	Aggregates in stroma, single cells dispersed among tumor cells with punctate, linear or circumferential staining
Denominator for scoring	Tumor area

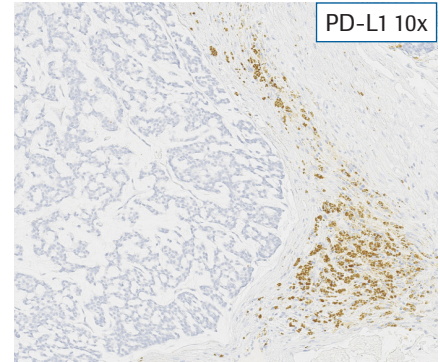
PD-L1 Expression < 1% IC



No Staining

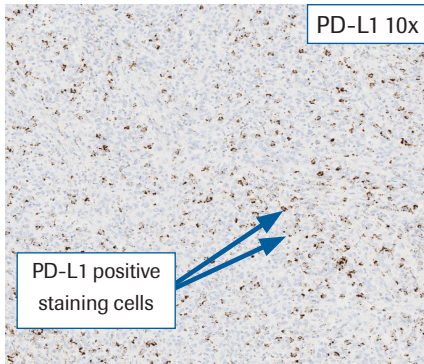


Light speckling and rare IC staining

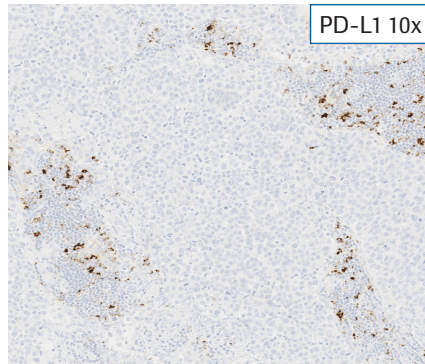


Hemosiderin pigment with no IC staining

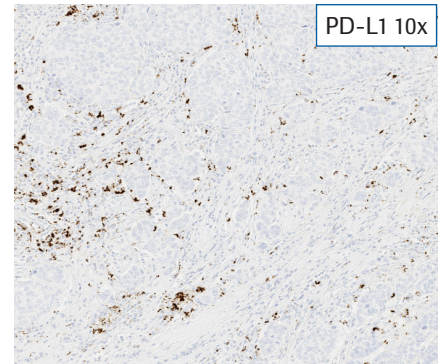
PD-L1 Expression ≥ 1% IC



Single-cell spread staining



Predominantly aggregate staining



Aggregate and single-cell spread staining

Scoring Method

VENTANA PD-L1 (SP142) Assay IC staining is scored as the proportion of tumor area covered with any discernible PD-L1 staining of any intensity in immune cells. Tumor-infiltrating immune cells include lymphocytes, macrophages, and cells with dendritic and reticular morphology. Tumor area is the area occupied by tumor cells as well as their associated intratumoral and contiguous peritumoral stroma (Figure 12). Given the fact the immune cells are present not only within the stroma but also are seen as single-cell or diffuse spread among the tumor cells, tumor area is chosen as the denominator.

Tumor Area: Area of tumor cells along with associated intratumoral and contiguous peritumoral stroma is illustrated in Figure 12.

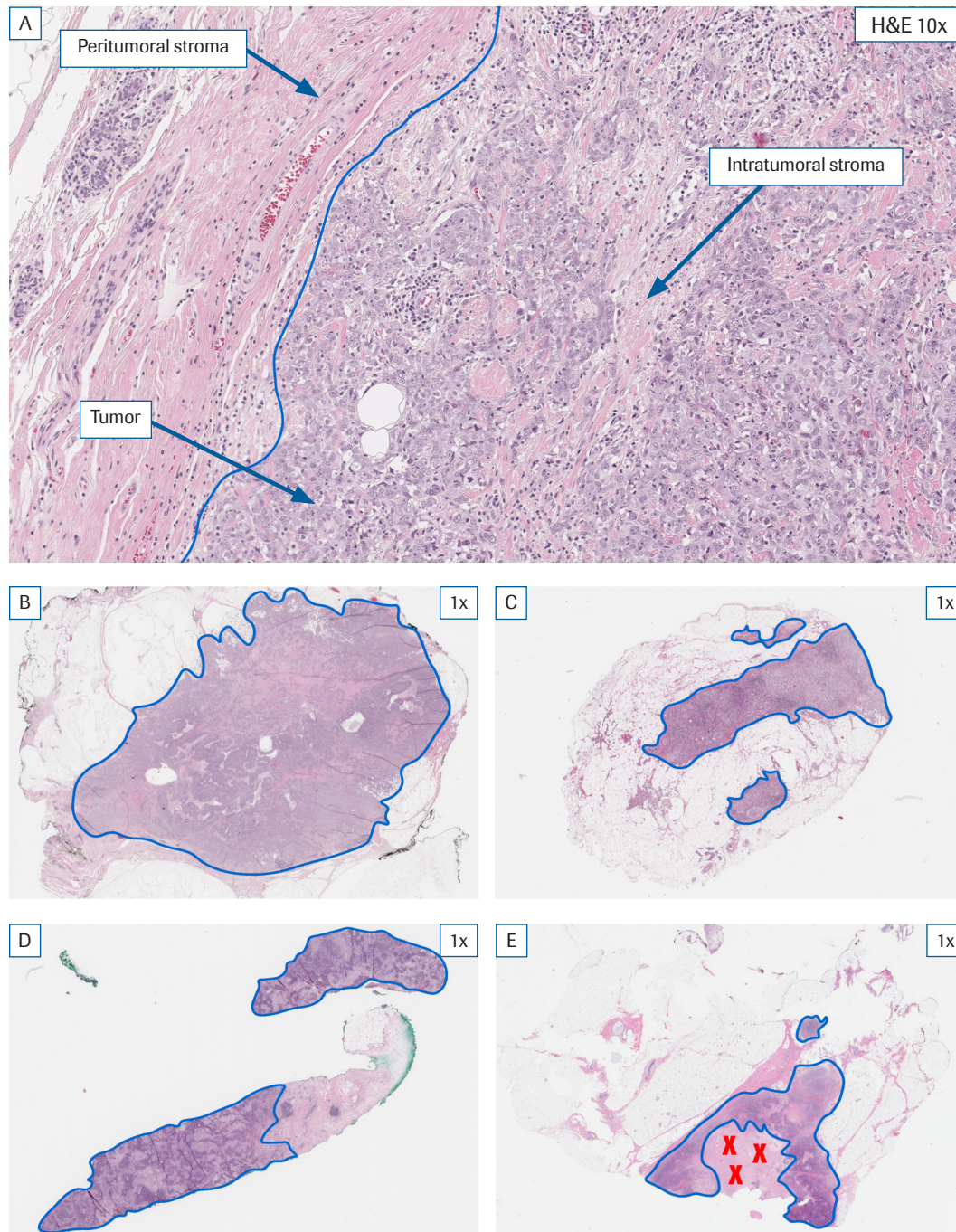
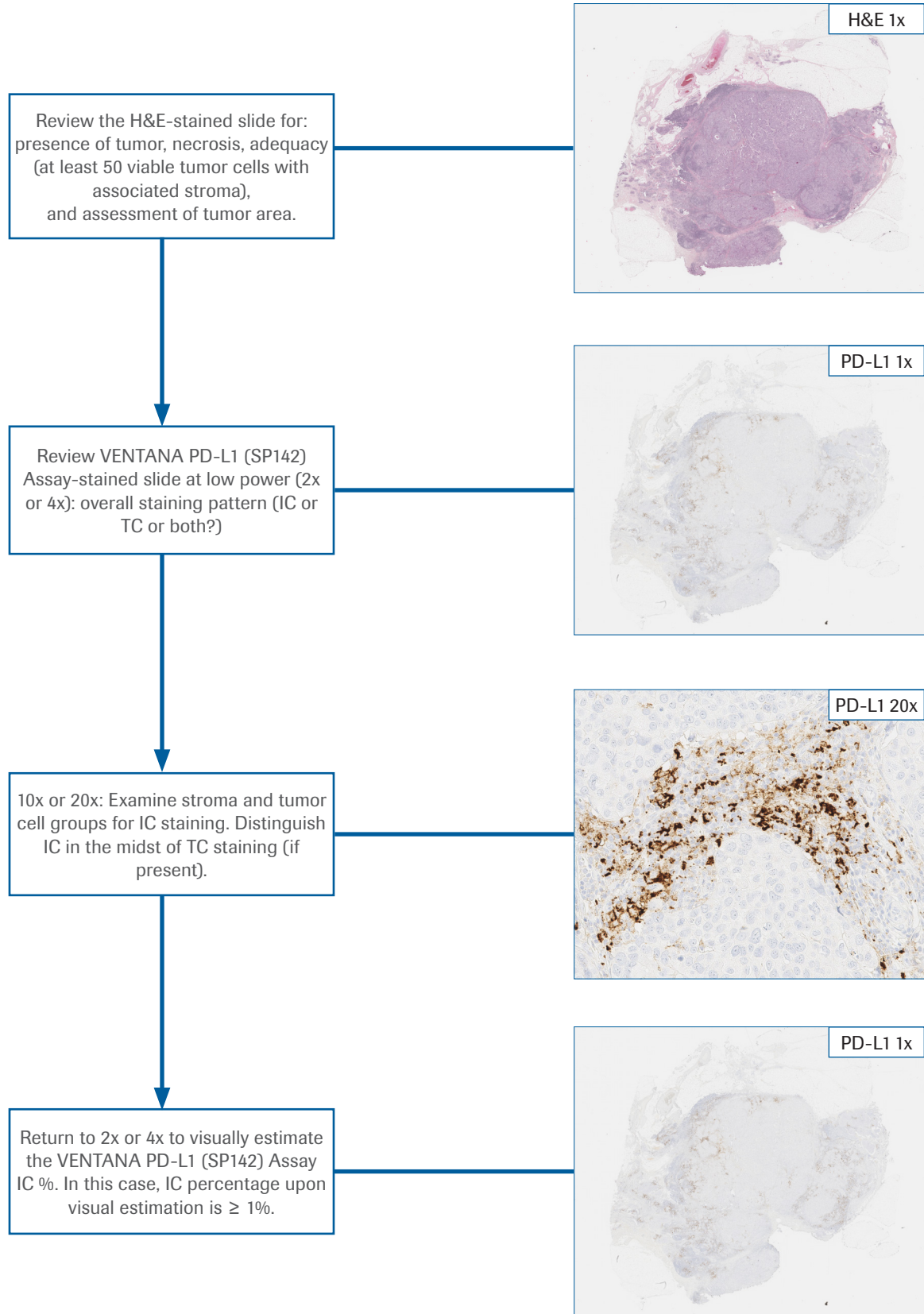


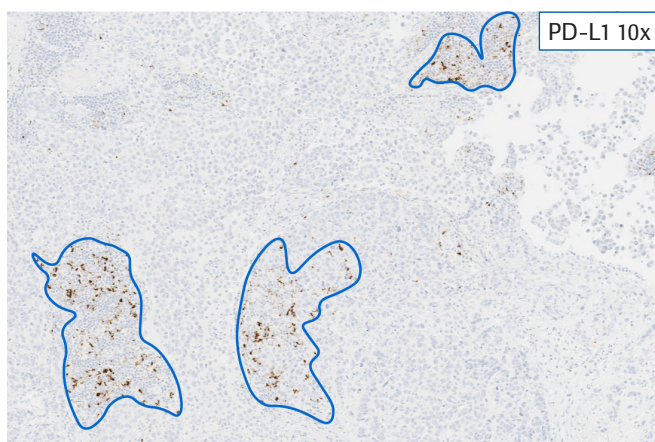
Figure 12: Encircled regions denote tumor area. A: High power image showing regions of stroma and tumor area; B: Tumor area in a resection specimen; C: Tumor area in multiple tumor nodules; D: Tumor area in a biopsy sample; E: Necrosis (marked by red “X”) is not included as part of the tumor area and should be excluded while scoring.

Estimation of VENTANA PD-L1 (SP142) Assay IC Percentage

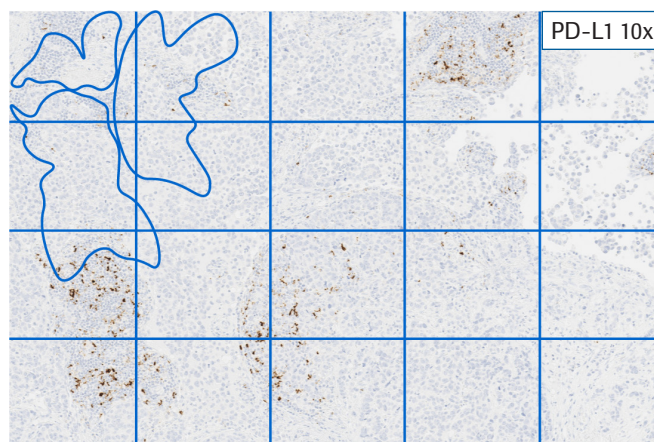


Scoring of PD-L1 IC aggregate staining

VENTANA PD-L1 (SP142) Assay IC percentage estimation is done at low power (2x or 4x) after reviewing the entire tumor area at high power. Visually assess the area of VENTANA PD-L1 (SP142) Assay positive IC and estimate their percentage as of the total tumor area. Reference images for a range of IC staining percentages are provided in the Reference Images section of this guide.



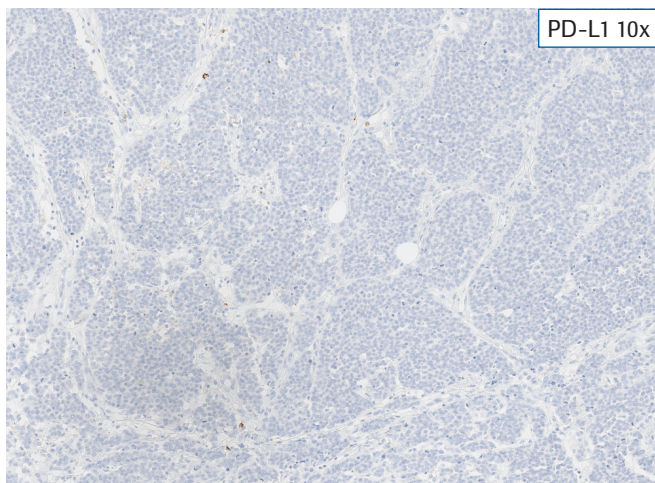
Visually encircle the IC aggregates as closely as possible



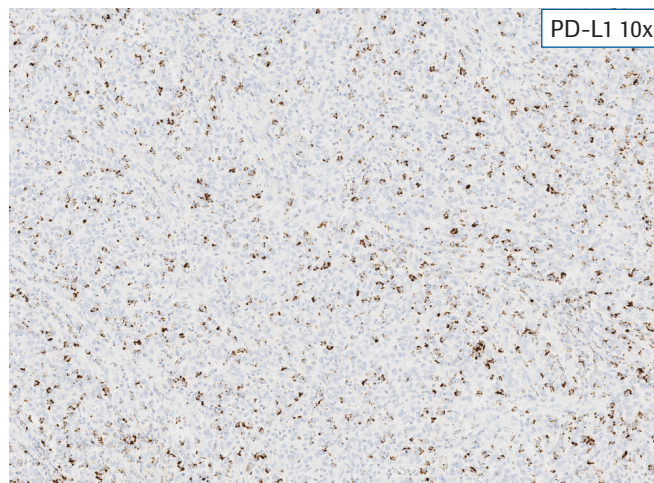
Combine these regions and estimate their combined area in the total tumor area. IC % is $\geq 1\%$

Scoring of PD-L1 IC single-cell spread staining

Single-cell spread IC is scored based on the density of single-cell spread, using the Reference Images section of this guide.



Cell density for single-cell spread IC is $< 1\%$



Cell density for single-cell spread IC is $\geq 1\%$

Controls

Tissue controls will be used only for monitoring the correct performance of processed tissues, test reagents and instruments, not as an aid in formulating a specific score for patient samples. One tissue control for each set of test conditions is recommended in each staining run.

Human benign tonsil is an ideal tissue control as it contains both positive and negative staining elements and can serve as a both a positive and negative tissue control for VENTANA PD-L1 (SP142) Assay. Tonsil tissue stained with VENTANA PD-L1 (SP142) Assay demonstrates staining of lymphocytes and macrophages in germinal centers, with scattered PD-L1 staining IC among PD-L1-negative cells in interfollicular regions. Also, diffuse staining is observed in reticulated crypt epithelial cells with an absence of staining of superficial squamous epithelial cells.

A positive control tissue should be a specimen fixed in 10% NBF and processed in the same manner as the patient specimens and should be run for each set of test conditions with every VENTANA PD-L1 (SP142) Assay performed. This tissue may be used to monitor all steps of specimen processing and staining. A tissue section fixed or processed differently from the test specimen can be used as a control for reagents and staining, but not for fixation or tissue preparation. Positive staining of lymphocytes

and macrophages in germinal centers, with diffuse staining observed in the reticulated crypt epithelial cells and absence of staining in the superficial squamous epithelial cells of the human benign tonsil tissue specimen confirms that VENTANA PD-L1 (SP142) Assay was applied and the instrument functioned properly. The positive tissue control should only be used to monitor performance, and it should not be used to aid the clinical diagnosis of patient samples.

Qualification and acceptability criteria for tonsil tissue control:

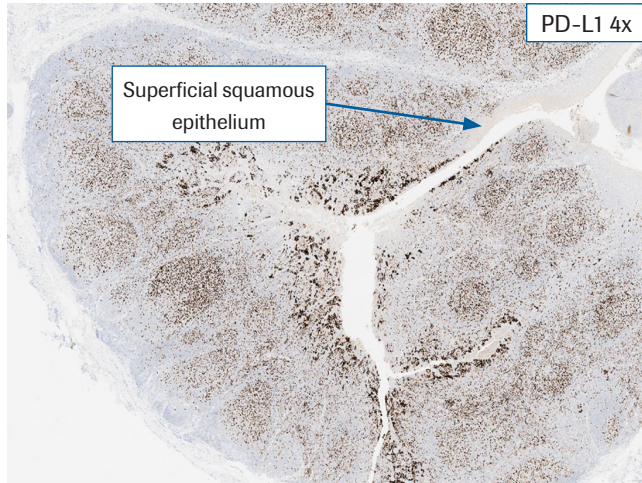
1. The reticulated crypt epithelial cells must show diffuse staining at moderate or strong intensity with no staining of the superficial squamous epithelial cells.
2. Lymphocytes and macrophages in the germinal centers must stain at moderate to strong intensity with scattered positive cells in the paracortical regions.
3. Background (i.e. non-specific staining) must be acceptable.

Human benign tonsil control tissue should show acceptable staining for an assay run to pass. The acceptance criteria for VENTANA PD-L1 (SP142) Assay staining in human benign tonsil tissue are provided below in Table 3.

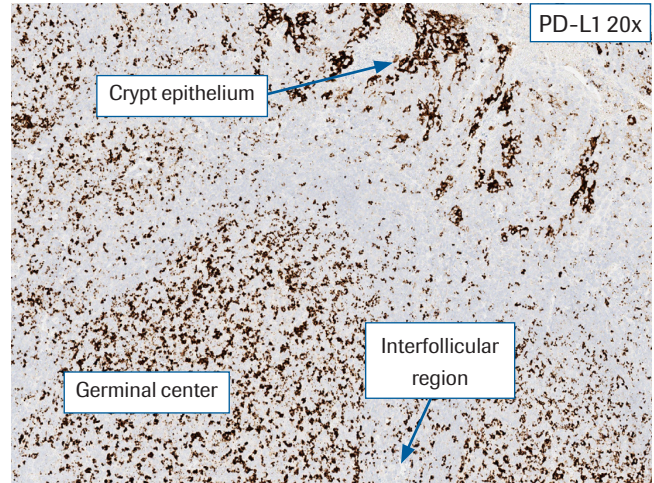
Table 3: Acceptance Criteria for VENTANA PD-L1 (SP142) Assay Staining in Human Benign Tonsil Tissue

Acceptable	Unacceptable
Positive tissue elements: Moderate to strong PD-L1 staining noted in lymphocytes and macrophages in germinal centers, with diffuse staining in reticulated crypt epithelial cells.	Excessive non-specific background staining obscuring the identification of PD-L1 positive cells.
Negative tissue elements: PD-L1 negative immune cells in the interfollicular regions with negative superficial squamous epithelium.	Weak to no PD-L1 staining noted in lymphocytes and macrophages in germinal centers, and reticulated crypt epithelial cells.

Acceptable Staining of Control Human Benign Tonsil Tissue

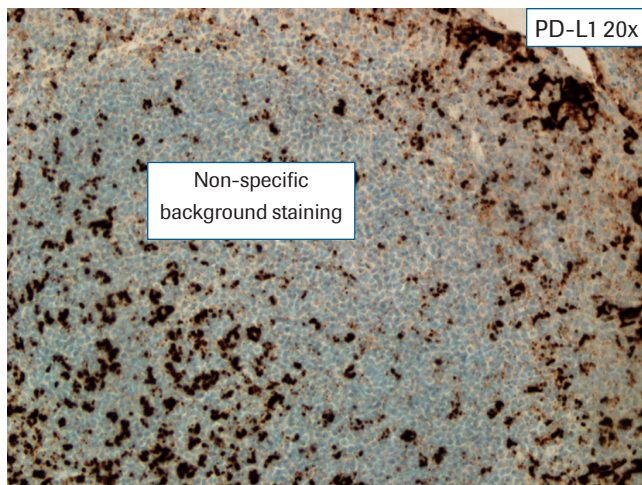


PD-L1 negative immune cells in the interfollicular regions with negative superficial squamous epithelium (Acceptable).

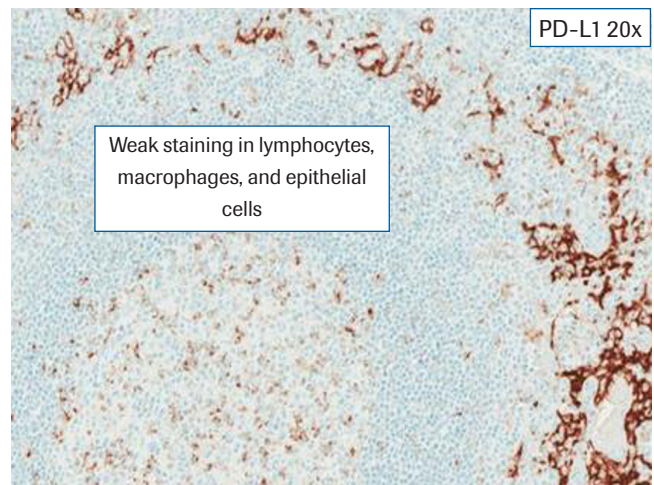


Moderate to strong PD-L1 staining noted in lymphocytes and macrophages in germinal centers, with diffuse staining in reticulated crypt epithelial cells (Acceptable).

Unacceptable Staining of Control Human Benign Tonsil Tissue



Excessive non-specific background staining obscuring the identification of PD-L1 positive cells (Unacceptable).



Weak to no PD-L1 staining noted in lymphocytes and macrophages in germinal centers, and reticulated crypt epithelial cells (Unacceptable).

Specimen Workflow

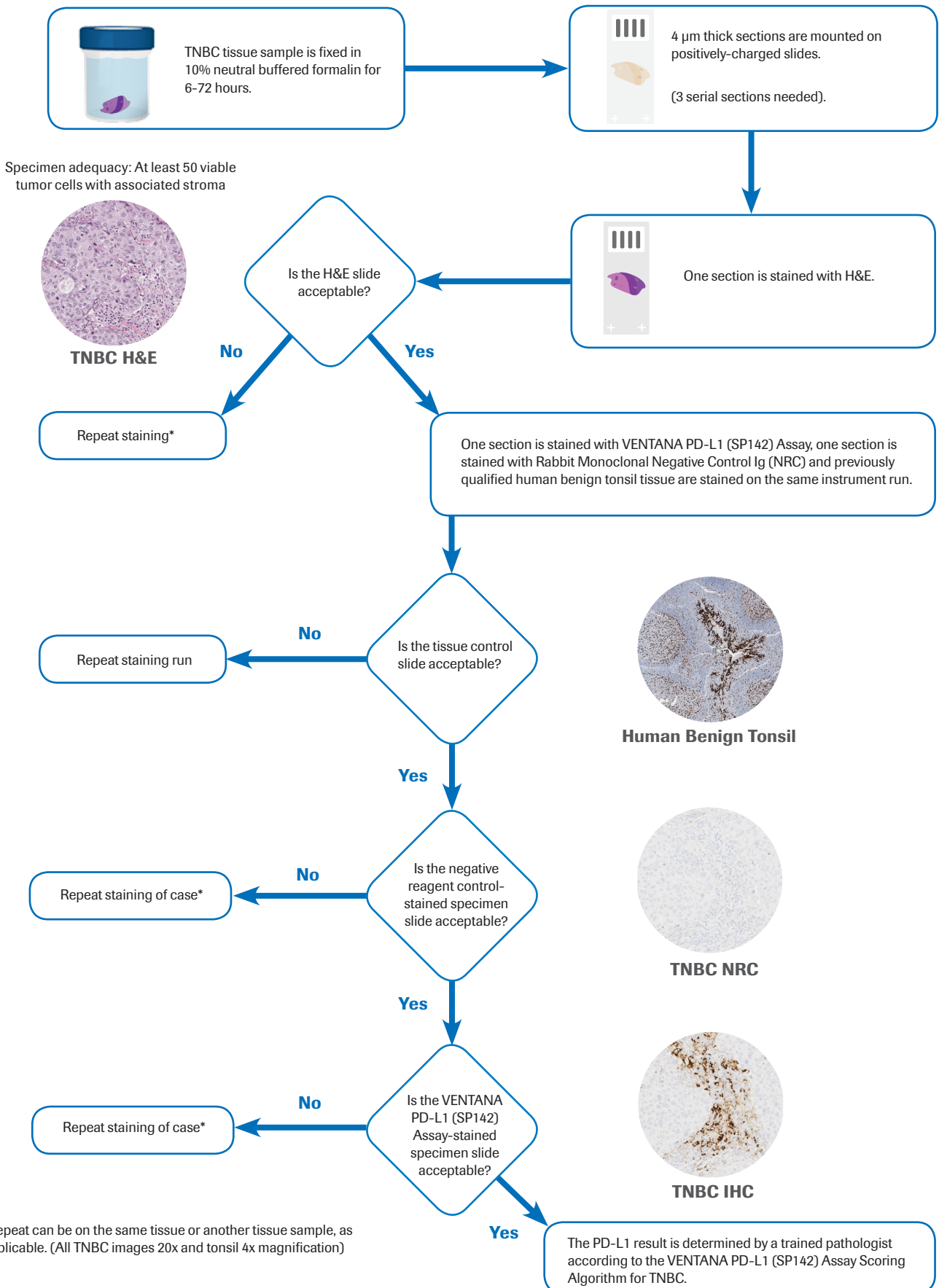
Staining requires three sections from each case, one serial tissue section for hematoxylin and eosin (H&E) staining, a second serial tissue section for Rabbit Monoclonal Negative Control Ig staining, and a third serial tissue section for VENTANA PD-L1 (SP142) Assay staining. If the H&E evaluation indicates that the patient specimen is inadequate, then a new specimen should be obtained and stained with VENTANA PD-L1 (SP142) Assay.

Pre-qualified human benign tonsil tissue exhibiting both positive and negative elements must be stained appropriately as defined by the acceptance criteria for human benign tonsil tissue (Table 3) on each run for the run to be considered valid.

A matched NRC slide must be run for every specimen to evaluate nonspecific staining and aid in the interpretation of results.

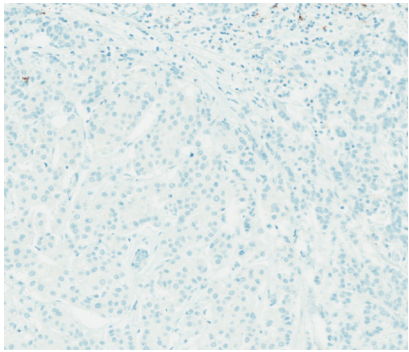
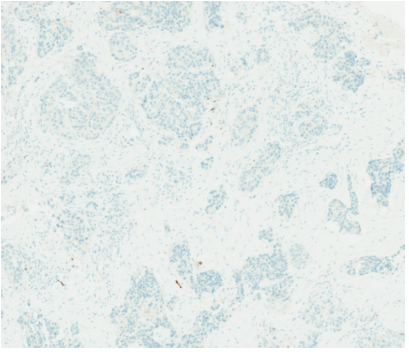
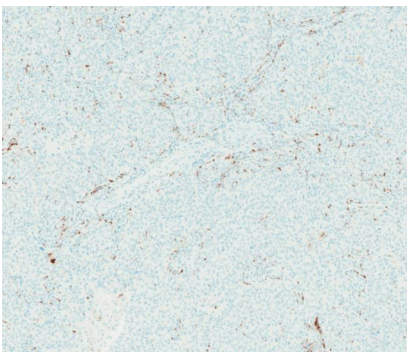
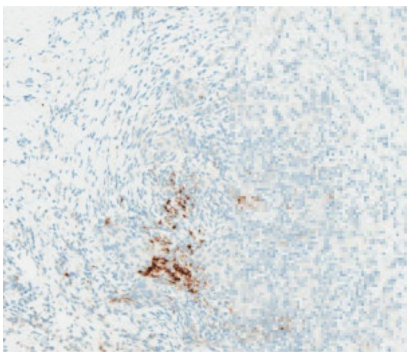
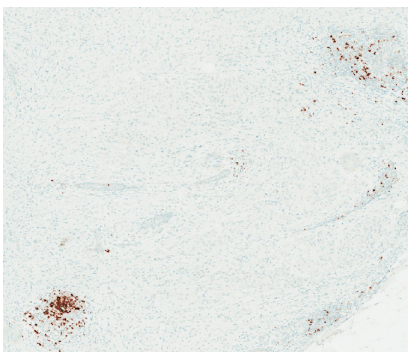
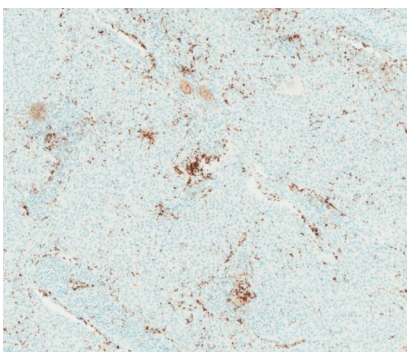
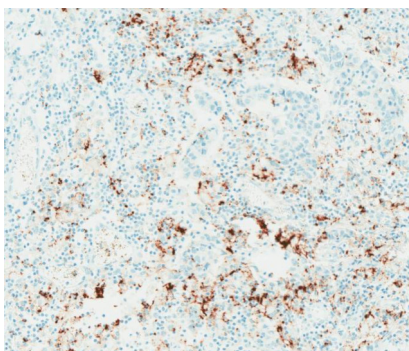
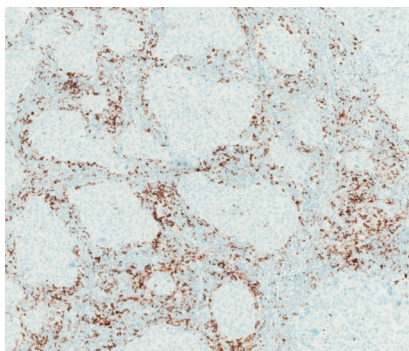
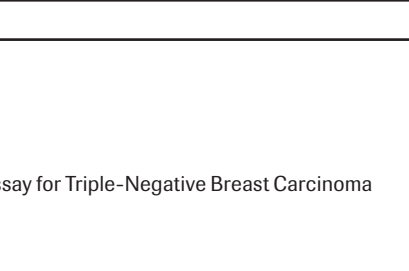

The PD-L1-stained specimen slides should be assessed by a trained pathologist. If either the PD-L1-stained tissue control slide or the NRC-stained specimen slide is not acceptable, staining of patient samples should be repeated. Repeat may be on the same tissue or another tissue sample, as applicable. A non-evaluable VENTANA PD-L1 (SP142) Assay-stained slide would mean that determination of reactivity is not possible due to necrosis, absent tissue, or artifacts.

Specimen Flow

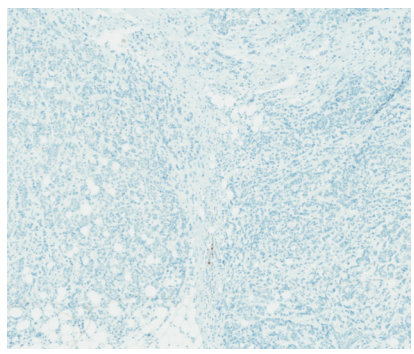
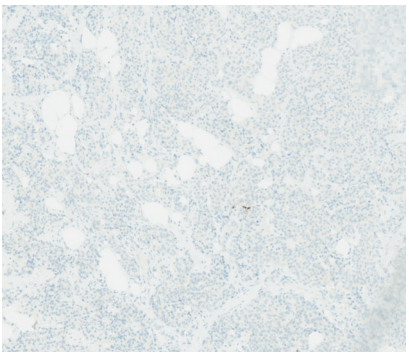
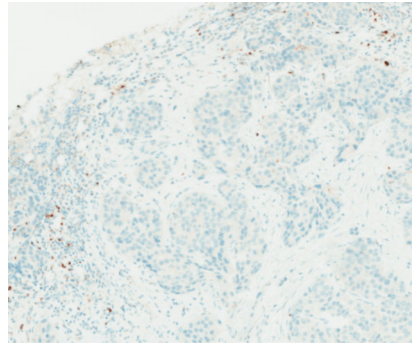
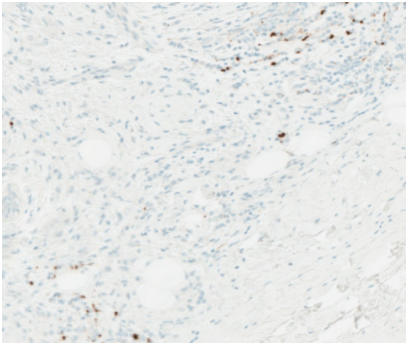
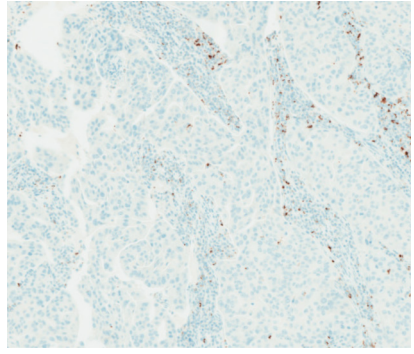
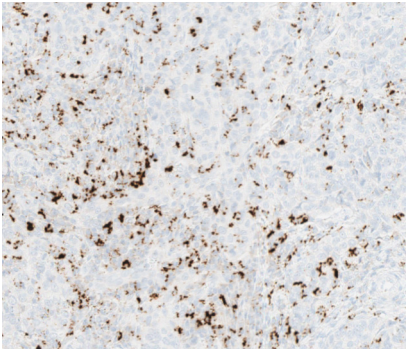
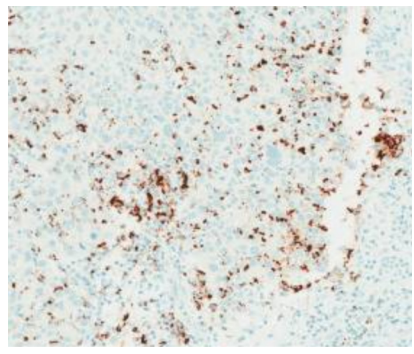
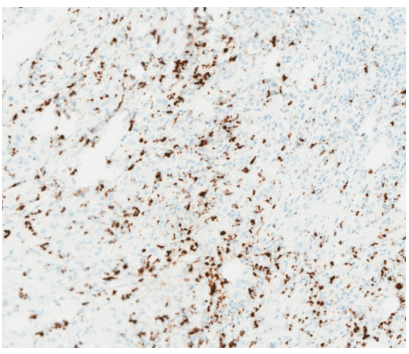




Reference Images

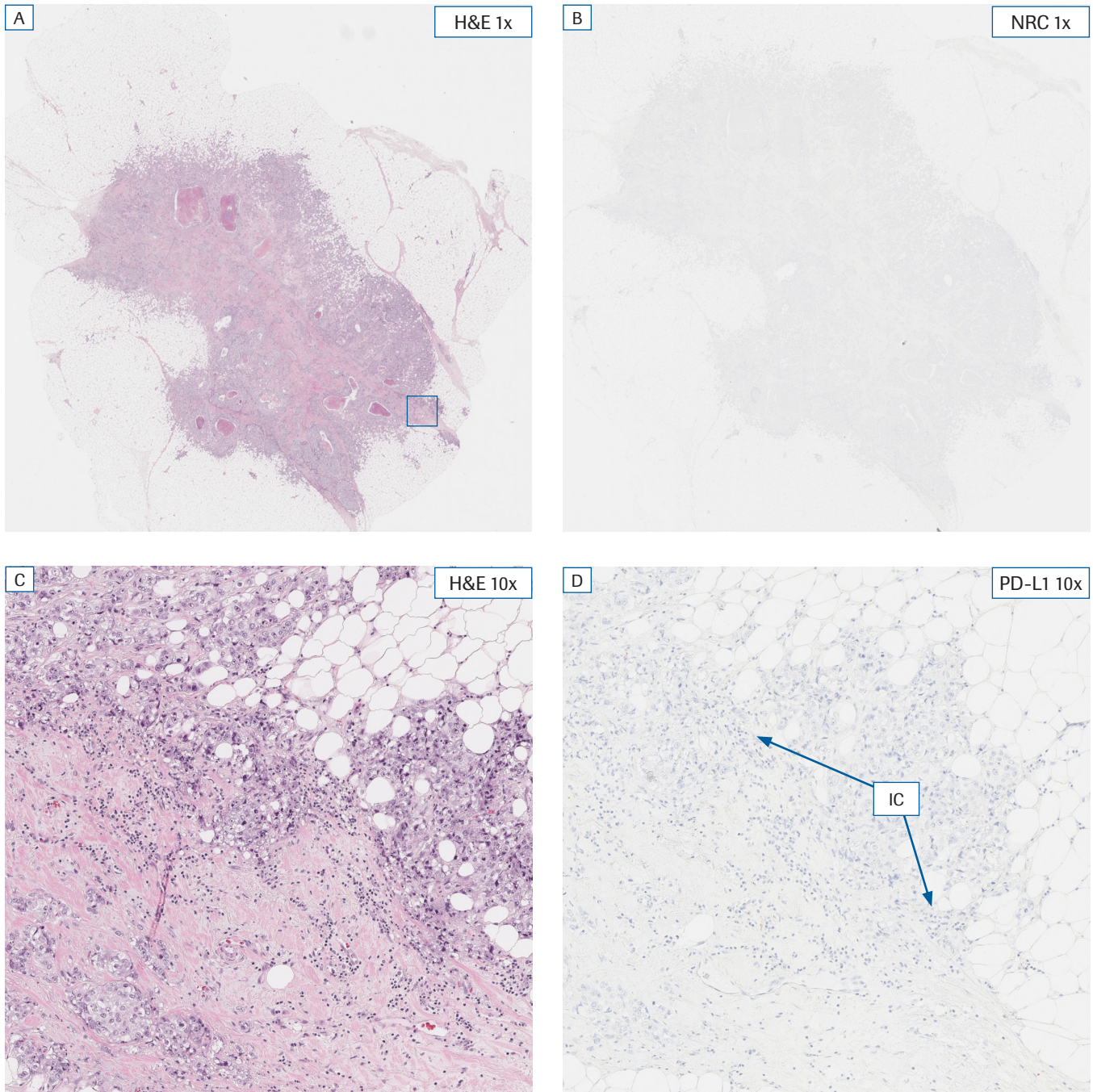
VENTANA PD-L1 (SP142) Assay: IC Aggregates Scoring

IC Aggregates		
IC < 1%		
		
IC ≥ 1%		
		
		
(all images 10x magnification)		

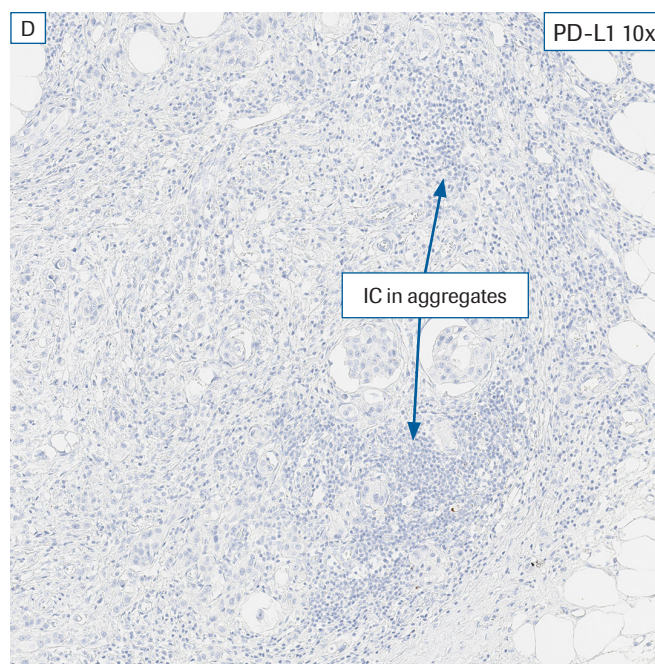
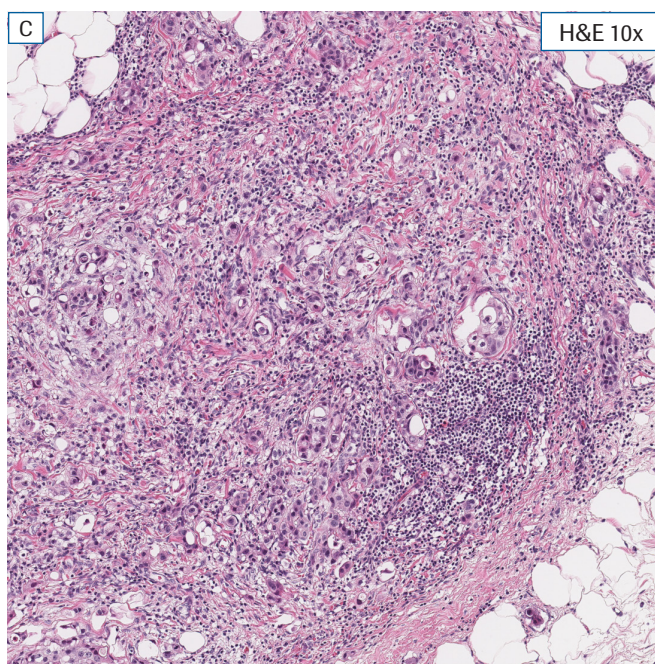
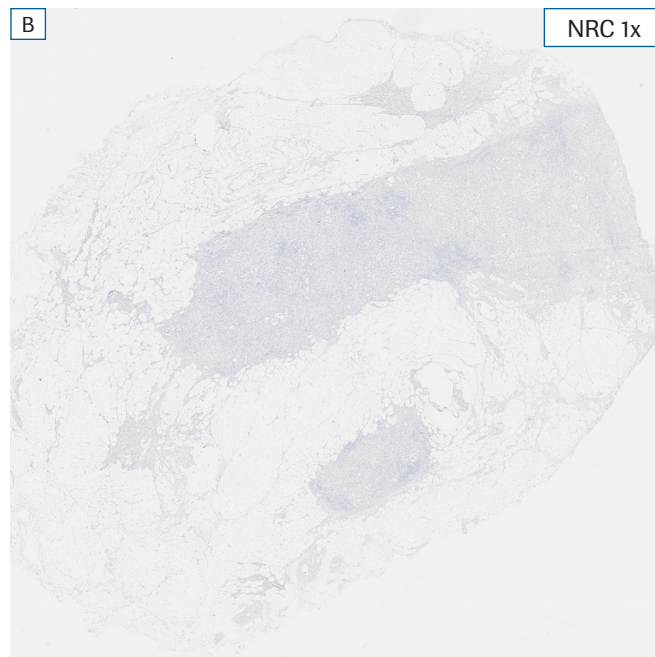
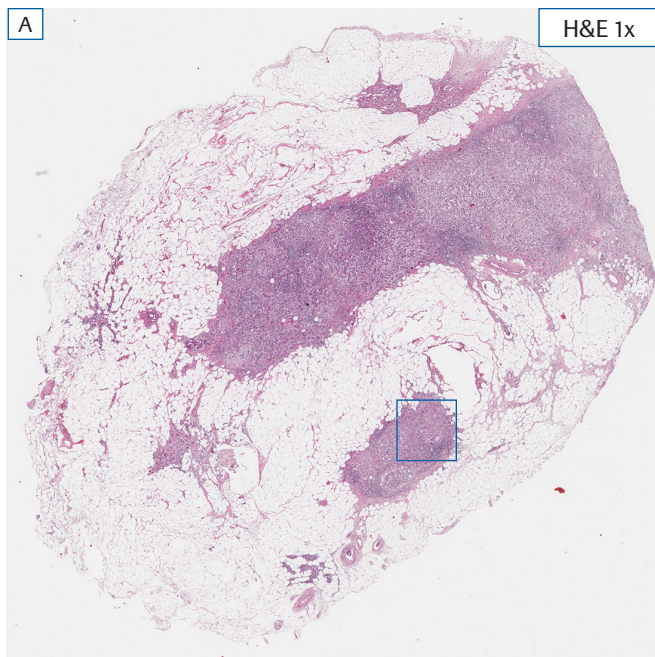
VENTANA PD-L1 (SP142) Assay: IC Single-Cell Spread Scoring

IC Single-Cell Spread		
IC < 1%		
IC ≥ 1%		
		
		
		
(all images 10x magnification)		

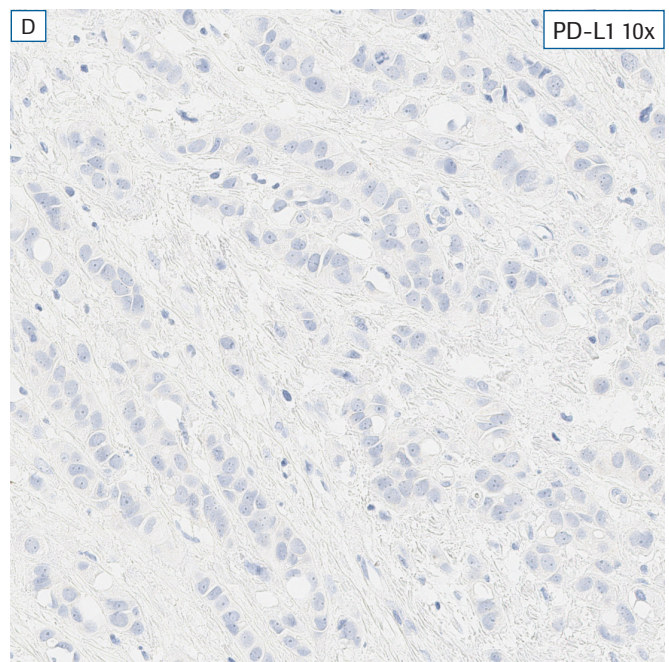
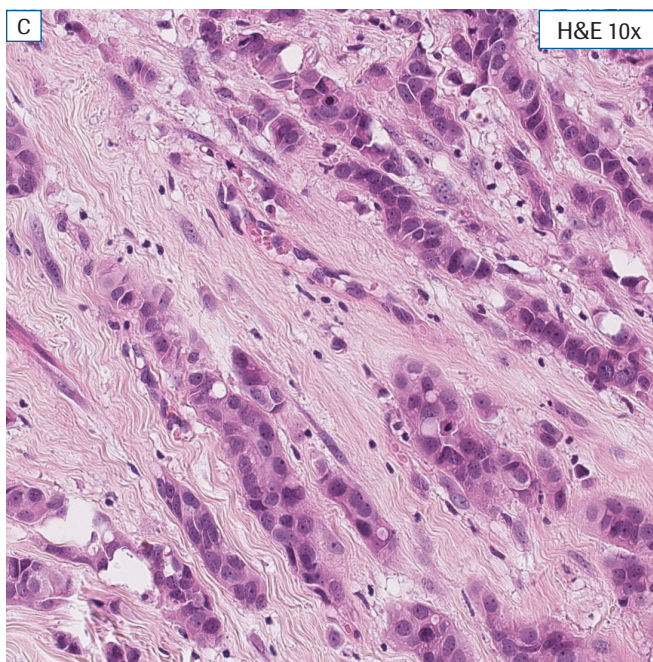

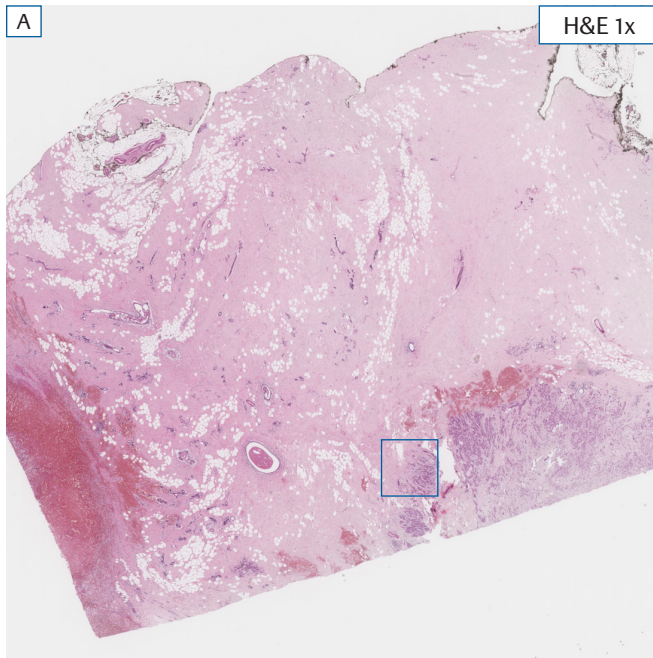
Example Cases: IC < 1% IC



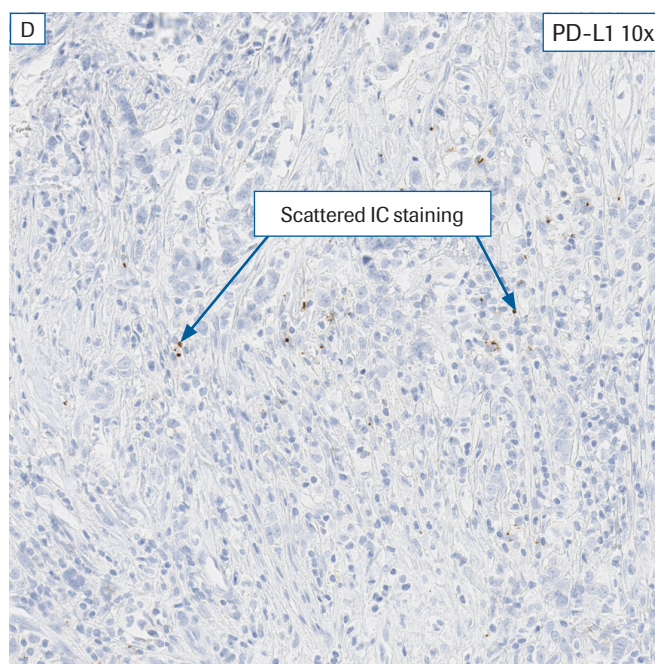
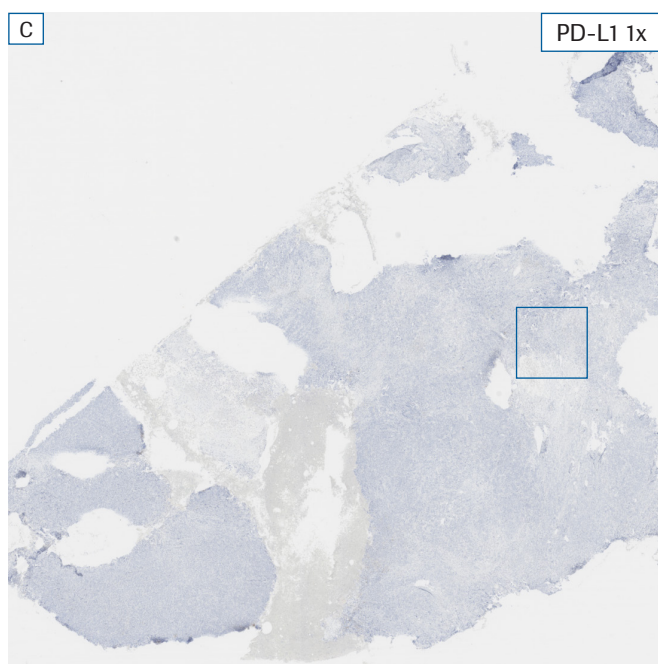
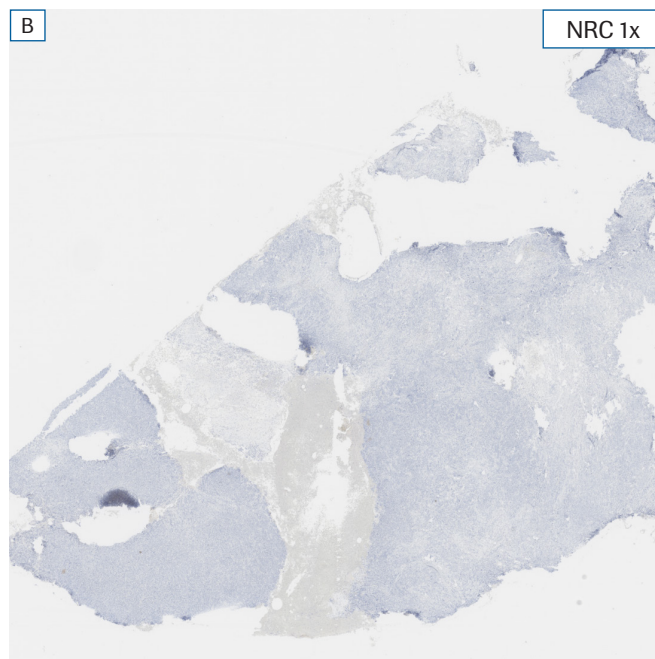
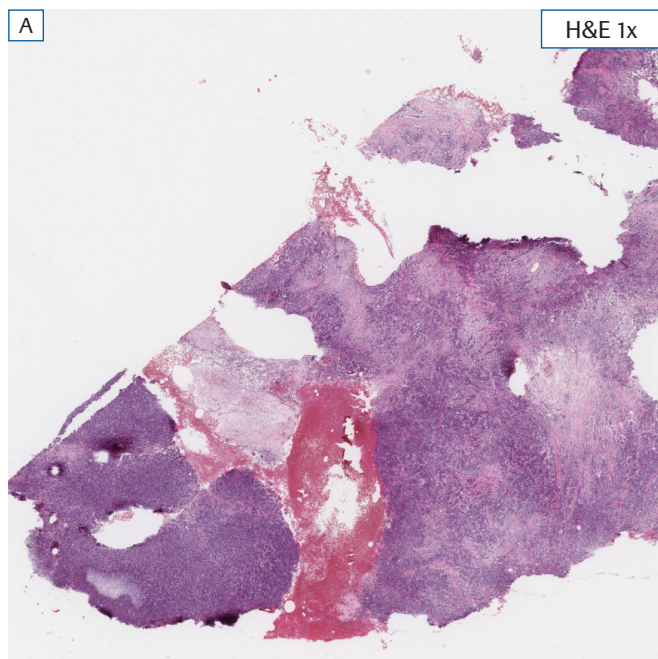
Case 1: IC: 0% - This case shows no PD-L1 staining. Boxed region in A is shown at higher magnification in C; the corresponding region on the PD-L1-stained slide is shown in D (image of the PD-L1-stained slide at lower magnification is not shown here). Here, IC are interspersed in the tumor area as single cells. This case is PD-L1 < 1% IC.



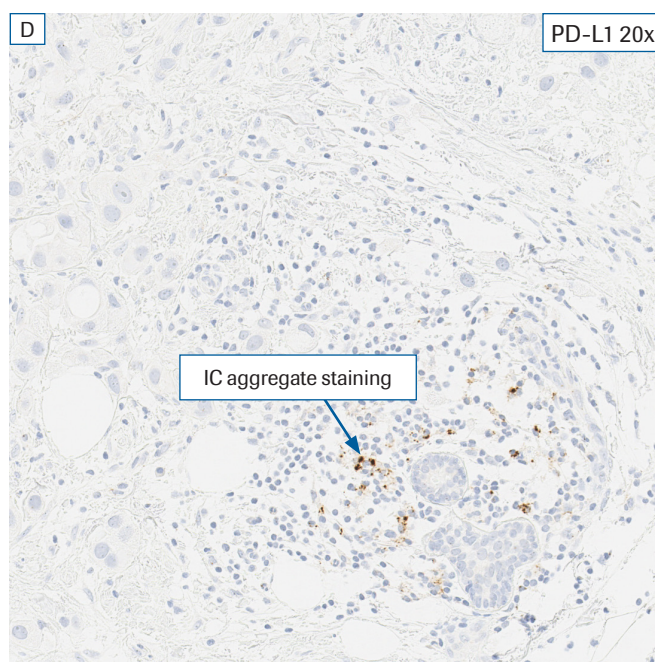
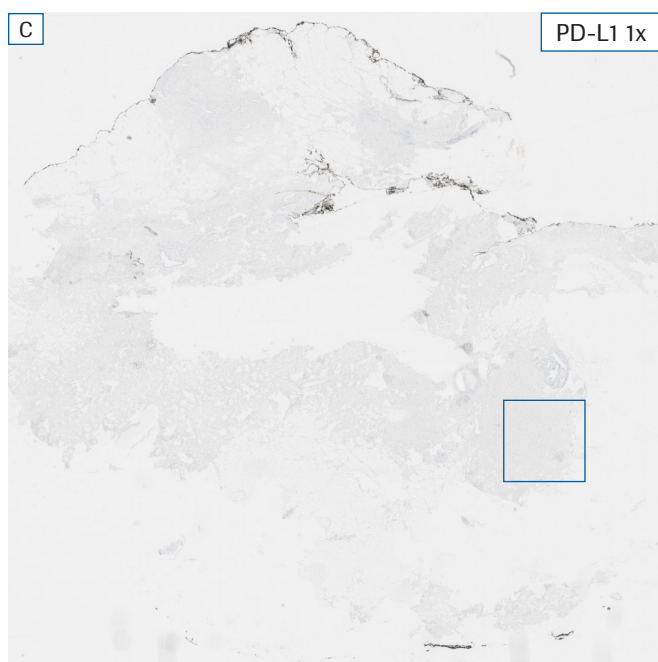

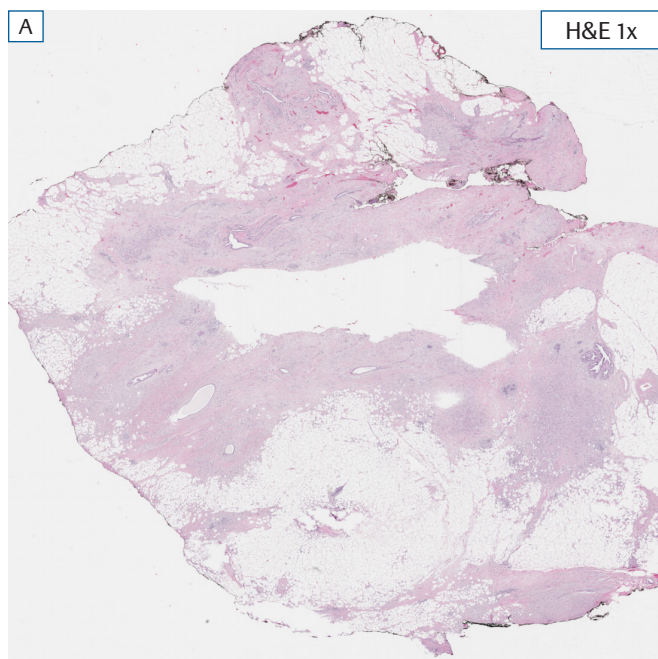
Case 2: IC: 0% - This case shows no PD-L1 staining. Boxed region in A is shown at higher magnification in C; the corresponding region on the PD-L1-stained slide is shown in D (image of the PD-L1-stained slide at lower magnification is not shown here). Here, IC are aggregated in the tumor area. This case is PD-L1 < 1% IC.



Case 3: IC: 0% - Boxed region in A is shown at higher magnification in C. Notice the paucity of IC in the tumor area (C). The corresponding region on the PD-L1-stained slide is shown in D (image of the PD-L1-stained slide at lower magnification is not shown here). This case is PD-L1 < 1% IC.

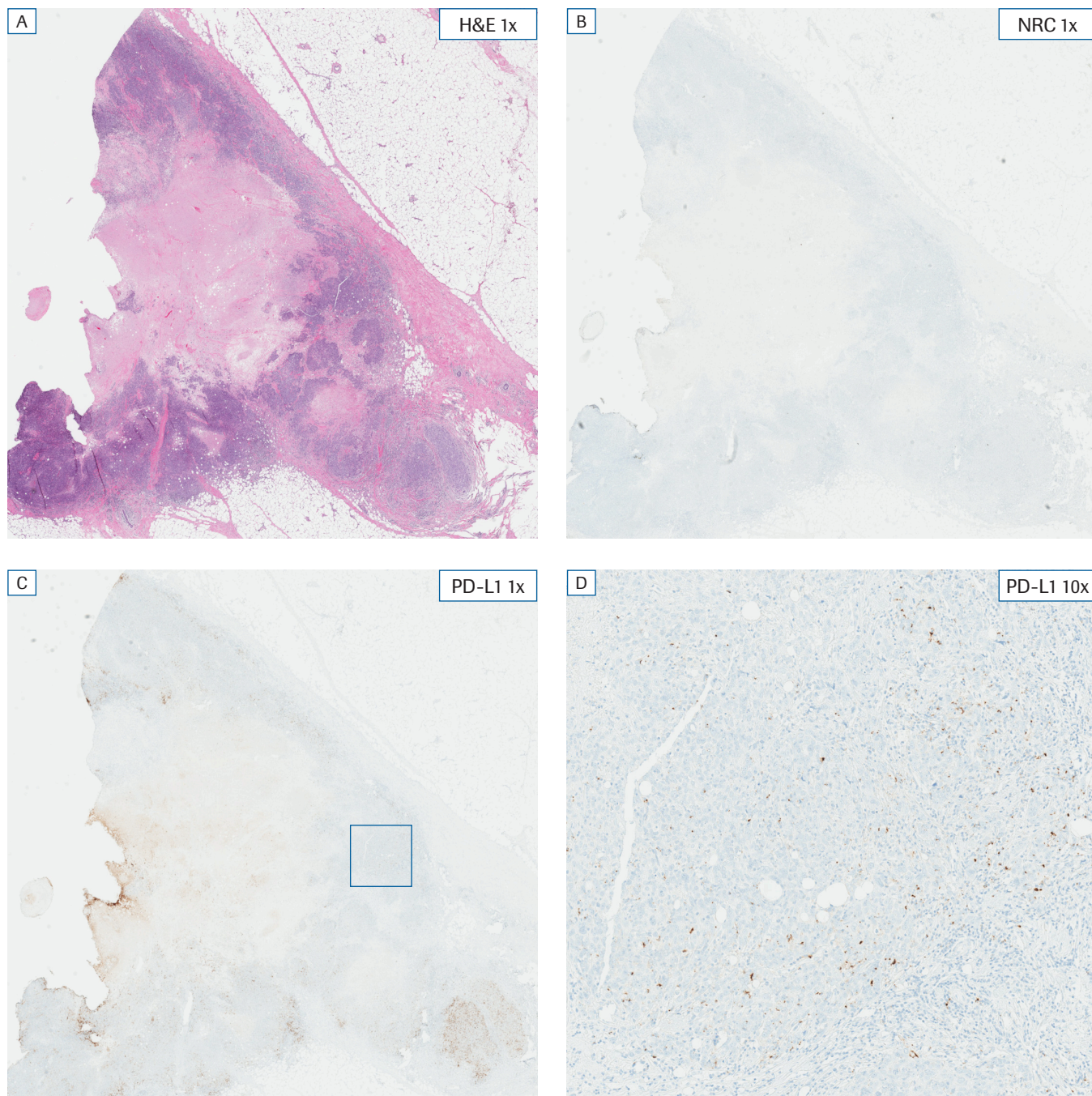


Case 4: IC: < 1% - This case shows scattered PD-L1 staining. Boxed region in C is shown at higher magnification in D. Here, IC are interspersed in the tumor area as single cells. This is the only region with PD-L1-positive IC staining. This case is PD-L1 < 1% IC.

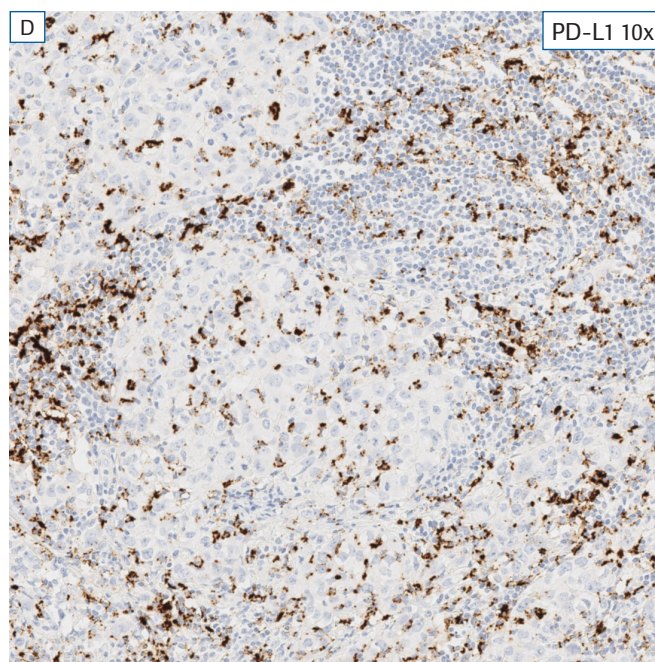
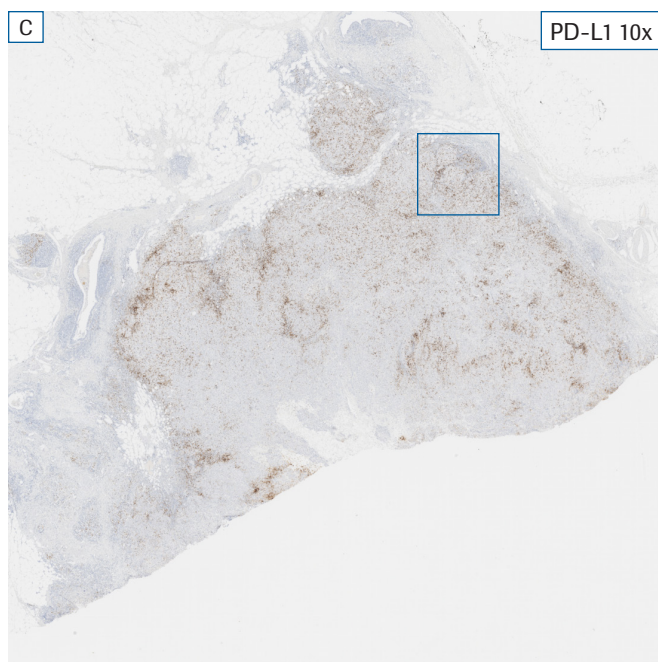
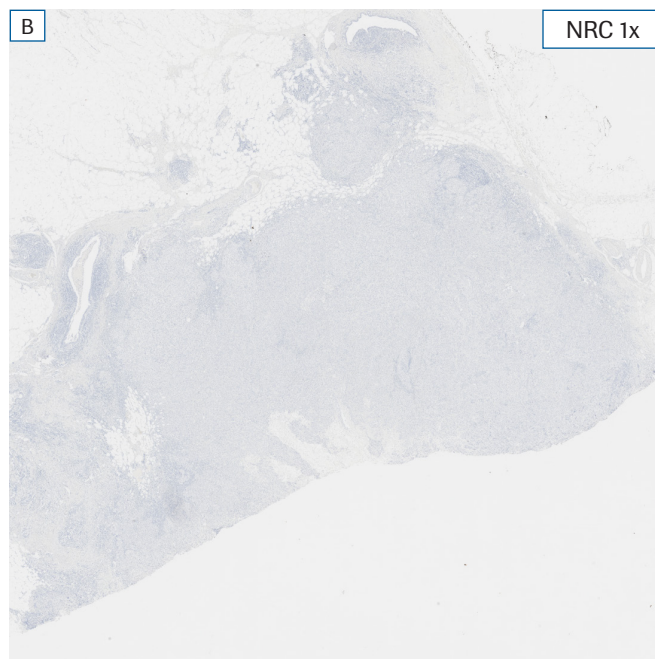
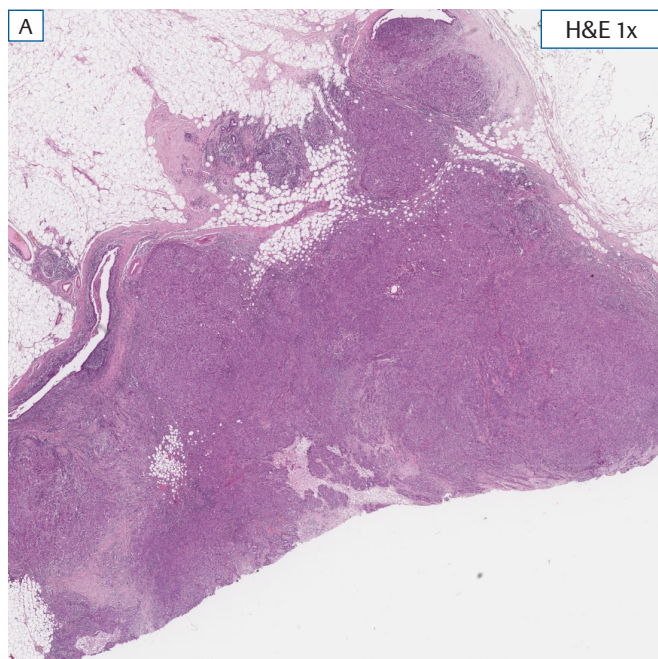


Case 5: IC: < 1% - Boxed region in C is shown at higher magnification in D. This case shows PD-L1 staining in aggregates of IC. This is the only region with PD-L1-positive IC staining. This case is PD-L1 < 1% IC.

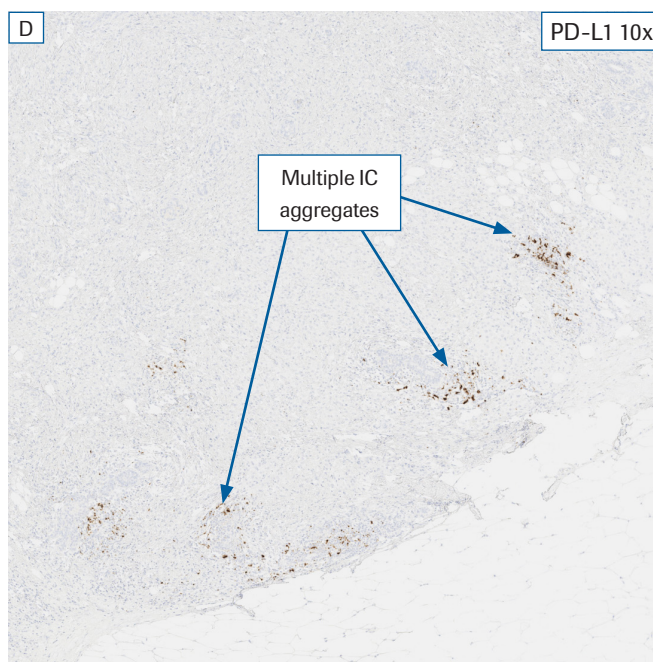
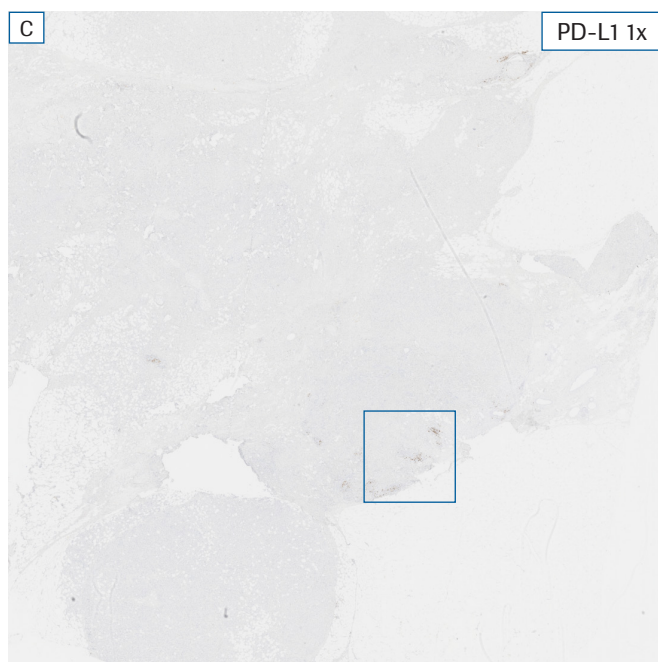
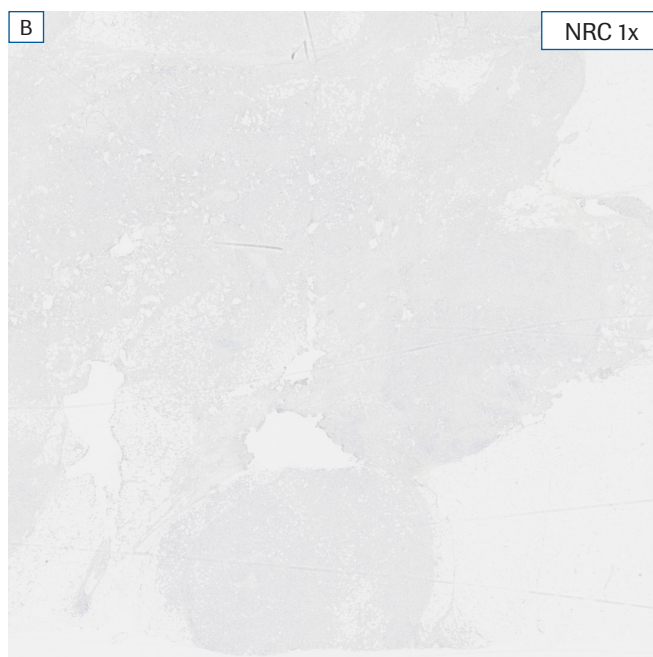
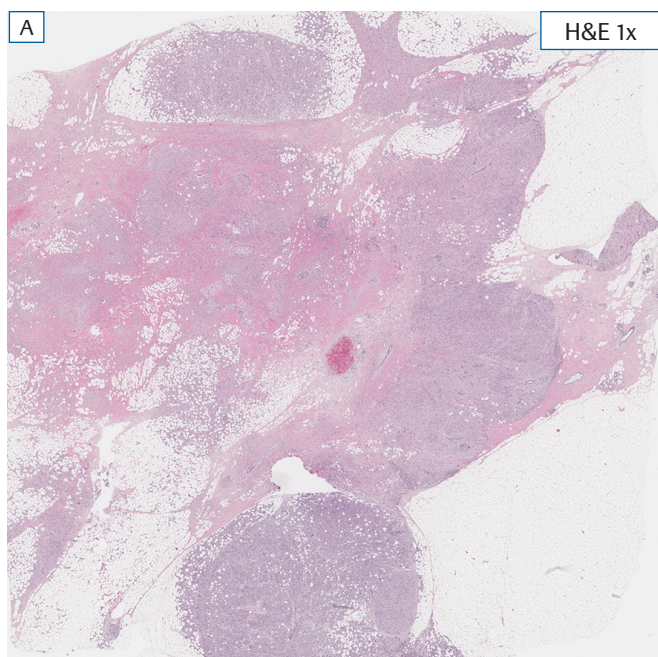
Example Cases: IC \geq 1% IC



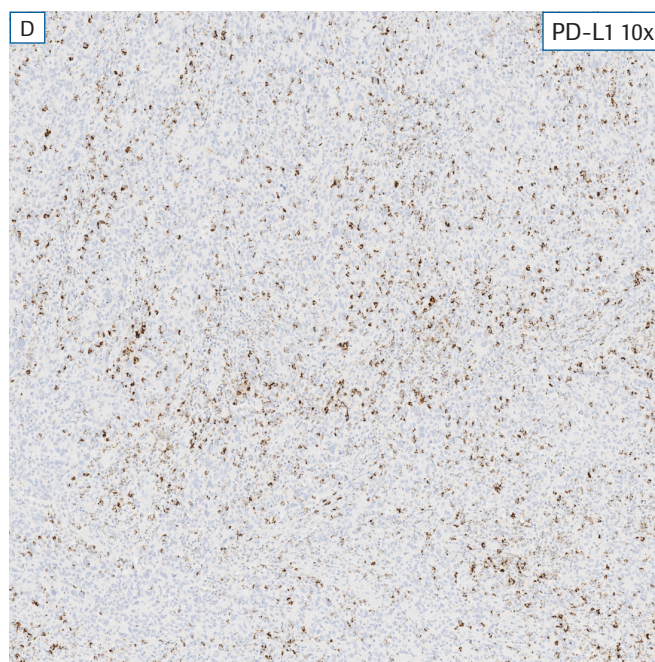

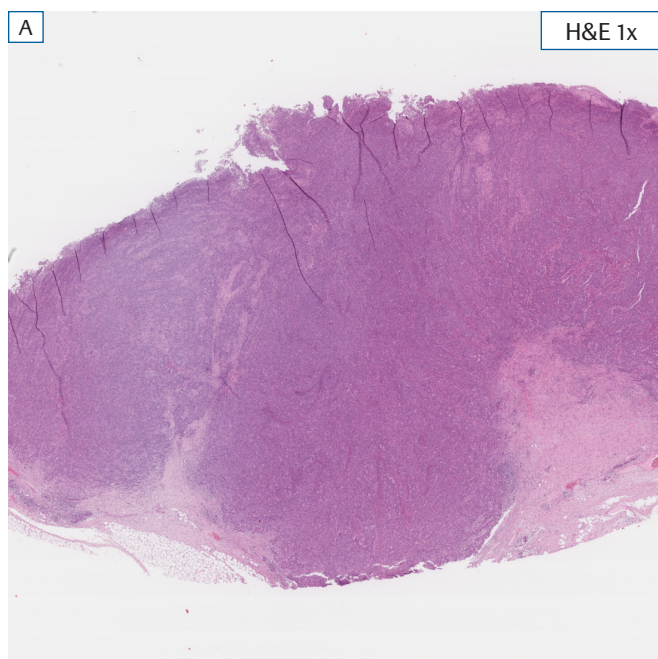
Case 6: IC: 2% – Boxed region in C is shown at higher magnification in D. This case shows scattered PD-L1 staining in a single-cell spread pattern. IC are interspersed in the tumor area. This case is PD-L1 \geq 1% IC.



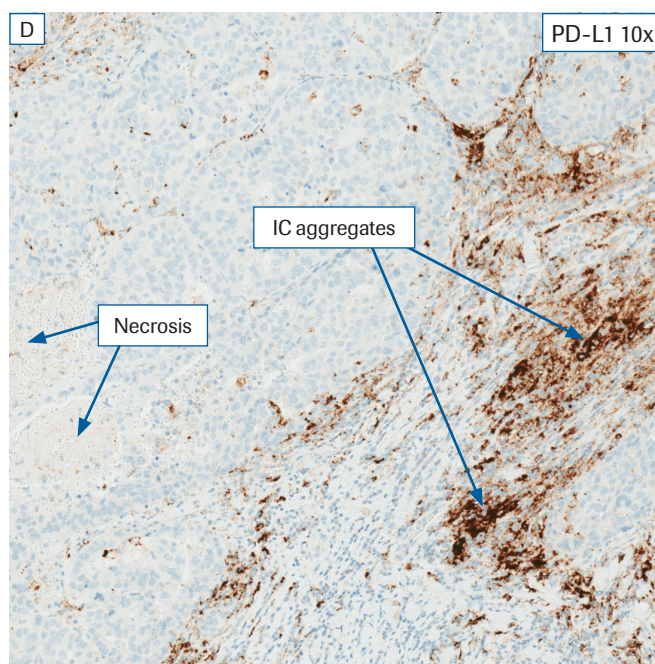
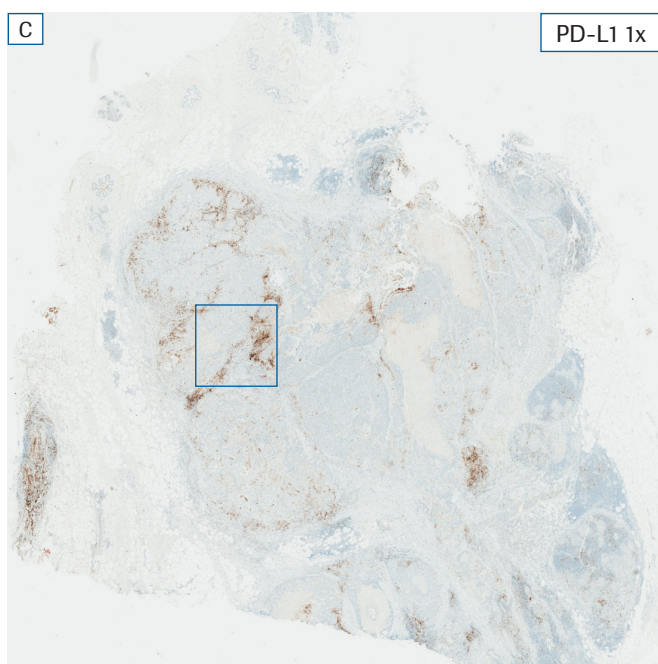

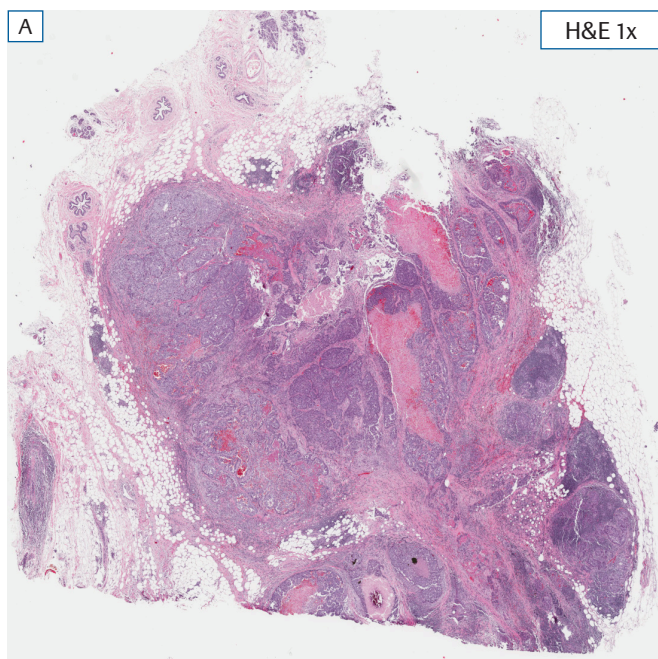
Case 7: IC: 25% - This case shows PD-L1 staining in an aggregate pattern. IC are scattered as small aggregates in the tumor area (C). Boxed region in C is shown at higher magnification in D. This case is PD-L1 \geq 1% IC.




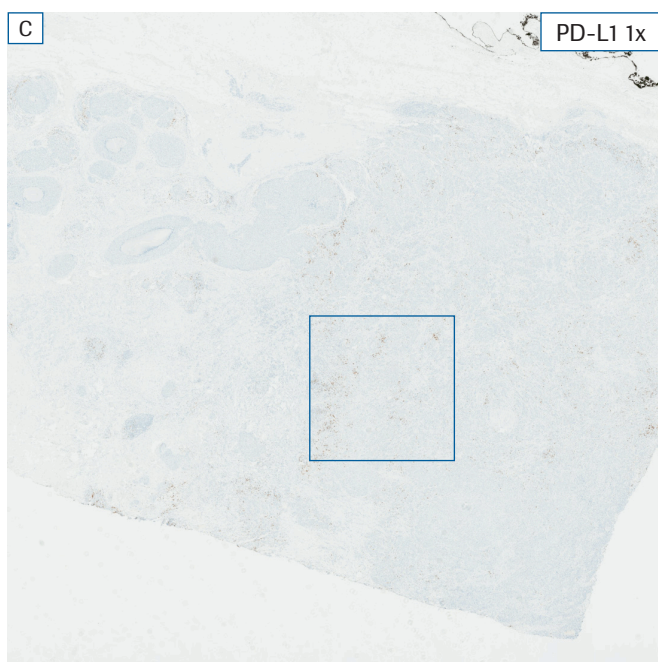

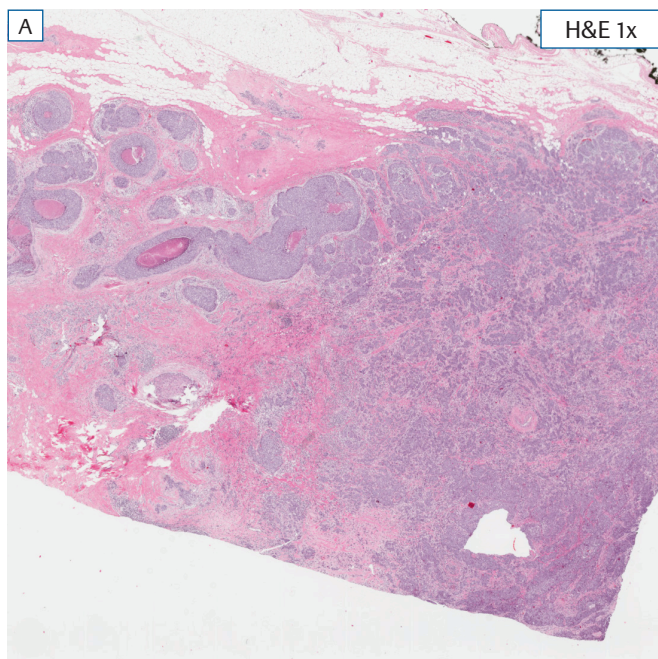
Case 8: IC: 2% - Boxed region in C is shown at higher magnification in D. Arrows point to IC aggregates. Due to the large tumor area, those aggregates and the few other aggregates present result in an overall 2% IC staining. This case is PD-L1 \geq 1% IC.



Case 9: IC: 15% - This case shows scattered PD-L1 staining in a single-cell spread pattern. Boxed region in C is shown at higher magnification in D. Here, IC are interspersed in the tumor area. This case is PD-L1 \geq 1% IC.



Case 10: IC: 5% - This case shows PD-L1 staining in aggregates. Boxed region in C is shown at higher magnification in D. Here, IC are scattered as big aggregates in the tumor area. Note the areas of necrosis that decrease the tumor area. This case is PD-L1 \geq 1% IC.



Case 11: IC: 5% - This case shows PD-L1 staining in IC scattered as both aggregates and single-cell spread which cover 5% of the tumor area. Boxed region in C is shown at higher magnification in D which is representative for the whole tumor area. This case is PD-L1 $\geq 1\%$ IC.

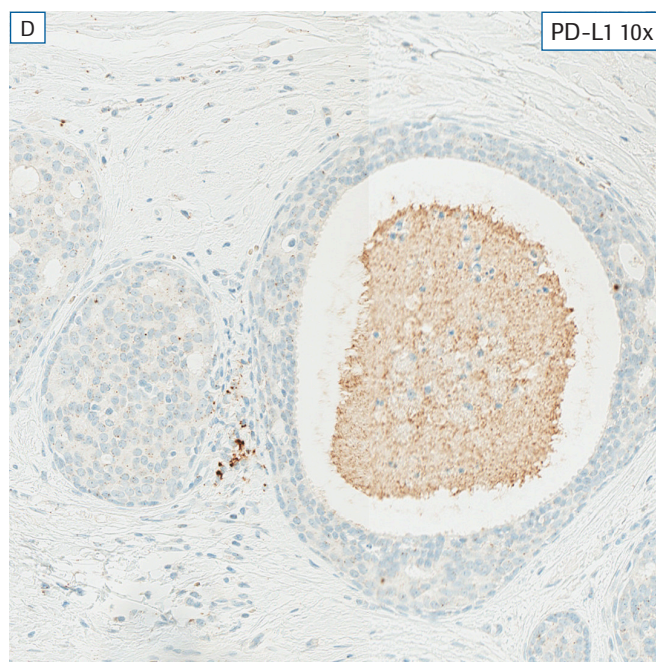
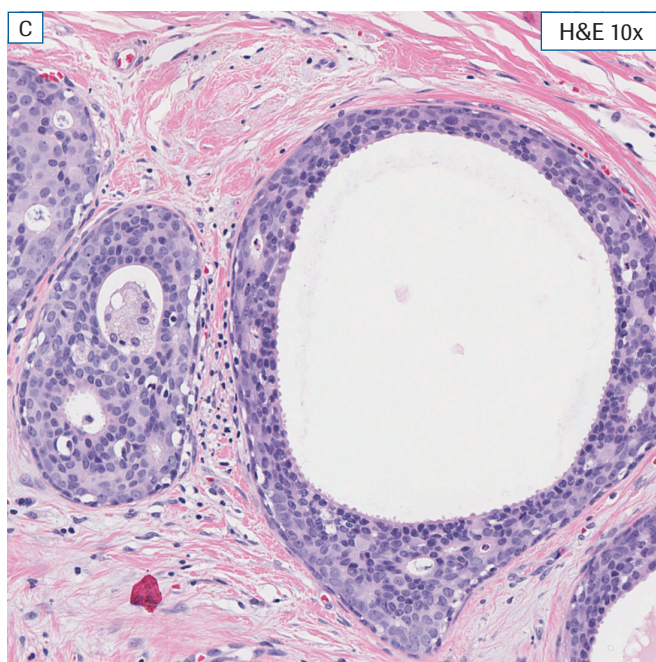
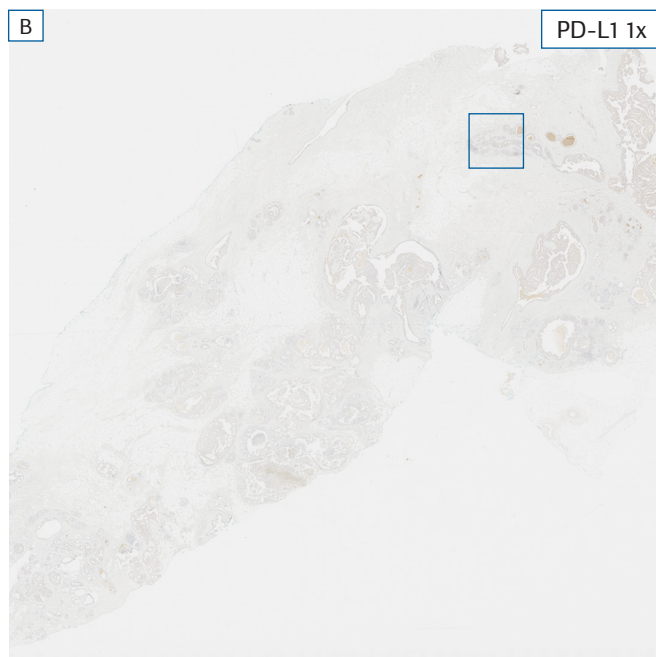
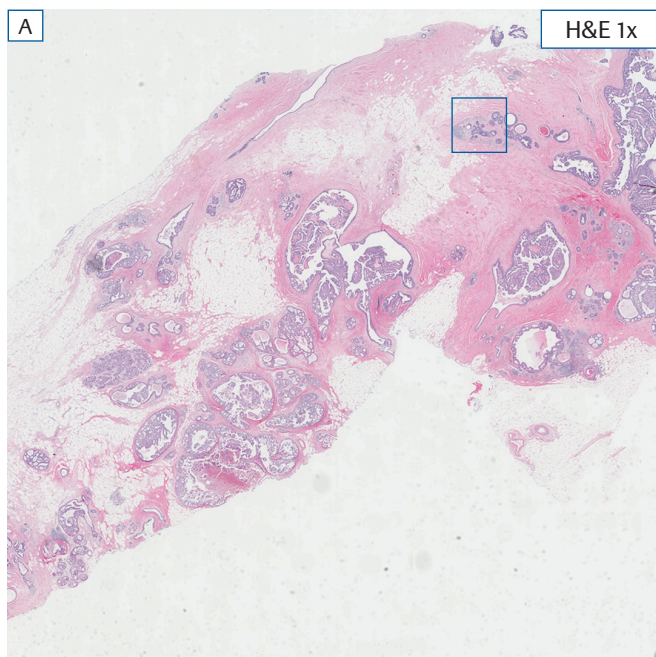
Challenging Cases

While the vast majority of cases stained with VENTANA PD-L1 (SP142) Assay are clearly $\geq 1\%$ IC or $< 1\%$ IC in their staining results, a few cases have been observed that present a challenge in interpretation.

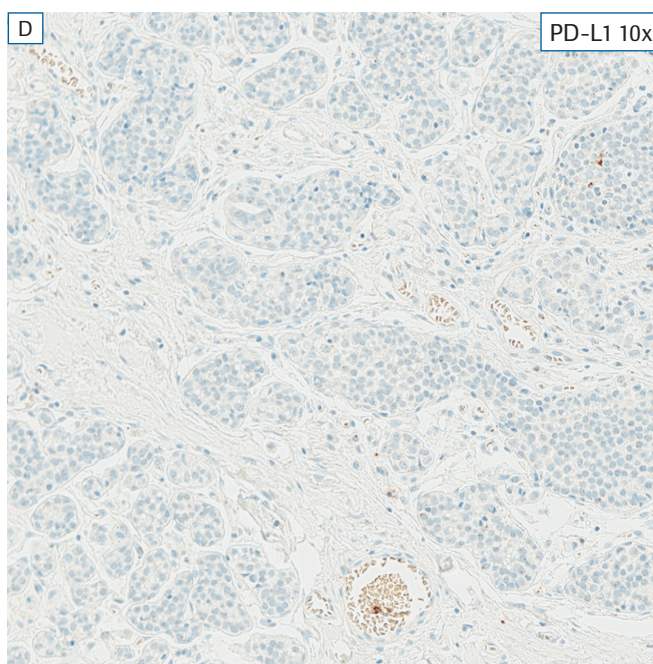
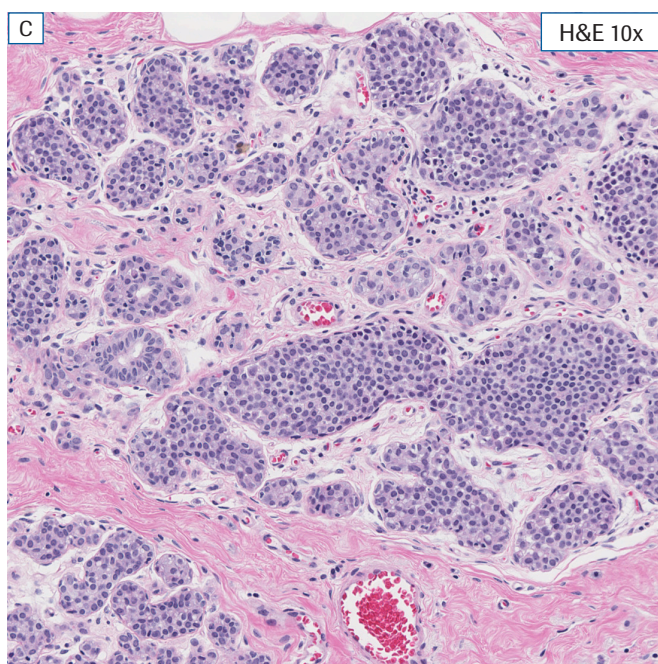
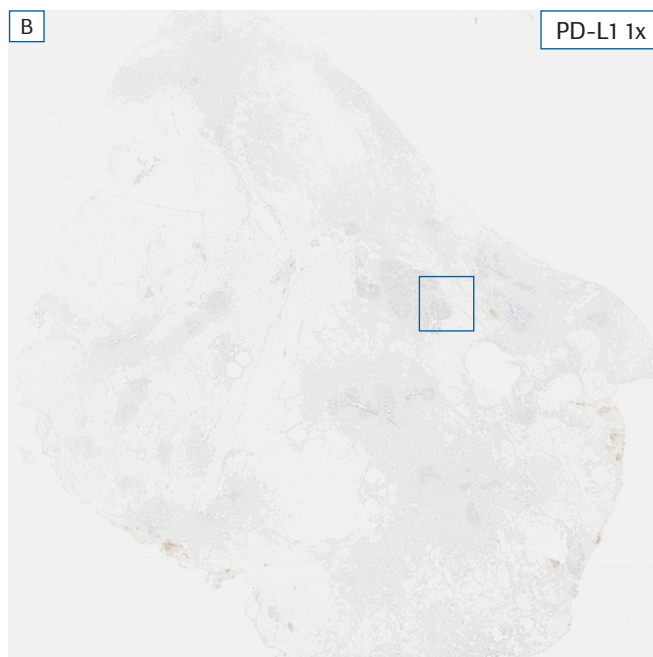
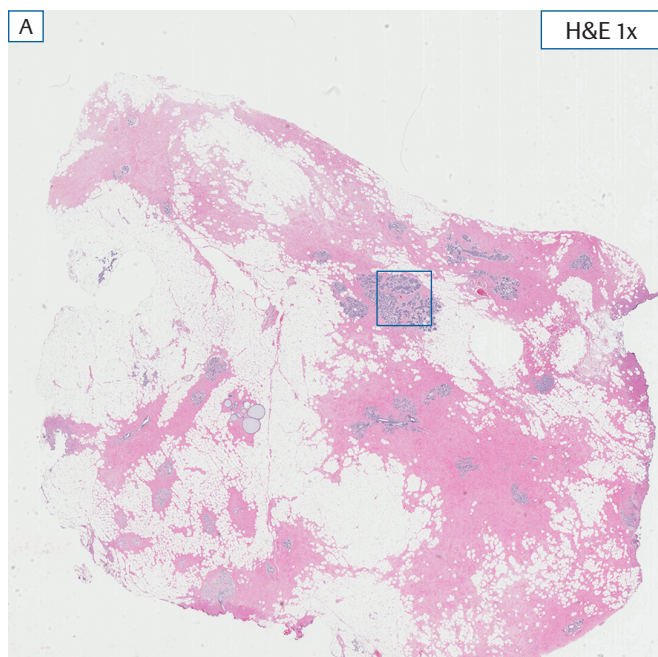
Index of challenging cases

- **Challenging case 1: Ductal carcinoma in situ (DCIS)**
- **Challenging case 2: Lobular carcinoma in situ (LCIS)**
- **Challenging case 3: Tumor within lymph node**
- **Challenging case 4: Foreign material**
- **Challenging case 5: Biopsy cavities and giant cells**
- **Challenging case 6: Biopsies and speckling**

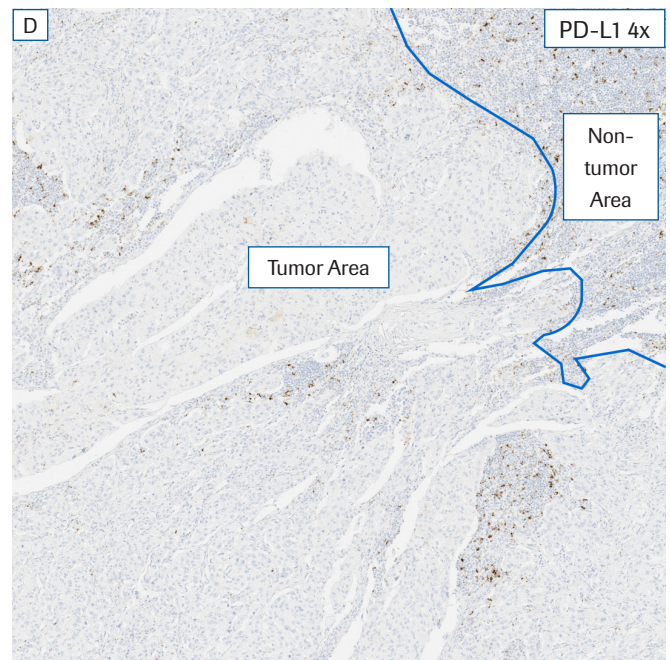
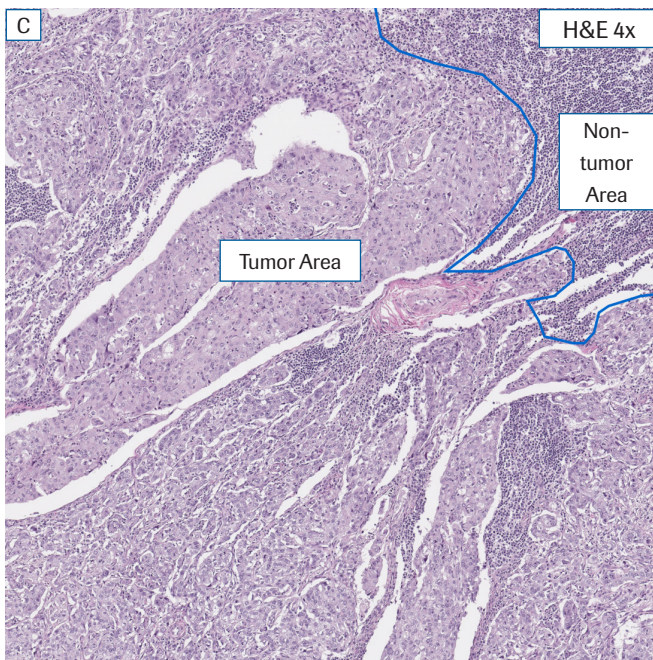
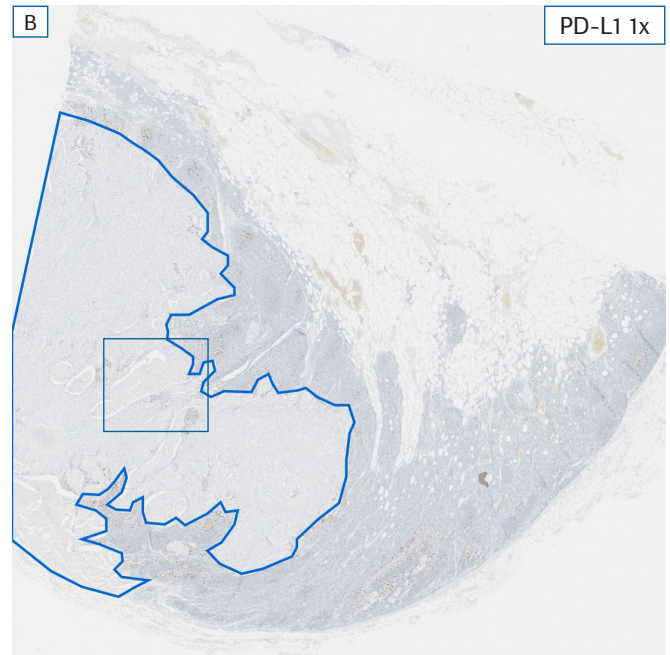
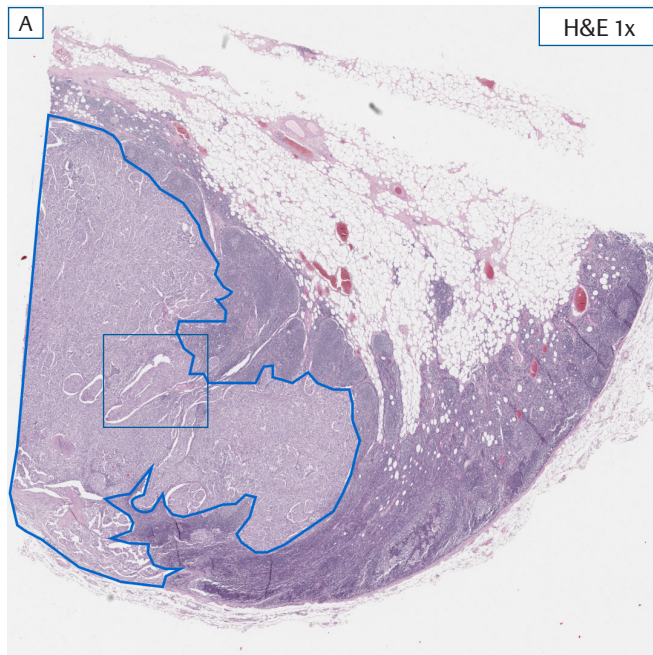
Examples of challenging cases are shown on the following pages.



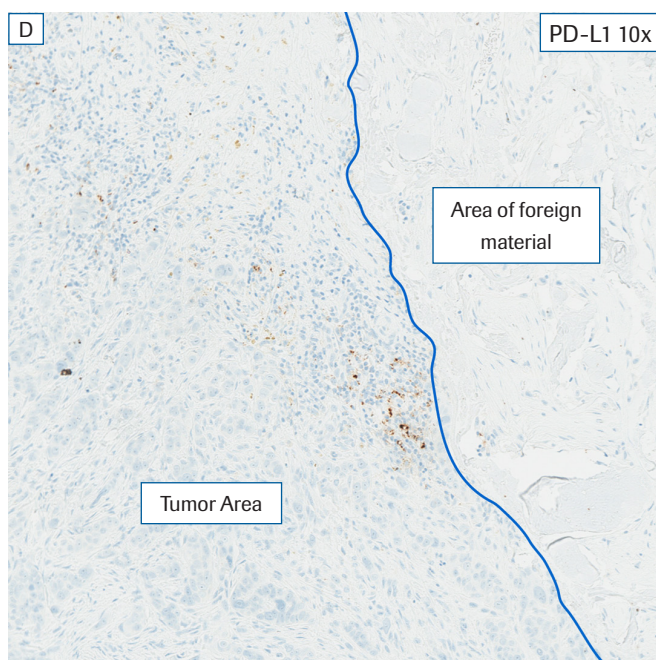
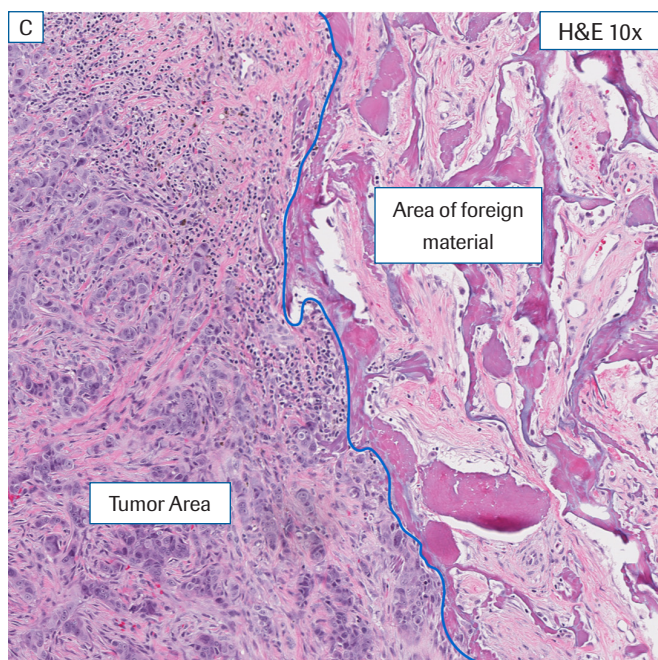
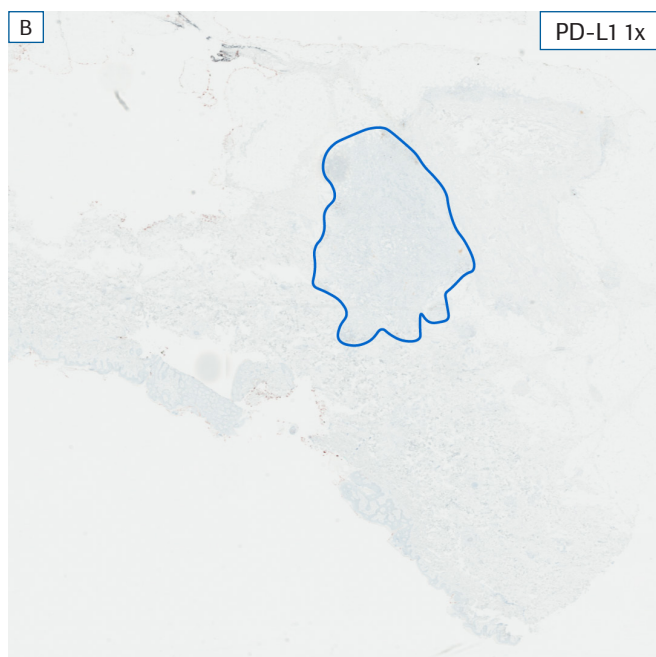
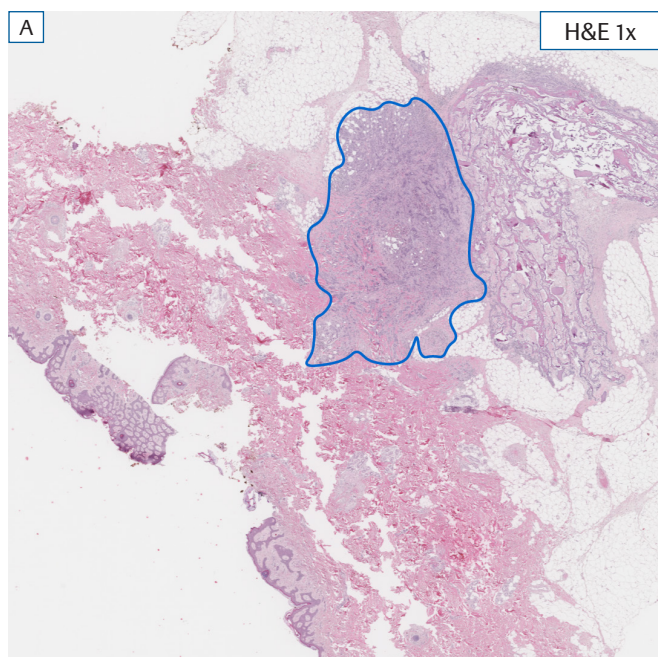
Challenging Case 1: DCIS - only DCIS, without an invasive component, is seen in this case. Boxed region in A is shown at higher magnification in C; boxed region in B is shown at higher magnification in D. PD-L1-stained IC seen in areas of DCIS are not included in the PD-L1 IC scoring. If there is an invasive component, only IC that are located within the defined invasive tumor area are included in the PD-L1 IC scoring.



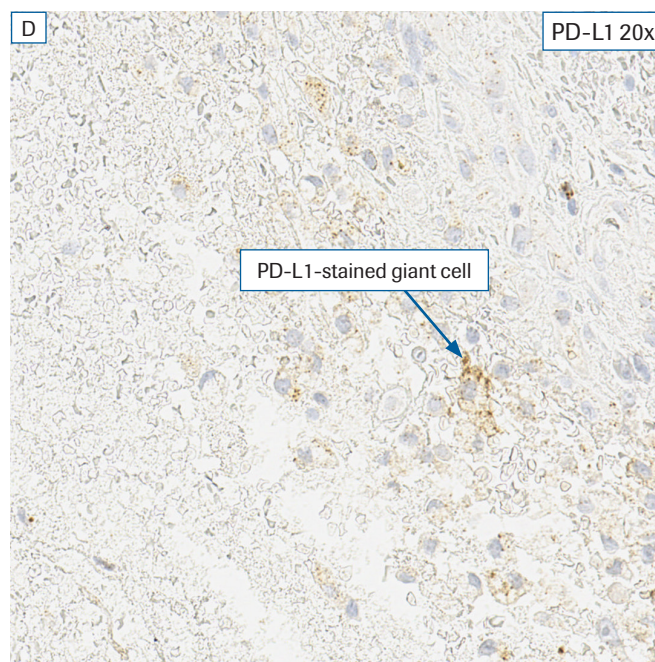
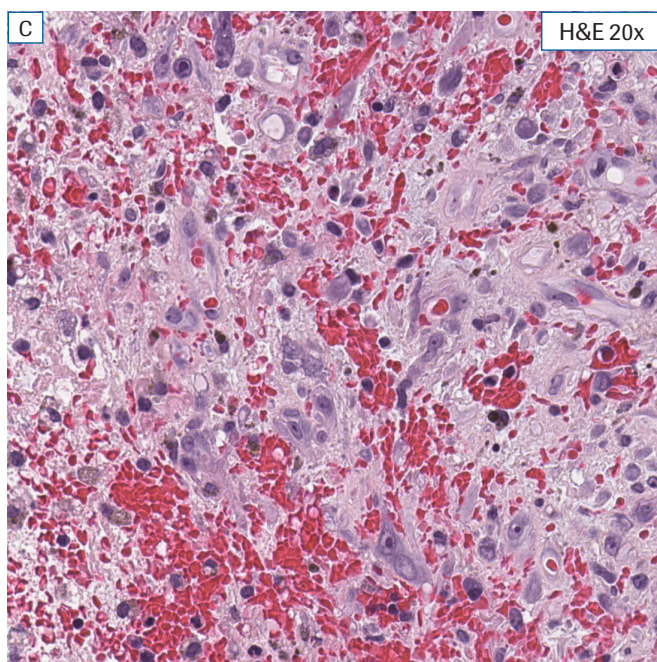
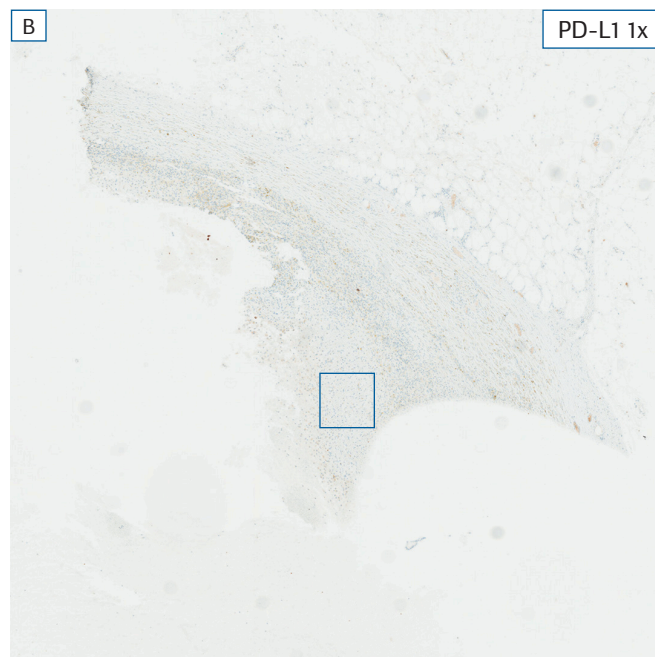
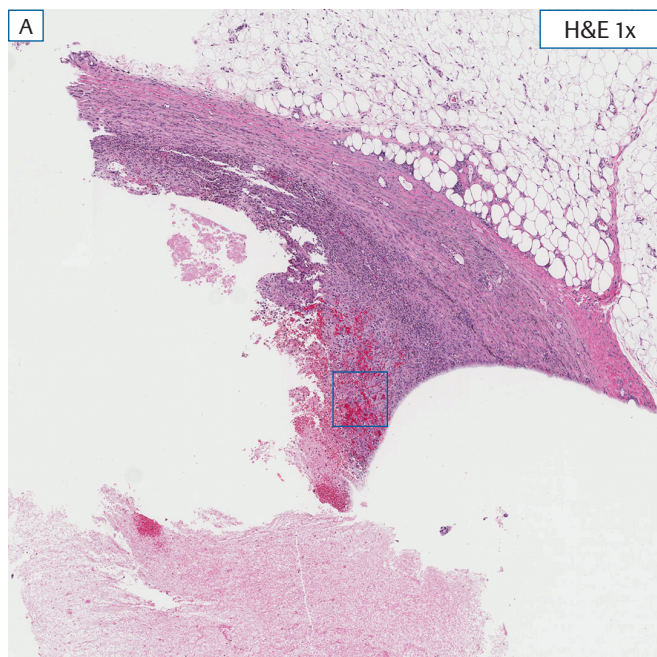
Challenging Case 2: LCIS - only LCIS, without an invasive component, is seen in this case. Boxed region in A is shown at higher magnification in C; boxed region in B is shown at higher magnification in D. PD-L1-stained IC seen in areas of LCIS are not included in the PD-L1 IC scoring. This case does not have any IC staining. If there is an invasive component, only IC that are located within the defined invasive tumor area are included in the PD-L1 IC scoring.



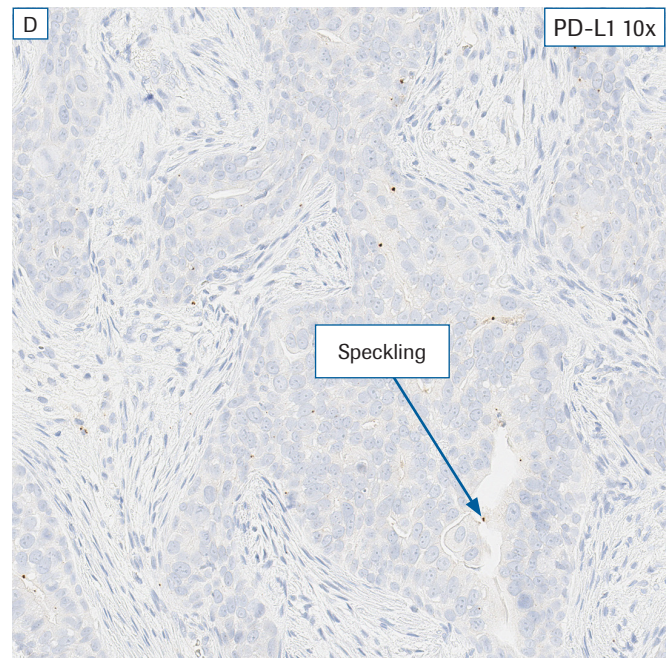
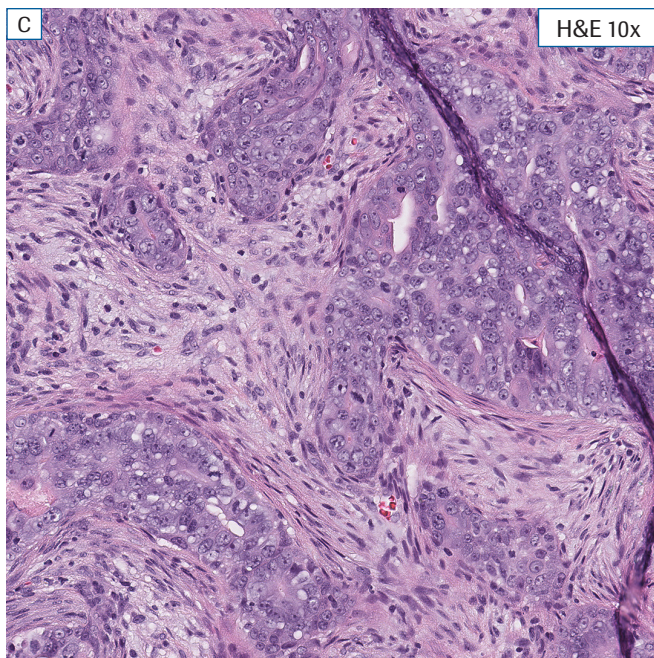
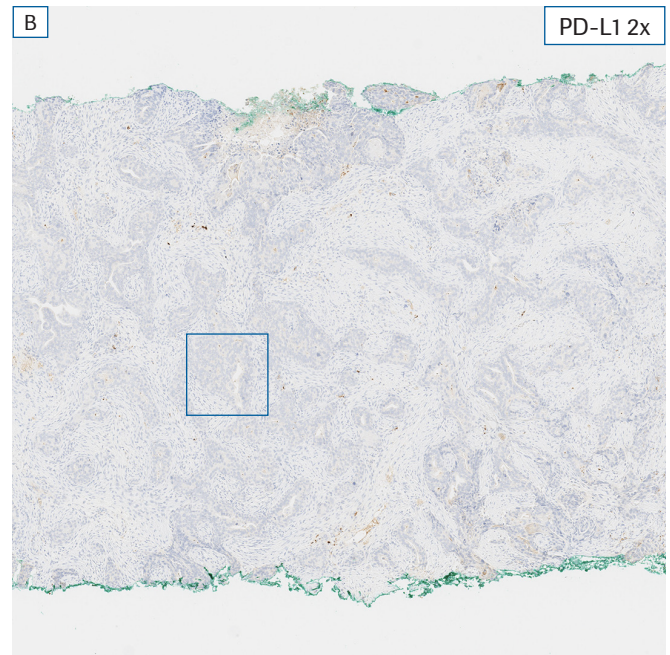
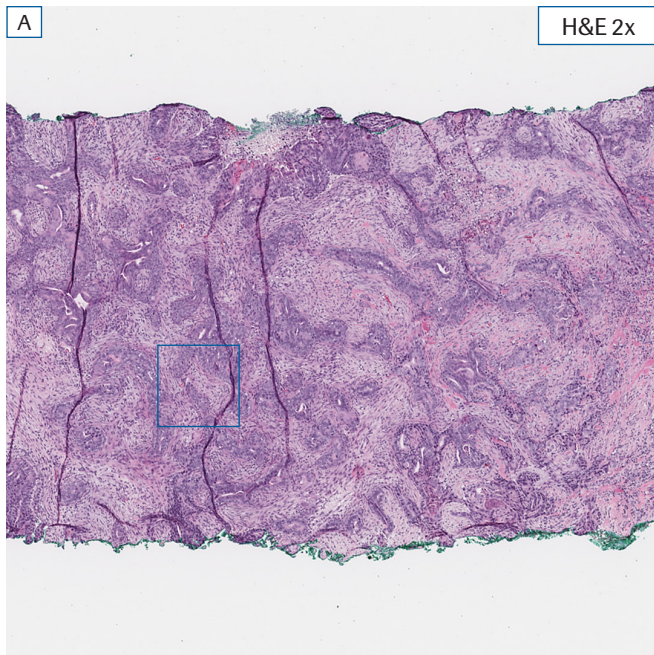
Challenging Case 3: Tumor within lymph node – this case contains tumor within a lymph node. Boxed region in A is shown at higher magnification in C; boxed region in B is shown at higher magnification in D. The tumor area is circumscribed from the uninvolved lymph node (non-tumor area) in A and B. Images C and D illustrate tumor area delineated from the non-tumor area. Only PD-L1 staining within the tumor area is included in the PD-L1 IC scoring.



Challenging Case 4: Foreign material - like areas of necrosis, areas of foreign material are excluded from the tumor area. Here, the tumor area is encircled on the H&E-stained slide in A and corresponding PD-L1-stained slide is seen in B. Image C and D show the tumor area delineated from the area of foreign material at higher magnification.



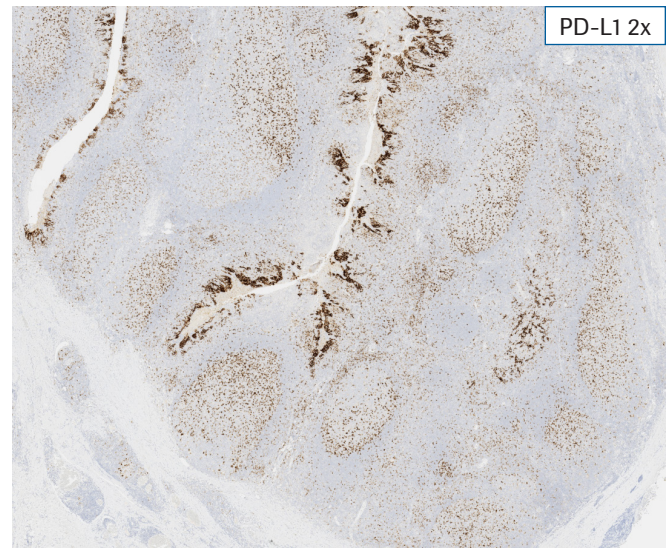
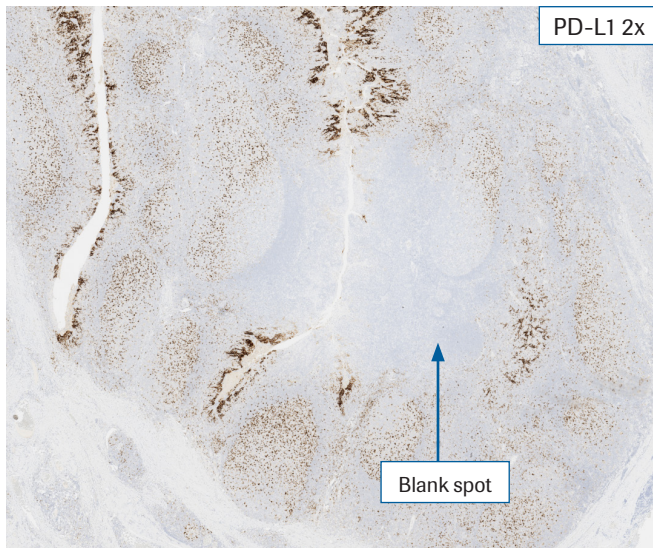
Challenging Case 5: Biopsy cavities and giant cells - biopsy cavities can contain giant cells, which are derived from macrophages and therefore may exhibit PD-L1 staining. Boxed region in A is shown at higher magnification in C; boxed region in B is shown at higher magnification in D. PD-L1 staining in these giant cells is not included in the IC scoring if no viable tumor is present in association with the giant cells.



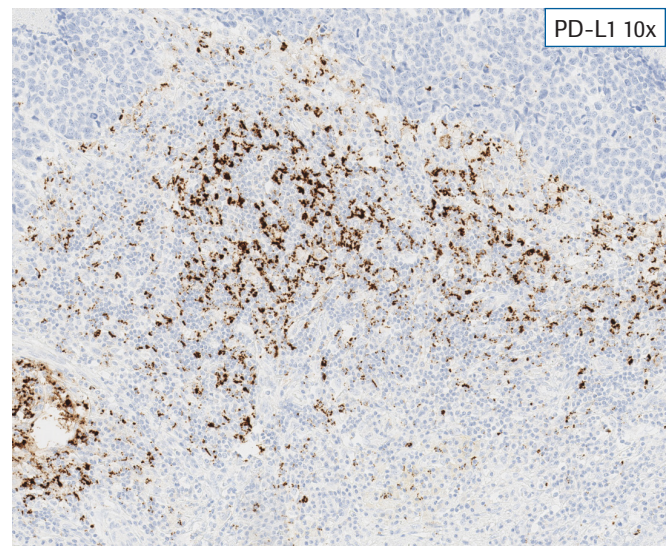
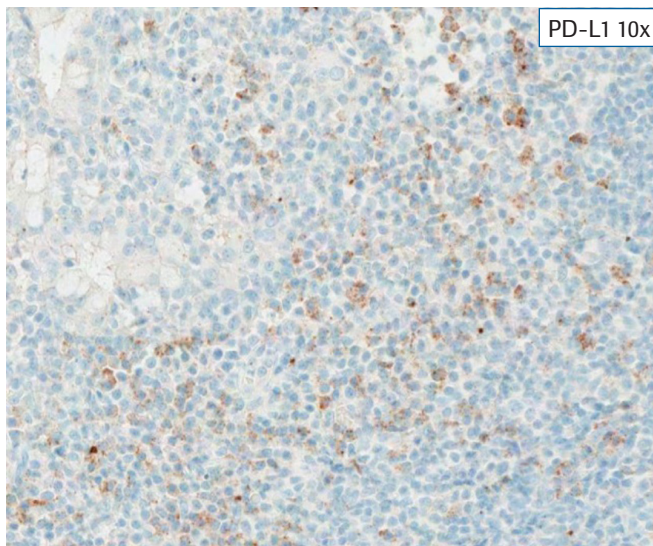
Challenging Case 6: Biopsies and speckling - speckling may be observed, particularly in biopsies. Boxed region in A is shown at higher magnification in C; boxed region in B is shown at higher magnification in D. Speckling consists of small, single punctate dots of lighter staining in contrast to the larger punctate darker membranous staining of IC. Speckling is not included in PD-L1 IC assessment.

Staining Artifacts

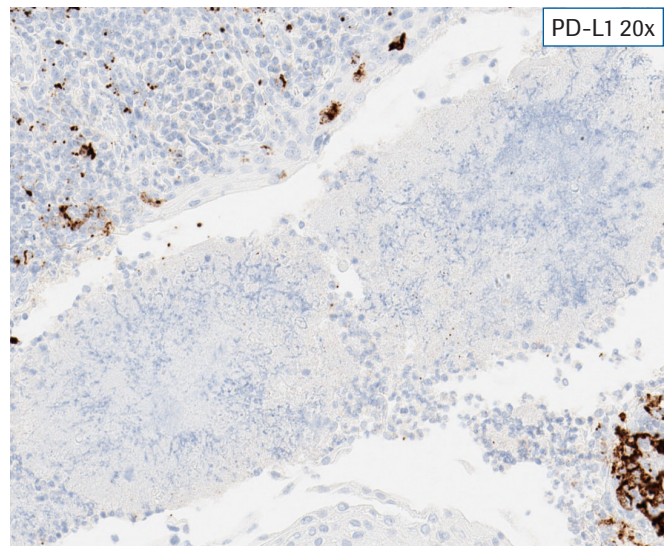
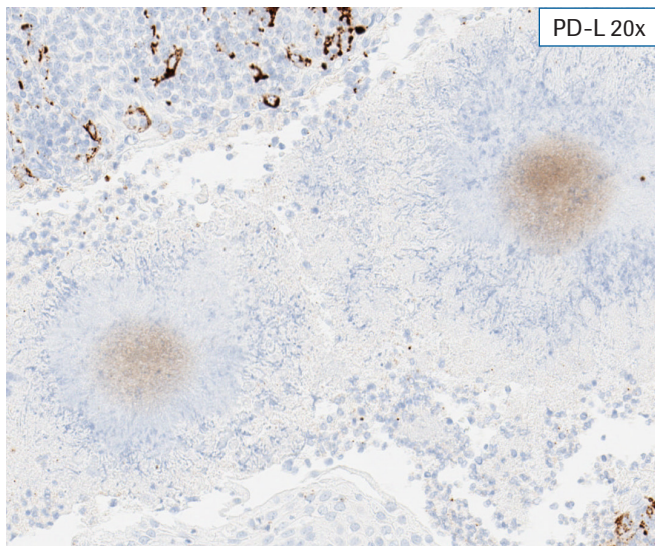
Artifacts noted in this section may be observed on Negative Reagent Control and VENTANA PD-L1 (SP142) Assay-stained slides. The presence of these artifacts may require repeat staining if they interfere with interpretation of VENTANA PD-L1 (SP142) Assay staining. Always review the corresponding Negative Reagent Control-stained slide to ensure that non-specific background staining is within acceptable limits.



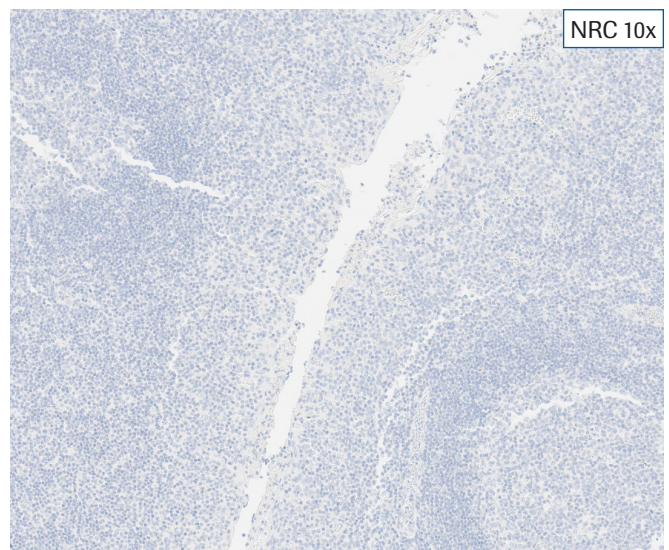
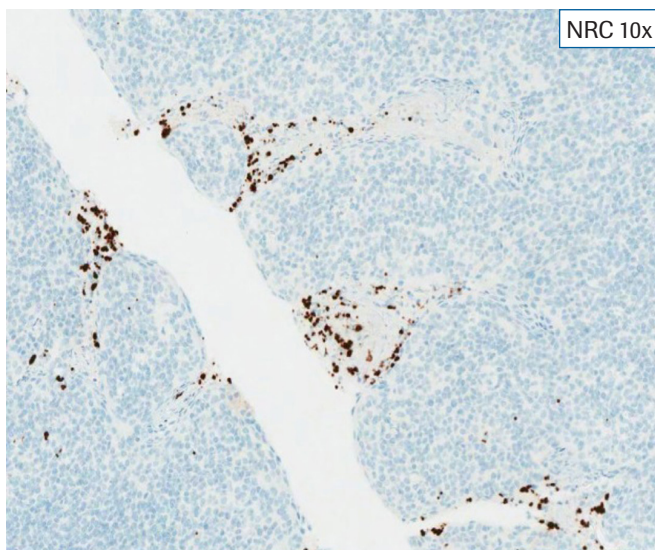
Blank Spots: Blank spots are light to non-staining areas that are typically circular and are due to a static bubble formed during staining procedure. The image on the left depicts an example of a blank spot opposed to the appropriate staining depicted in the image on the right. If the blank spot interferes with interpretation of the PD-L1-stained slide, a repeat run may be required.



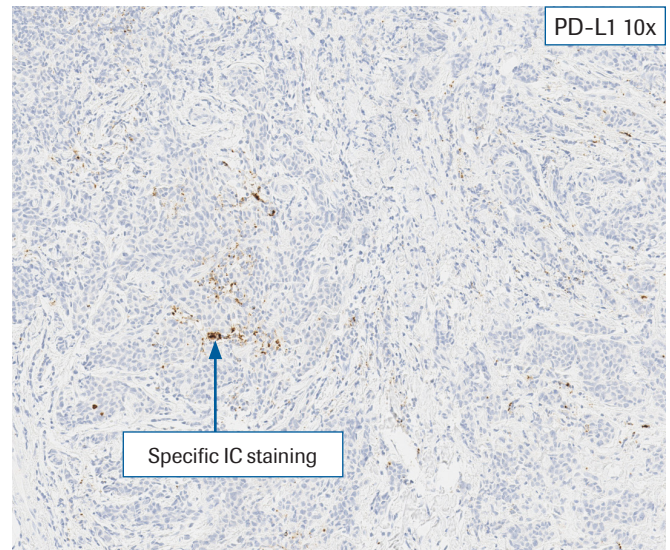
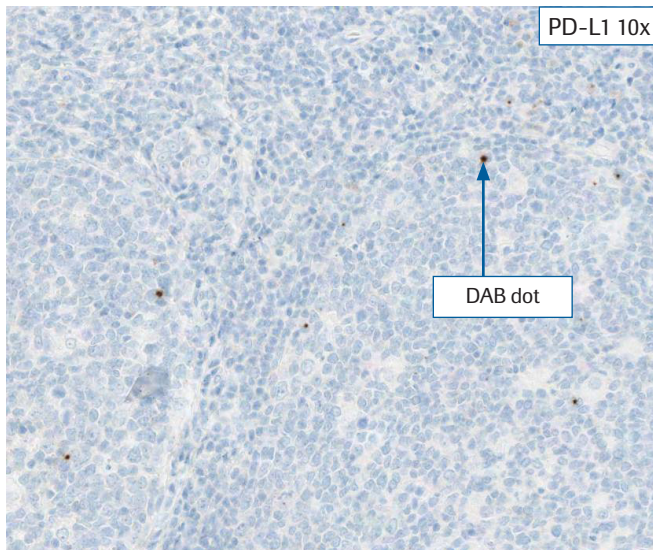
Speckling: Speckling, depicted in the image to the left, is weak to moderate non-specific staining that appears as a uniformly distributed fine granular precipitate most often in the cytoplasm. Speckling does not conform to either IC or TC staining characteristics. This artifact should not be confused with specific staining such as depicted in the image to the right.



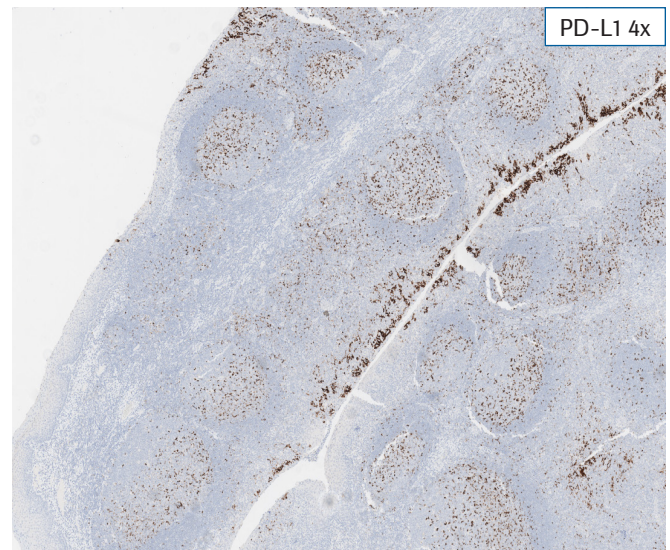
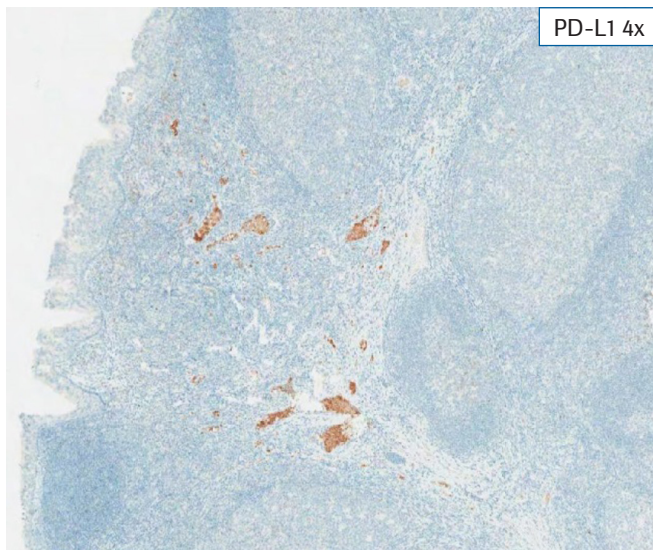
DAB Spots: DAB spots are circular spots that may form due to trapped DAB underneath the tissue section during the staining procedure. If this artifact interferes with the interpretation of the PD-L1-stained slide, repeat the stain with fresh unstained slides. In the image to the right, the DAB spot is not present with repeat staining of a serial section.



Luminal Debris: Tonsil stained with VENTANA PD-L1 (SP142) Assay can serve as both a positive and negative tissue control due to positive and negative staining elements being present. Luminal staining due to cross reactivity with an unknown antigen can be observed in the image of a tonsil stained with NRC on the left. An appropriate example of tonsil stained with NRC is depicted on the right. If you choose to run NRC on tonsil control tissue and luminal debris is observed, the sample should not be used as control.



DAB Dots: Non-specific punctuate background may be observed on tonsil or other lymphoid organs and are small, indiscriminate staining artifacts from the detection system. In comparison to IC, DAB dots are smaller and exhibit a different, crisp morphology outline than the punctate IC staining. Expected immune cell staining can be seen in the image to the right.



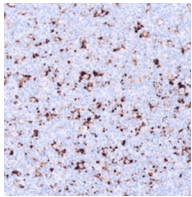
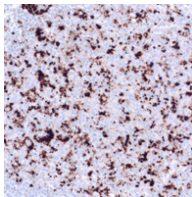
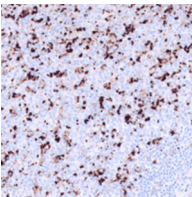
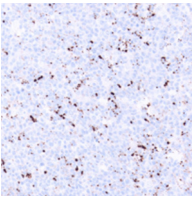
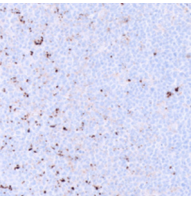
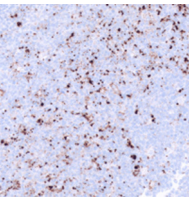
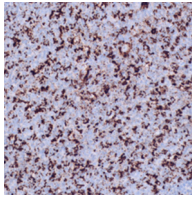
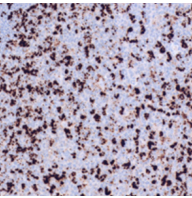
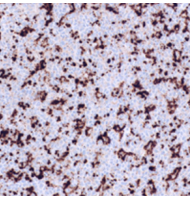
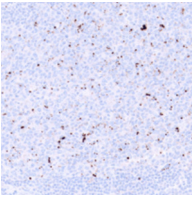
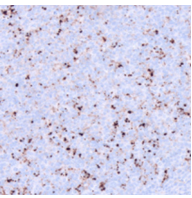
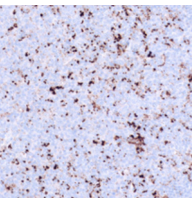
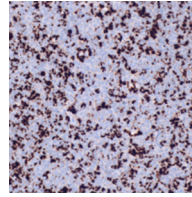
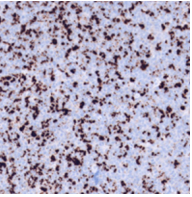
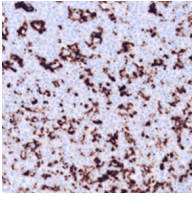
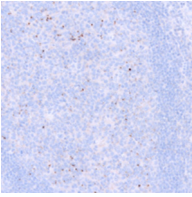
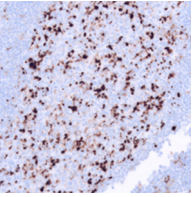
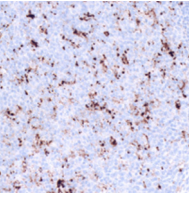
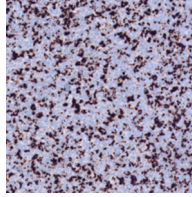
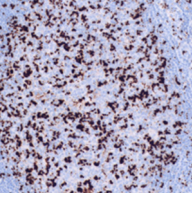
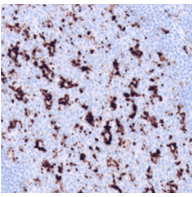
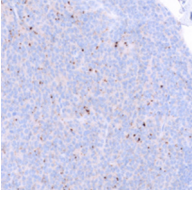
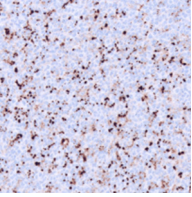
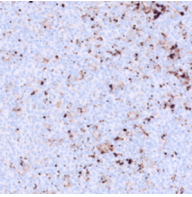
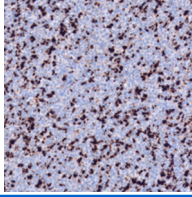
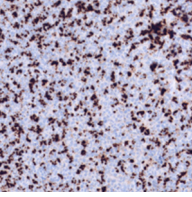
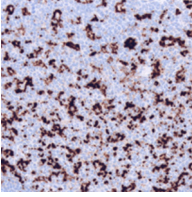
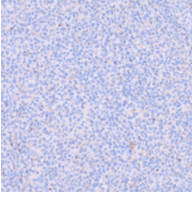
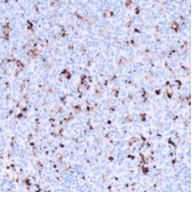
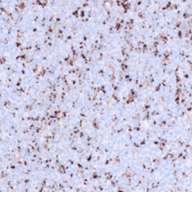
Serum Background: Serum background is non-specific staining in vascular spaces and serum extravasates. This is depicted in the image to the left. It should not be confused with specific staining as depicted in the image to the right.

Impact of Pre-analytical Conditions on VENTANA PD-L1 (SP142) Assay

Acceptable Fixation Conditions to Achieve Optimal Staining Results

- Ventana recommends fixation in 10% NBF for 6-72 hours. See acceptable Fixatives and fixation times in blue box below.
- Zinc Formalin demonstrates comparable staining to 10% NBF.

Table 4: VENTANA PD-L1 (SP142) Assay Staining of Human Benign Tonsil Tissue Across Fixatives and Fixation

Time Hours	Fixative					
	10% NBF	Zinc Formalin	Z-5*	PREFER*	AFA*	95% Alcohol*
1*						
6						
12						
24						
72						

(all images 20x magnification)

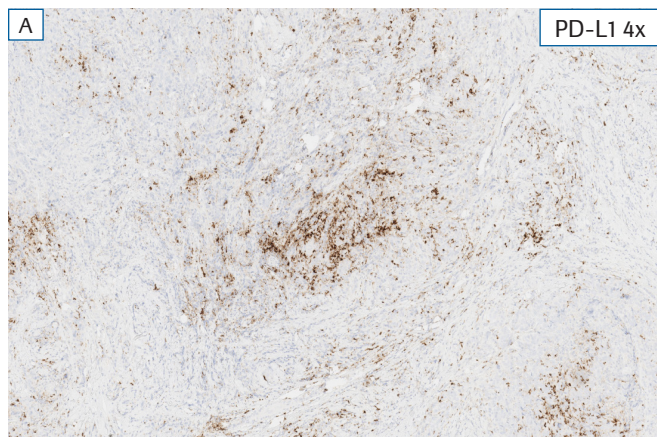
The following fixatives and fixation times are **not recommended**:

- Less than 6 hour fixation is not recommended.
- Samples fixed with Z-5 (Anatech Ltd) demonstrate inconsistent staining with those fixed in 10% NBF; Z-5 fixation is not recommended.
- PREFER (Anatech, Ltd.) and alcohol fixatives including AFA (weaker staining) are not recommended.

Cut Slide Stability

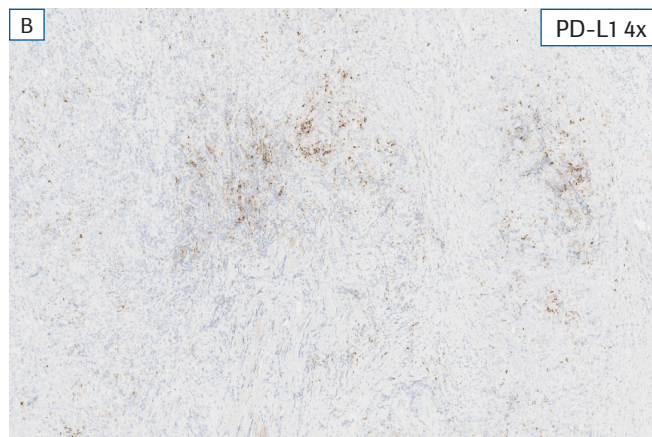
Ventana has determined that VENTANA PD-L1 (SP142) Assay should not be performed on cut slides that have been stored longer than 2 months. The intensity of the staining decreased when slides were stored at room temperature past the recommended storage time. Examples are shown below. Ventana

has not tested the impact of diminished antigenicity of cut tissue sections combined with different fixatives. Tissue fixed with a fixative other than NBF may exhibit decreased staining intensity in cut tissue sections stored less than 2 months.



Case 1 freshly sectioned and stained TNBC tissue.

Although both slides are positive for PD-L1 staining, note diminished staining on the slide stored at ambient (room temperature) past the recommended storage period (B) compared to the freshly sectioned stained slide (A).



Case 1 slides stored at ambient (room temperature) after two months.

References

1. Rodler E, Korde L, and Gralow J. Current treatment options in triple negative breast cancer. *Breast Dis.* 2010;32(1-2):99-122.
2. Blank C, Mackensen A. Contribution of the PD-L1/ PD-1 pathway to T-cell exhaustion: an update on implications for chronic infections and tumor evasion. *Cancer Immunol Immunother.* 2007;56(5):739-745.
3. Butte MJ, Keir ME, Phamduy TB, et al. Programmed death-1 ligand 1 interacts specifically with the B7-1 costimulatory molecule to inhibit T cell responses. *Immunity.* 2007;27(1):111-122.
4. Dong H, Zhu G, Tamada K, et al. B7-H1, a third member of the B7 family, co-stimulates T-cell proliferation and interleukin-10 secretion. *Nat Med.* 1999;5(12):1365-1369.
5. Herbst RS, Soria JC, Kowanetz M, et al. Predictive correlates of response to the anti-PD-L1 antibody MPDL3280A in cancer patients. *Nature.* 2014;515(7528):563-567.
6. Schmid P, Adams S, Rugo HS, et al. Atezolizumab and Nab-Paclitaxel in Advanced Triple-Negative Breast Cancer. *N Engl J Med.* 2018;379(22):2108-2121.



Refer to the corresponding VENTANA
PD-L1 (SP142) Assay package insert for
manufacturer contact information.

www.ventana.com

© 2019 Ventana Medical Systems, Inc. and
Roche Diagnostics International, Inc. All
rights reserved.

VENTANA, BENCHMARK and OPTIVIEW and
the VENTANA logo are trademarks of Roche.
All other trademarks are the property of their
respective owners.

1018231EN Rev D
2019-06-28

IVD

