

# A Systematic Approach to the Class IV Restoration

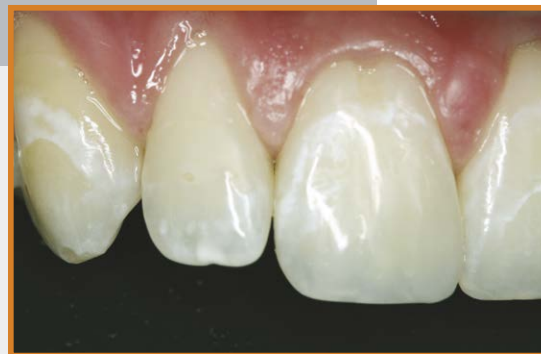Camille J. Zelen, DDS

## Abstract

The restoration of a Class IV fracture is a commonly encountered challenge in dentistry. This clinical occurrence, often the result of a traumatic event, can interrupt an already busy schedule. The patient, unsure of the prognosis, may be somewhat fearful or anxious upon presenting for treatment. Having a step-by-step procedure in place for this type of situation enables the treating dentist to deliver a predictable result that is both clinically sound and of optimal esthetics. Contemporary composites offer a range of characteristics and indications, making them the material of choice for Class IV restorations. Because of the traumatic origin of many Class IV fractures, it is preferred to deliver a noninvasive, conservative treatment to allow the tooth to recover from the injury, thereby supporting a more favorable long-term prognosis. Patient habits and occlusal forces must be considered in conjunction with proper preparation design and composite selection when considering a Class IV composite. A resin restoration is a clinically sound and esthetically superior treatment option that is conservative in nature, preserving vital tooth structure in an already traumatized tooth. This article discusses a step-by-step approach to treating a patient who presented with Class IV fractures on his maxillary central incisors.

**Key Words:** Class IV, MIFL fracture (Ellis II), bonding, composite, Accreditation Case Type IV

// Shade mapping provides a predictable roadmap for layering the composite to achieve lifelike esthetics that blend seamlessly into the dentition. //



## Introduction

Patients who present with a Class IV fracture often are upset and apprehensive. Clinicians who are able to confidently provide timely treatment that is both conservative and optimally esthetic can help to alleviate their concerns. Also, there are times when patients will present with an existing Class IV composite restoration with poor esthetics; these patients may be emotional due to a previous negative dental experience, as well as have heightened anxiety about the prospect of undergoing additional treatment. Another subcategory of those seeking a Class IV restoration are young patients whose parents want to avoid invasive treatments such as root canals and crowns and wish to improve the esthetics of the existing composite restoration via a more conservative approach. The multitude of composite options available to today's dentist makes direct bonding an ideal noninvasive, highly esthetic, and economical solution in all these situations.<sup>1,2</sup>

## Case Presentation

### Patient's Complaint and History

A 24-year-old male patient presented to the clinic on an emergency basis in the late afternoon stating that he had just fallen and broken his front tooth. He reported that the tooth was sensitive to temperature and touch. The patient was in good general health but said that, due to finances, he had not been to the dentist for several years.

### Evaluation, Diagnosis, and Treatment Plan

Upon intraoral examination the soft tissues were found to be intact. A large mesial-incisal-facial-lingual (MIFL) fracture (Ellis II) of #8 was noted along with a small fracture (Ellis I) of the mesial incisal corner of #9 (Fig 1). Tooth #8 was sensitive to air and pressure. The patient was unaware of the enamel chip on #9, which was asymptomatic. A periapical radiograph of the two teeth was taken to determine the extent of the fractures and their proximity to the pulp (Fig 2). Direct pulpal involvement was ruled out and a limited examination of the rest of the dentition did not reveal any other immediate concerns. The patient reported that he had not been experiencing any other dental issues. (Because this was an Accreditation Case Type IV, the restorative focus was specific to the Class IV restorations on #8 and #9. The generalized decalcification was noted and options for future treatment of these areas were discussed with the patient.)

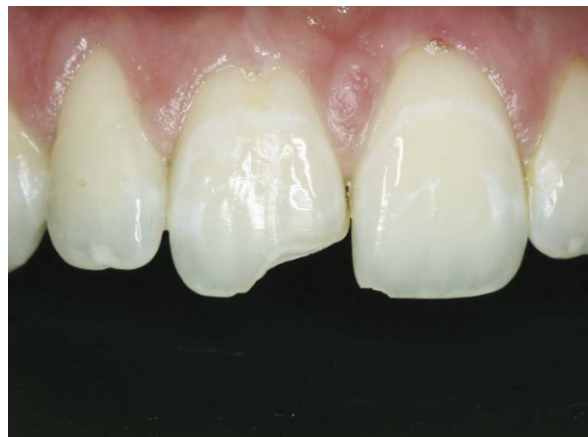In general, his periodontium appeared healthy and overall dentition was intact. After a discussion of the risks of pulpitis and necrosis and the potential need for future root canal therapy and a crown for #8, the patient agreed to stay and proceed with the following treatment plan:

- an immediate Class IV composite restoration for #8
- a very small Class IV restoration for #9
- a postoperative visit to reevaluate the two teeth, along with a comprehensive examination and prophylaxis.

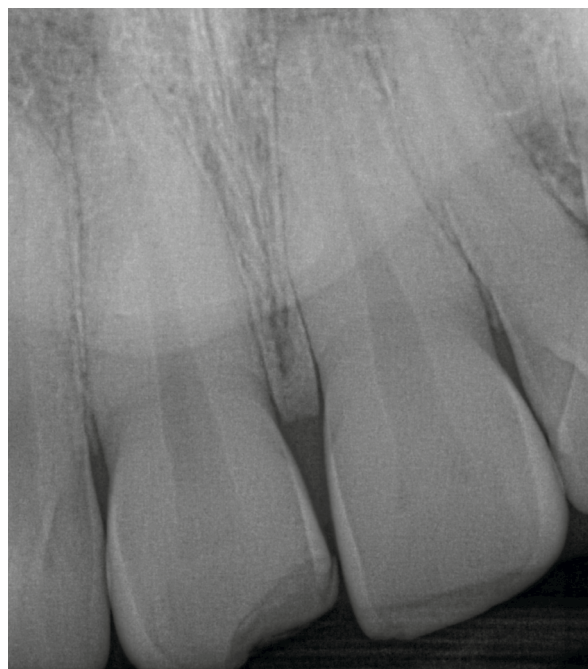
Once the treatment plan was accepted, the full preoperative series of AACD Accreditation photographs was taken. Next, multiple shades of composite were tested against the dentition for shade mapping. This was done by curing small amounts of composite against the central incisors to evaluate chroma, hue, and value. Enamel and dentin shades were then selected. For accuracy, it is critical to complete this step prior to any preparation or dehydration of the teeth.<sup>3</sup> Shade mapping provides a predictable roadmap for layering the composite to achieve lifelike esthetics that blend seamlessly into the dentition.

### Treatment

**Mock-up and preparation:** Anesthesia was accomplished with 1.7 mL of 4% Septocaine 1:100,000 (Septodont; Louisville, CO) above the apices of

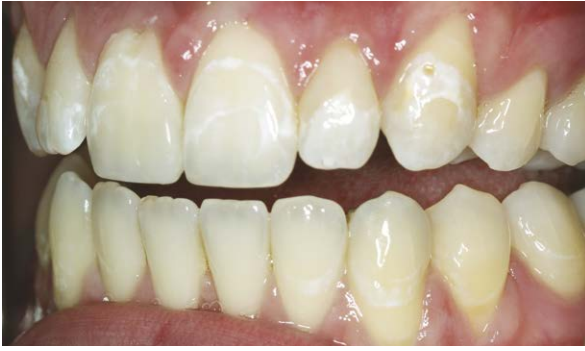

**Figure 1:** The preoperative retracted anterior view (1:1) shows the incisal corner fractures of #8 and #9.

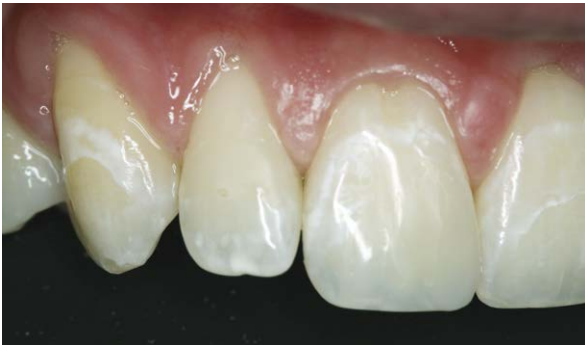

**Figure 2:** A preoperative periapical x ray ruled out pulpal involvement or pathology.

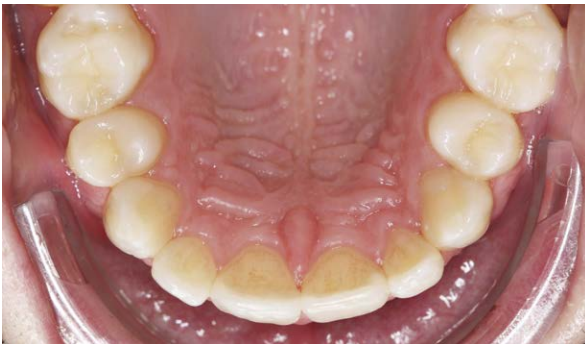|| The location of the incisal edge and its embrasures and the mesial and distal width were most important, as this step was the foundation of the outline form for the final restoration. ||



**Figure 3:** The postoperative retracted left lateral view (1:2) shows the recreation of the incisal halo, which blends seamlessly into the intact tooth structure on the central incisors.



**Figure 4:** Postoperative retracted right lateral view (1:1). A milky-white microhybrid composite is ideal for recreating the incisal halo due to its opacity and increased edge strength.



**Figure 5:** The maxillary occlusal view (1:2) evaluates and confirms accurate replication of secondary anatomy and embrasure contours.

When restoring central incisors, one must pay careful attention to achieve near perfect symmetry in the contours and optical qualities of the adjacent central incisor as well as in the surrounding dentition.

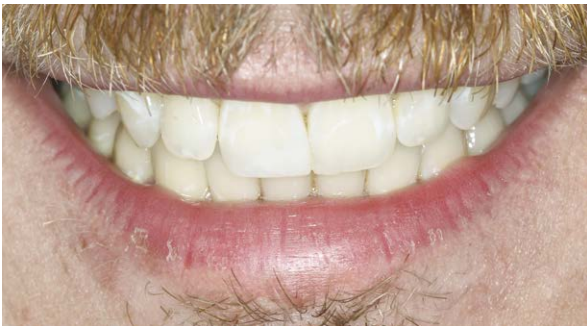#8 and #9. The teeth were isolated with a latex-free retractor (Optragate, Ivoclar Vivadent; Amherst, NY). A quick mock-up of the restoration without bonding was done on #8 using a single shade to obtain the desired outline form.<sup>3-6</sup> This was cured into place and the shape and contours of the proposed final restoration were refined in the mock-up. The location of the incisal edge and its embrasures and the mesial and distal width were most important, as this step was the foundation of the outline form for the final restoration. A putty matrix (Exafast, GC America; Alsip, IL) was then made of the mock-up.<sup>4-6</sup> Once the putty was set it was removed and cut mesiodistally, leaving only the very lingual and palatal portions to provide support for formation of the lingual wall.<sup>3,4</sup> This matrix captured the desired gingival incisal height, mesiodistal width, faciolingual depth, and position of the incisal edge.<sup>3</sup> The fit of the matrix was verified to ensure proper trimming of excess putty. The mock-up was removed easily as bonding was not used.

The small chipped area of enamel on #9 was minimally prepared, removing only unsupported enamel using a fine flame diamond (862-012F, Patterson Dental; St. Paul, MN). The enamel was prepared for bonding with a 35% phosphoric acid gel for approximately 25 seconds (Ultra-Etch, Ultradent Products; South Jordan, UT). After a thorough rinsing, the preparation was dried of excess moisture. A single-component, total-etch adhesive (Excite F, Ultradent) was scrubbed into the enamel for 20 seconds, then air-thinned and light-cured. A very small amount of resin (Renamel Nano shade A3, Cosmedent; Chicago, IL) was placed to restore the mesial incisal corner. Shaping and contouring was achieved freehand with Cosmedent composite instruments and brushes. Because the fracture was small and limited to the natural incisal halo area, only a single shade layer of composite was needed to recreate the halo's appearance (Fig 3). Tooth #9 was shaped and polished with aluminum oxide discs (FlexiDisc, Cosmedent), after which #8 was prepared by placing a facial bevel at a 45-degree angle to the fracture line and feathering out in a starburst pattern.<sup>3,4</sup>

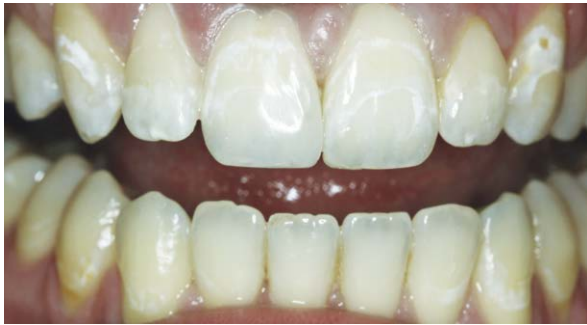**Etching and layering:** Once the minimal preparation was completed, the adjacent teeth were protected with plumber's tape. The matrix was tried in again to ensure proper seating with the tape in place and #9 restored. While it was seated in the mouth, the matrix was scored along the fracture line as a guide in placing the lingual composite layer into the matrix.<sup>4</sup> With the matrix removed, the prepared outline of enamel was etched in the same manner for 10 seconds, after which the phosphoric acid gel was extended over the entire preparation, including the dentin, for 15 additional seconds. The adhesive was scrubbed on the preparation for 20 seconds, then air-thinned and light-cured. A thin layer of liquid resin (Brush & Sculpt, Cosmedent) was placed into the lingual matrix to aid in removal after curing of the initial lingual layer.<sup>6</sup> A flowable microhybrid composite (Renamel shade milky white occlusal [MWO], Cosmedent) was layered very thinly onto the lingual matrix, paying attention to the creation of the incisal halo present on #9 (Fig 4).<sup>6-9</sup> The scored line indicating the fracture outline is helpful to avoid overfilling the lingual wall.<sup>4</sup> The matrix was seated and a small condensing instrument was used to seal all edges of the lingual and most of the interproximal area. Again, attention was paid to the creation of the incisal halo by leaving a slightly thicker amount of the MWO composite at the very incisal edge.<sup>8-10</sup> After curing the lingual wall, the dentin layer was built using resin shade A3.<sup>11,12</sup>

While working with small amounts of composite for precise control, time was spent carefully replicating the mamelons as visible in #9 using the small condensor.<sup>6,12</sup> Next, a very thin amount of shade BO opaquener was placed with a #1 brush to aid in masking the fracture line. The

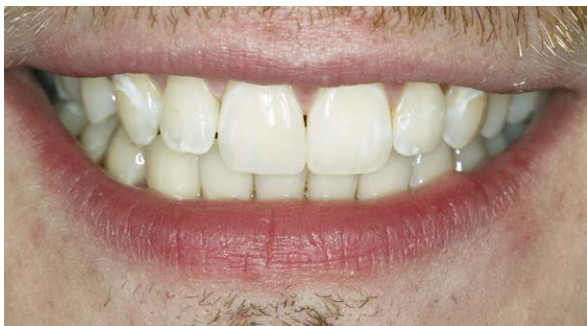



**Figure 6:** Postoperative smile, frontal view (1:2); the opacity was too noticeable and unnatural looking.



**Figure 7:** Postoperative retracted frontal view (1:2). The mamelon placement and facial contours were not symmetrical in the evaluation of the first composite restoration of #8, and the decision was made to remove and relayer some of the facial composite to perfect the esthetics.



**Figure 8:** Postoperative natural smile; frontal view (1:2). The final restorations blend seamlessly with the adjacent dentition. The light reflection shows symmetrical contours and line angles



**Figure 9:** The postoperative portrait shows final restorations that are esthetic and functional.

opaque tint was cured and then a thin layer of the dentin shade was added to blend the opaque tint. A composite placement instrument (IPCL, Cosmedent) was used to smooth the transition of the composite interproximally and a #3 brush was used to smooth the entire dentin layer. The restoration was evaluated incisally at this point to ensure that the dentin layer was not too thick, allowing sufficient room for a thin enamel layer. Once the dentin layer was cured it was safe to remove the lingual matrix. The tape was also removed so that the last layer of composite could be pulled through interproximally with a clear mylar strip to create a smooth transition into the contact area.<sup>13</sup> The final enamel layer was placed (Renamel Microfill Light Incisal). The small particles in microfills are highly polishable, making them perfect enamel composites. A clear mylar strip was pulled through the contact area using the “mylar pull” technique.<sup>14</sup> The final enamel layer was then smoothed with the #3 brush prior to the final cure.

Once the restoration was fully cured, the incisal edge position was viewed and modified as needed for symmetry with the adjacent incisor. Occlusion was evaluated and initial adjustments made. Next, the mesial and distofacial line angles were drawn on the tooth and composite as a guide to avoid losing their position while contouring the facial anatomy. After the outline form and embrasures were defined, secondary anatomy including the facial depressions, which were best evaluated from an incisal view, were replicated (Fig 5). The adjacent central naturally had a fairly smooth surface texture so minimal tertiary anatomy was indicated.

By this time in the appointment the adjacent teeth had become dehydrated, making comparisons for colors and characterization unreliable. The patient was scheduled to return one week later to reevaluate for any residual pulpitis and make esthetic modifications as needed. Occlusion was checked again and the patient was dismissed.

**Follow-up visit—modification of #8:** The patient returned the following week and a set of bitewing radiographs, a panoramic radiograph, and a follow-up periapical radiograph of the 8/9 area were taken. A comprehensive oral exam was completed. The patient was healthy periodontally and needed a single occlusal filling on #30. Teeth #8 and #9 were asymptomatic. However, a pronounced opaque area was noted on #8 (Fig 6) and the facial contours lacked symmetry, as seen in the light reflections in Figure 7. The patient was willing to stay for modification of #8.

Local anesthesia of #8 was achieved with 1.7mL of 4% Septocaine. The facial layer of enamel composite was removed along with some of the outer dentin layer and underlying opaque tint. Leaving only a minimal amount of opaquer, the dentin and enamel shades were rebuilt employing the same shades and steps described above. The incisal edge was contoured to the appropriate position, followed by mesial and distal facial line angle placement.<sup>4</sup> Contouring and polishing were completed in the same sequence as at the previous appointment (discs, burs, and points), with a final polish using polishing paste on a felt-coated disc (Enamelize and FlexiBuff, Cosmedent). Flossing confirmed interproximal finishing and occlusion was checked in centric and excursive movements. The patient returned two days later and a final set of postoperative AACD photographs was taken.

## Discussion

Accreditation Case Type IV is an opportunity for the restoring dentist to demonstrate his or her ability to work with a variety of resins and tints to create a customized restoration that mimics nature. A working knowledge

of the characteristics of the different composites and tints available allows the clinician to reproduce the intricate layers and nuances of enamel and dentin found in natural dentition. As observed in this case, even the smallest amount of tint can create a notable appearance in the restoration. When restoring central incisors, one must pay careful attention to achieve near perfect symmetry in the contours and optical qualities of the adjacent central incisor as well as in the surrounding dentition (Fig 8). This case demonstrates how employing a well-ordered procedure to complete a Class IV restoration ensures timely and predictable treatment. Understanding the properties of the many contemporary resins and polishing systems at our disposal allows us to replicate nature and create imperceptible Class IV restorations that blend seamlessly into the dentition.

## Summary

Utilizing a systematic approach to the Class IV restoration allows the dentist to integrate a dental emergency into a busy schedule. The methodology detailed above results in a multilayer restoration that emulates the properties of nature, as well as being clinically sound and esthetically pleasing. It is crucial to discuss with the patient the potential for future pulpal issues with fractured teeth, as well as the possibility of tooth discoloration and possible chipping, prior to proceeding with a Class IV composite restoration. Once patients are informed of their prognosis and treatment options, clinicians can and should embrace the capabilities of composite resins. Being able to immediately provide a definitive restoration in a noninvasive manner can help not only to alleviate patient fear and anxiety, but it also may convert a new patient emergency into a lifelong patient and excellent referral source (Fig 9).

Utilizing a systematic approach to the Class IV restoration allows the dentist to integrate a dental emergency into a busy schedule.



Dr. Zelen maintains a private practice in Duluth, Minnesota.

Disclosure: The author did not report any disclosures.

## Acknowledgment

*The author thanks Ian Parsons, owner of Excel Dental Laboratory (Bargara, Queensland, Australia) for his beautiful and consistent ceramic work, and for his collaboration on the author's AACD Accreditation cases.*

## References

1. Muhamad AH, Azzaldeen A, Mai A. Esthetics of class IV restorations with composite resins. *IOSR-JDMS*. 2016 Jan;15(1):61-6.
2. Strain RL. Class IV composite repair: a heavily textured central incisor. *J Cosmetic Dent*. 2014 Spring;30(1):14-9.
3. Morgan J, Presley S. Making the most of an emergency appointment: a Class IV fracture repair. *Dent Today*. 2008 May;27(5):118, 120.
4. Seay A. Using dental composite to quickly repair class IV fractures. *DC dentalcompare* [Internet]. 2013 May. Available from: <https://www.dentalcompare.com/Featured-Articles/136692-Using-Dental-Composite-to-Quickly-Repair-Class-IV-Fractures/>
5. Fahl N Jr. Step-by-step approaches for anterior direct restorative challenges: mastering composite artistry to create anterior masterpieces—part 2. *J Cosmetic Dent*. Winter 2011;26(4):42-55.
6. Blank JT. Esthetic anterior composite restorations. ADA CERP, PennWell course material. Available from: <https://www.yumpu.com/en/document/read/22671212/esthetic-anterior-composite-restorations-ineedcecom>
7. Romero MF, Austin JG, Todd M. Restoration of a large Class IV fracture using direct composite resin: a clinical report. *J Prosthet Dent*. 2017 Oct;118(4):447-51.
8. Harris ED. Multi-shade composite layering: replacing a single-shade Class IV anterior composite in an adolescent patient. *J Cosmetic Dent*. Spring 2017;33(1):16-21.
9. Dietschi D, Fahl N Jr. Shading concepts and layering techniques to master direct anterior composite restorations: an update. *Br Dent J*. 2016 Dec 16;221(12):765-71.
10. Mopper KW. Let's talk composites! *Dent Today*. 2008 Oct;27(10):118, 120, 122.
11. Marus R. Restoring a Class IV fracture using a compactable, universal nanohybrid composite. *Dent Today*. Nov 2017. Available from: <https://www.dentistrytoday.com/articles/quick-technique/item/2607-restoring-a-class-iv-fracture-using-a-compactable-universal-nanohybrid-composite>
12. Sabbagh J. Golden rules for successful composite resin restorations. *Dent Today*. 2009 Feb;28(2):142, 144-5.
13. Sherwood IA, Rathakrishnan M, Savadamaoorthi KS, Bhargavi P, Vignesh Kumar V. Modified putty index matrix technique with mylar strip and a new classification for selecting the type of matrix in anterior proximal/incisal composite restorations. *Clin Case Rep*. 2017 Jun 1;5(7):1141-6.
14. Willhite C. *Cosmetic composites – achieving great contours and contacts*. Chicago: Cosmedent, Inc.; 2012. Available from: <http://www.dentalcomposites.com/technique-videos/cosmetic-composites--achieving-great-contours-and-contacts/> **JCD**