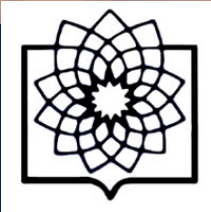




8th **WORLD GLAUCOMA CONGRESS**
MARCH 27 – 30, 2019
MELBOURNE, AUSTRALIA



Secondary Angle Closure

Mohammad Pakravan, MD

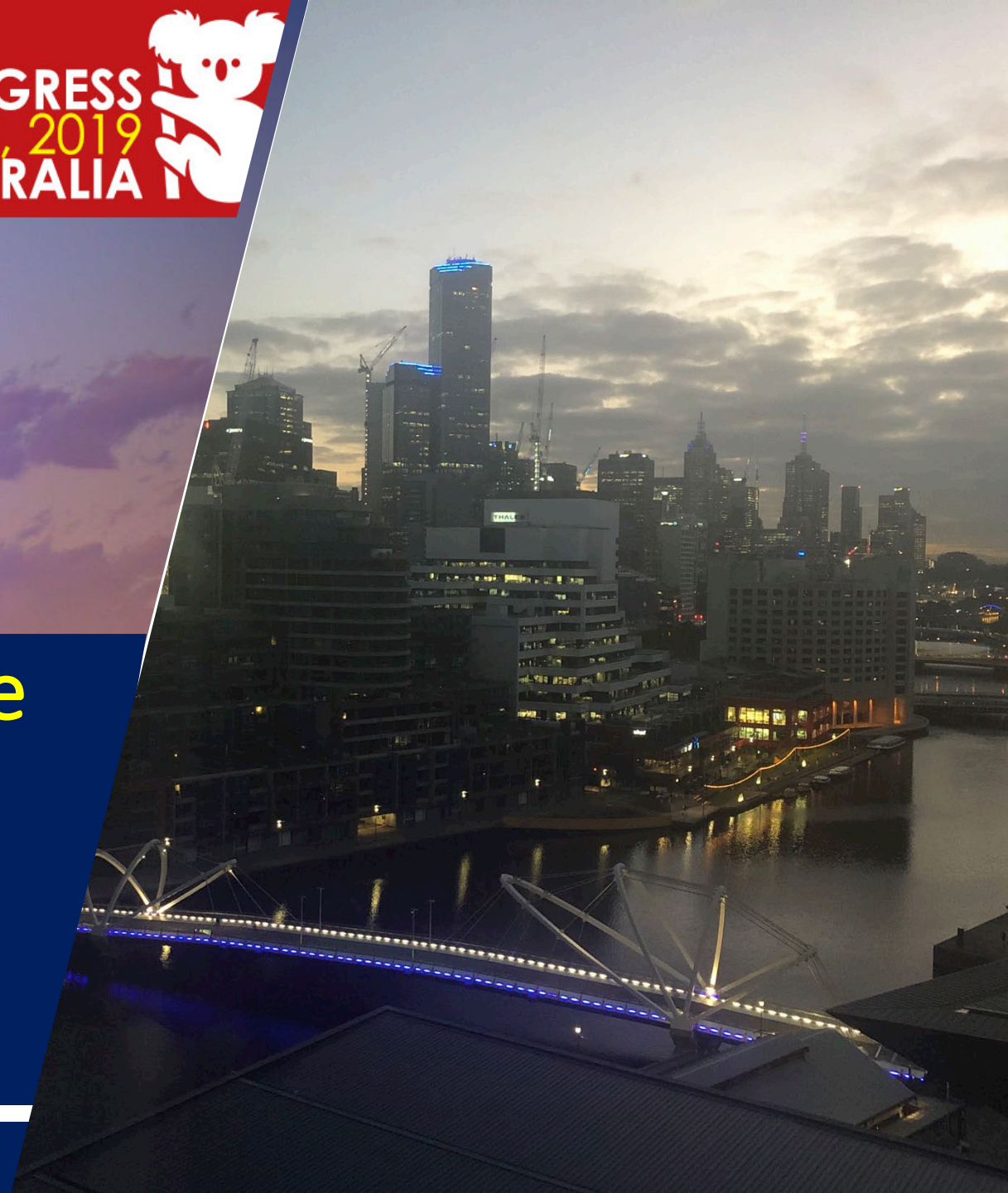Professor of Ophthalmology

Labbafinejad Medical Center

Tehran, Iran

mohpakravan@icloud.com

March 2019





Conflict of Interest Disclosure



I have no potential conflict of interest to disclose



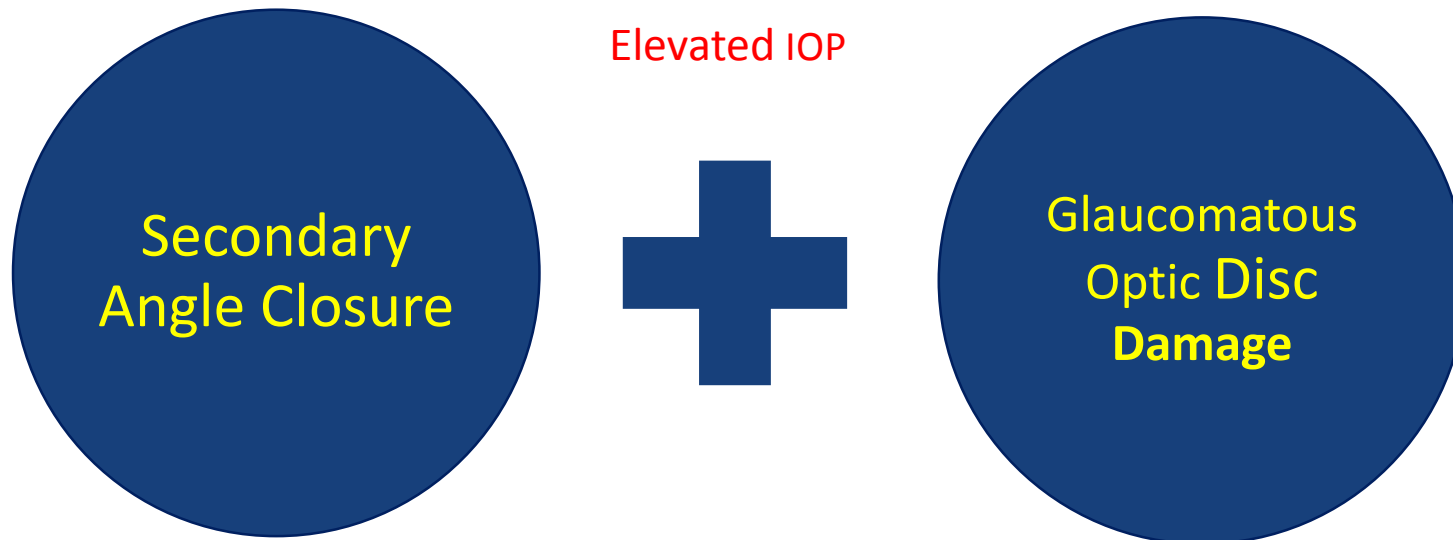
I have the following potential conflict(s) of interest to report :

- ☐ Receipt of grants/research supports:
- ☐ Receipt of honoraria or consultation fees:
- ☐ Participation in a company sponsored speaker's bureau:
- ☐ Stock shareholder:
- ☐ Spouse/partner:
- ☐ Other support (please specify):



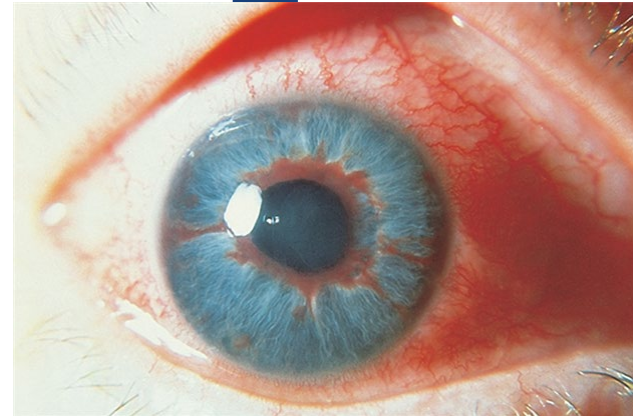
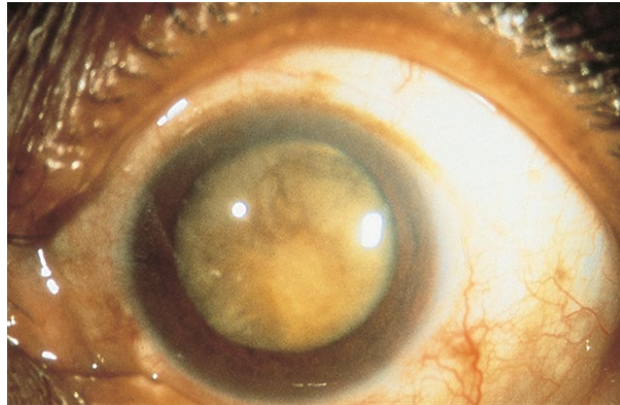
Secondary Angle Closure Vs. Secondary Angle Closure Glaucoma

An Underlying **Identifiable** Pathologic Etiology



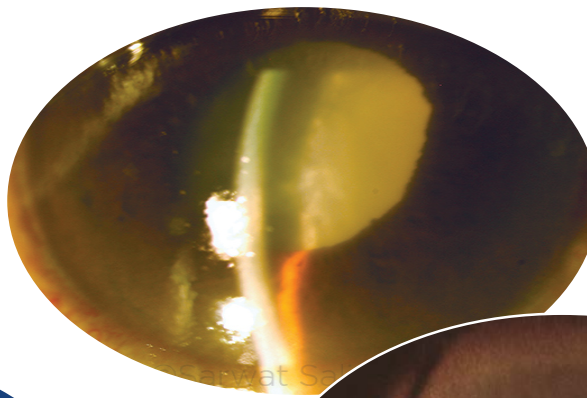
Secondary Angle Closure Mechanism

Secondary angle closure can result in **acute** attacks or could be **chronic**.

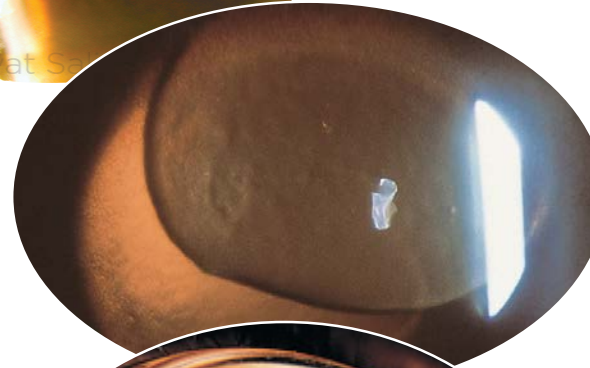


Secondary Angle Closure With Pupillary Block

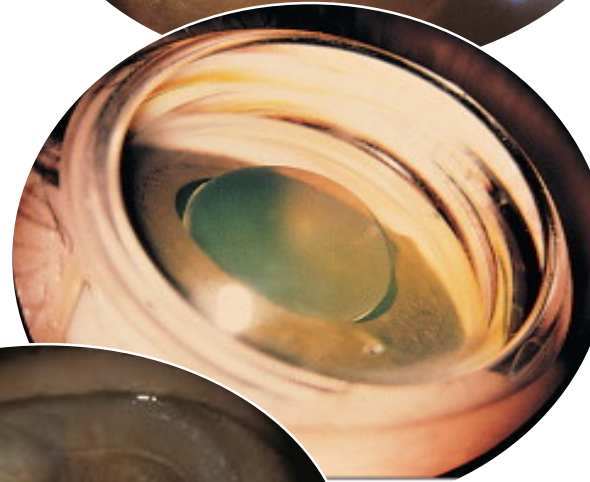
Lens-Induced Angle closure



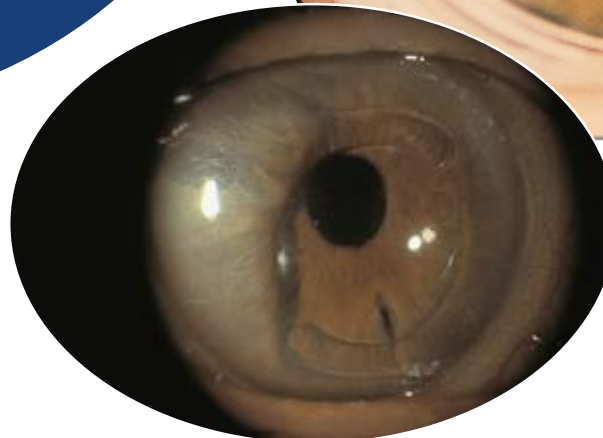Phacomorphic glaucoma



Ectopia lentis



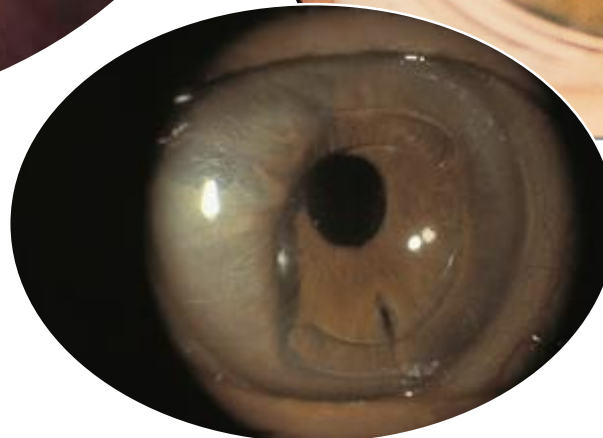
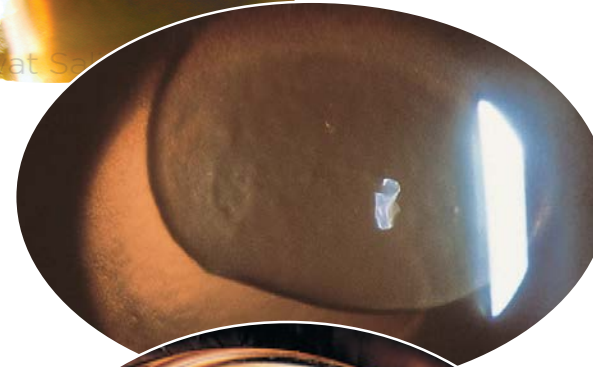
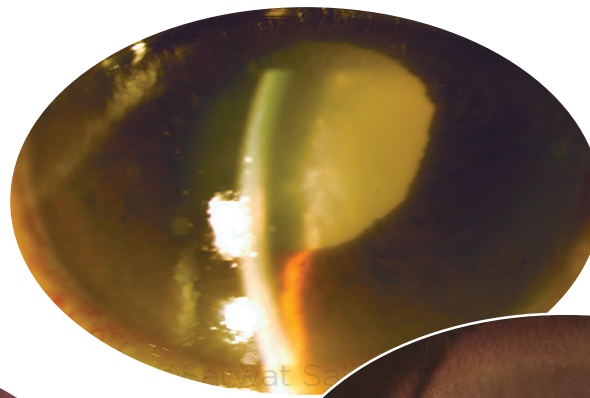
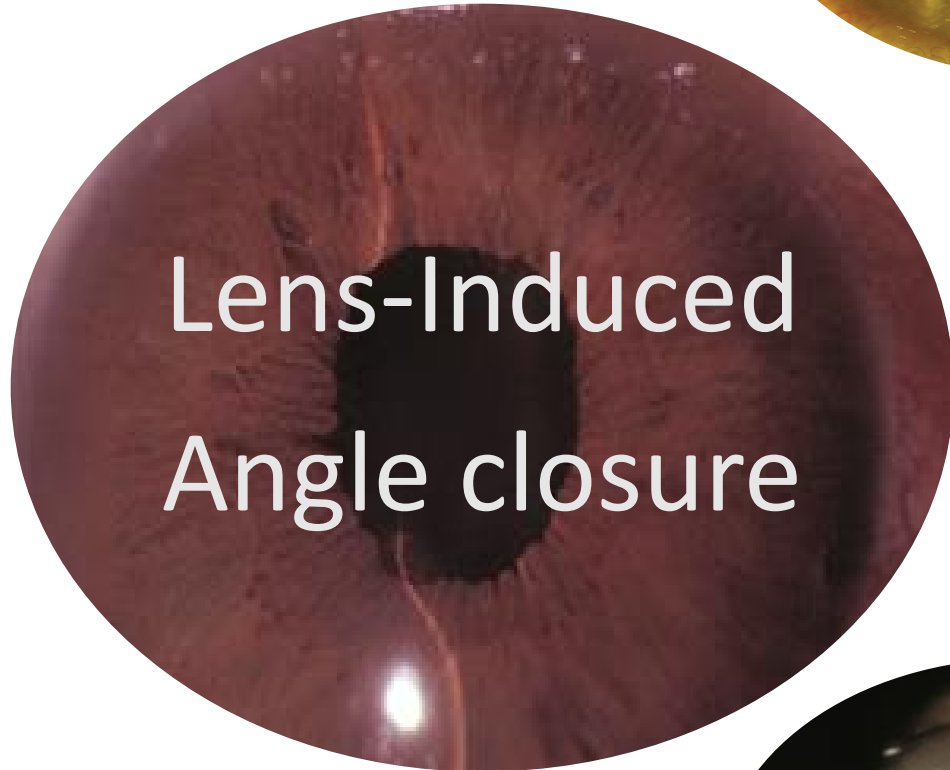
Microspherophakia



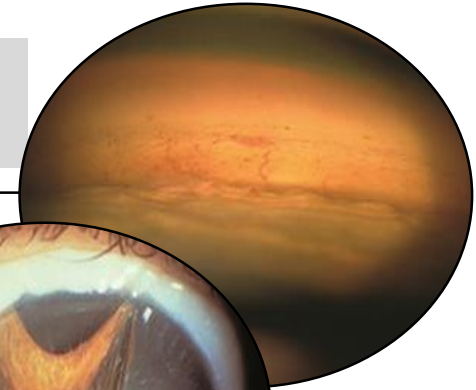
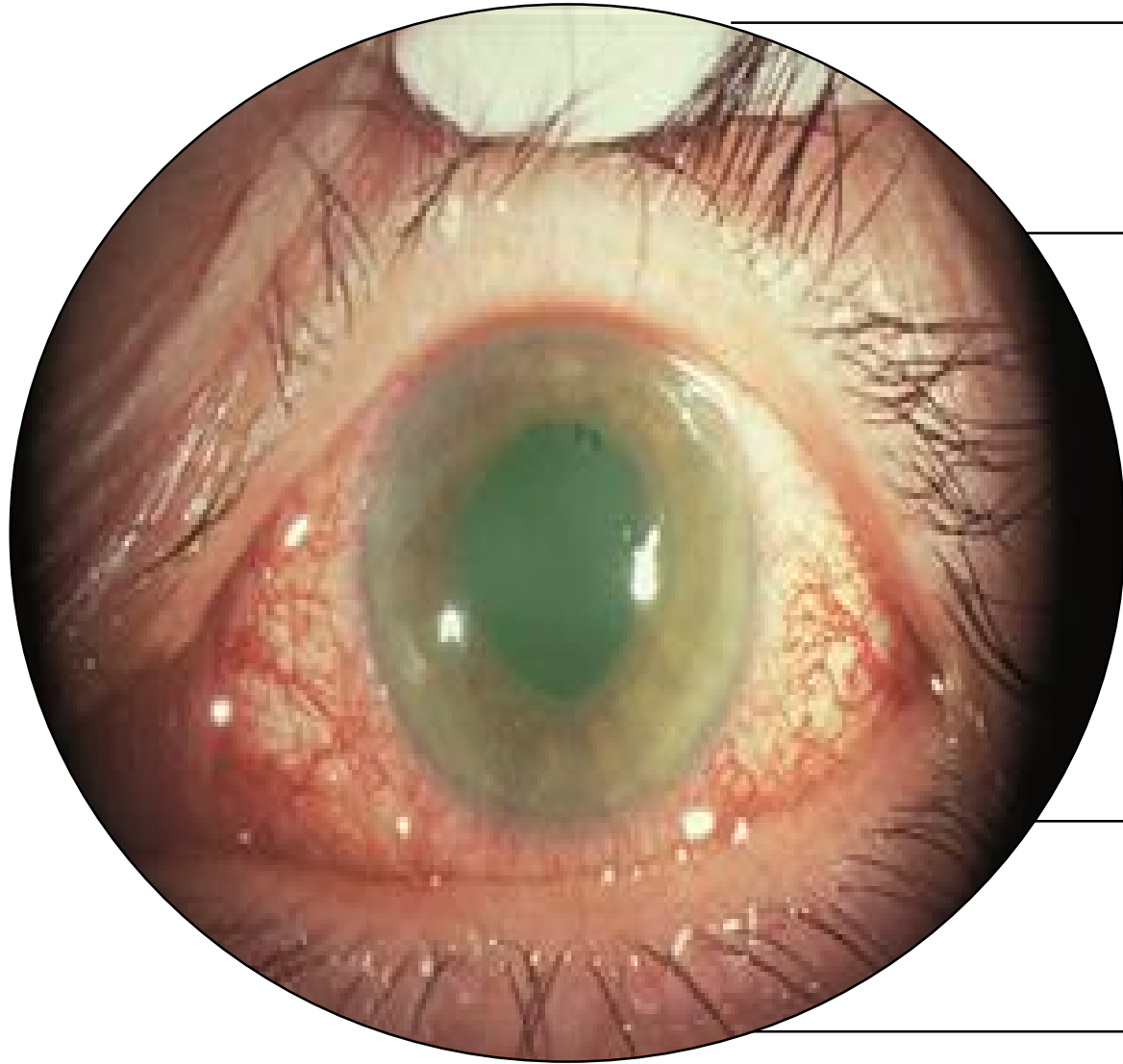Aphakic or pseudophakic



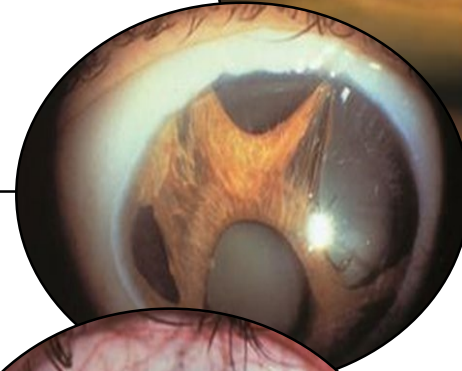
Secondary Angle Closure With Pupillary Block



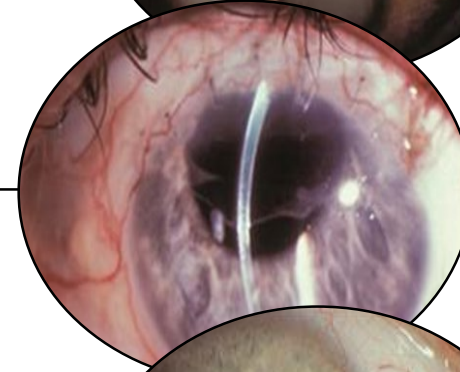
Secondary Angle Closure Without Pupillary Block



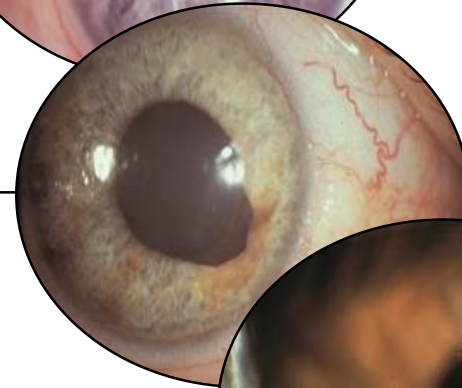
Neovascular
Glaucoma



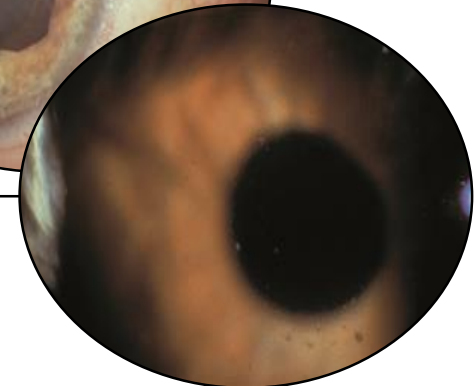Iridocorneal Endothelial
Syndrome



Epithelial and Fibrous
Ingrowth



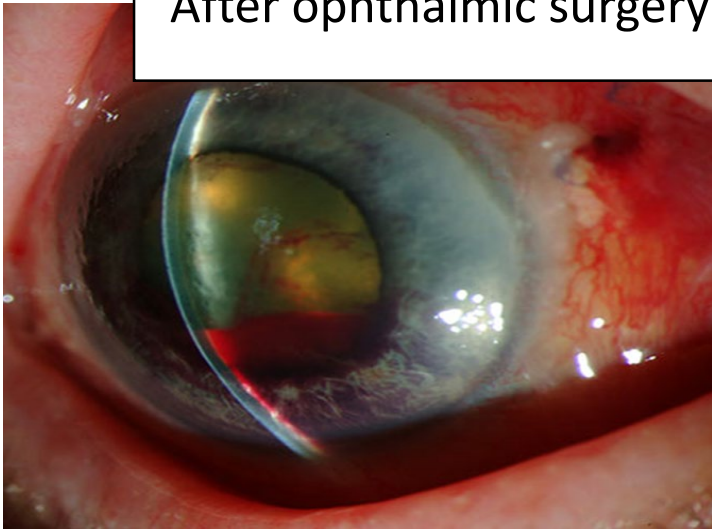
Tumors



Inflammation

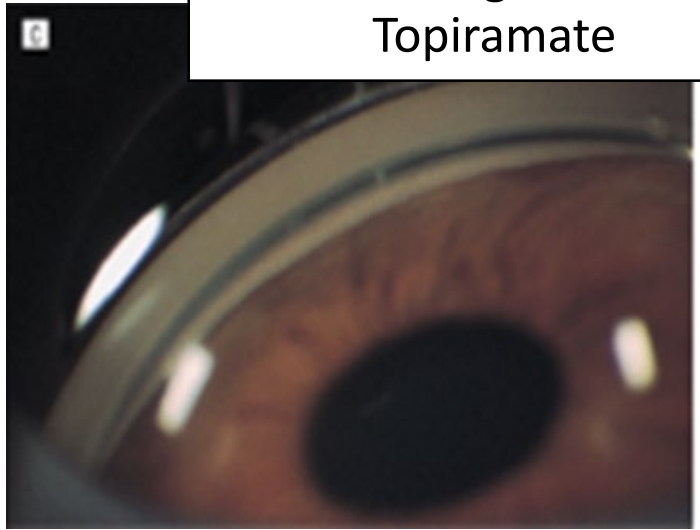


After ophthalmic surgery



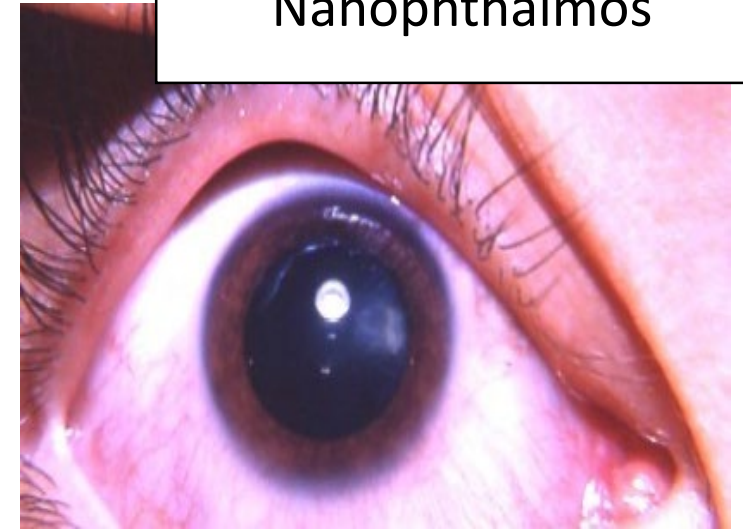
[Courtesy of Douglas J. Rhee](#)

Sulfa drugs such as
Topiramate

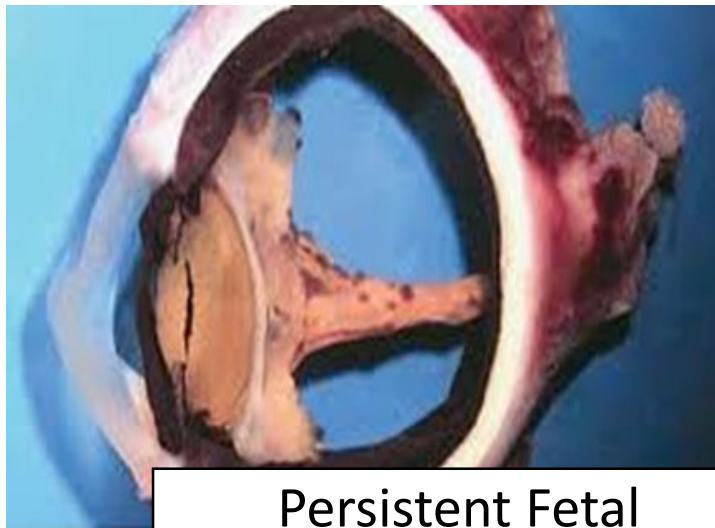

[Courtesy of William Caccamise, Sr, MD](#)

Nanophthalmos

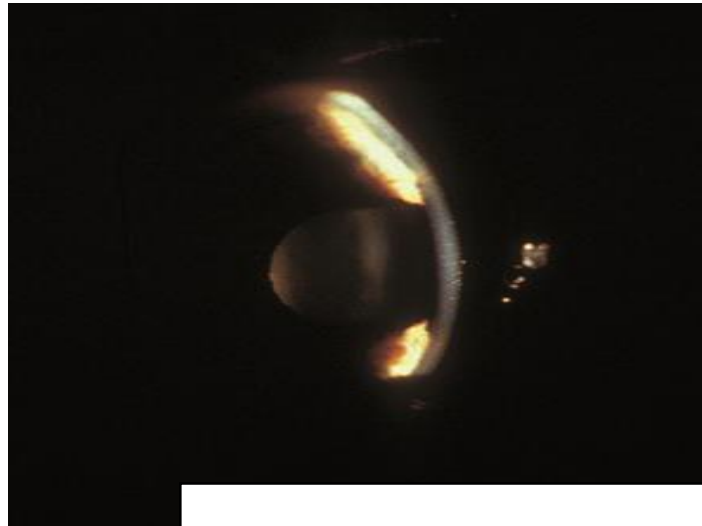


[Courtesy of Daniel G. Dawson, MD](#)



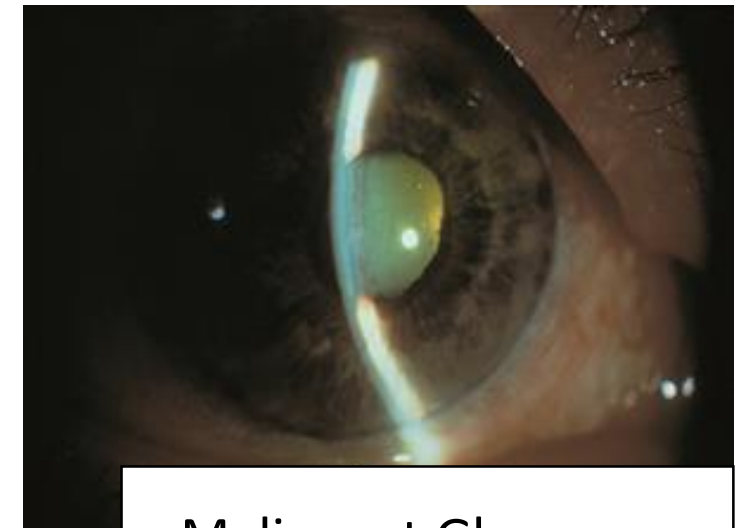
Persistent Fetal
Vasculature

[Courtesy of Justin Risma, MD](#)



Flat Anterior Chamber

[courtesy of Wallace L M Alward MD,](#)



Malignant Glaucoma

[courtesy of Wallace L M Alward MD,](#)

Aqueous Misdirection Syndrome

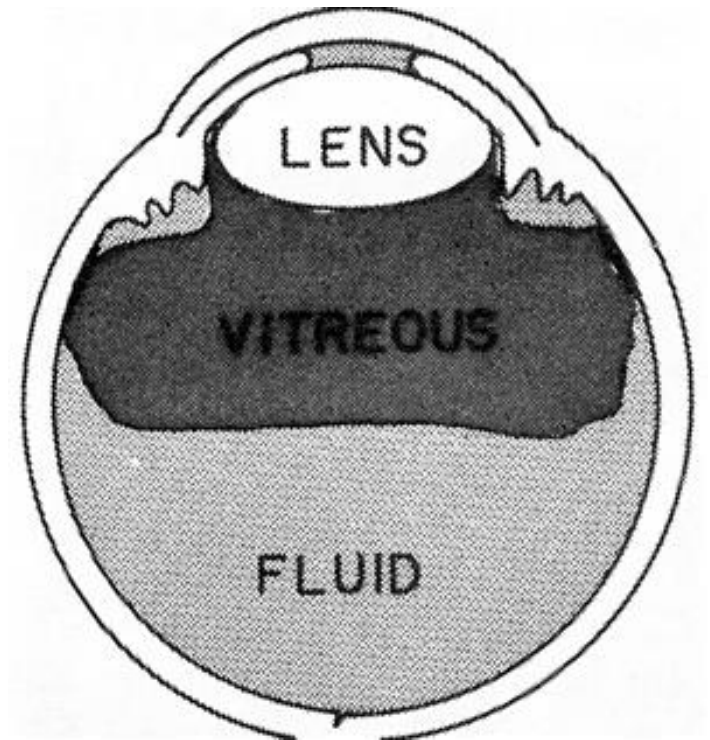
- Occurs in **up to 6%** of eyes undergoing surgery for angle-closure glaucoma.

- The mechanism of this condition is yet to be

Posterior diversion
of aqueous
with **anterior**
displacement of
ciliary processes

Acute vitreous
or uveal
congestion

Choroidal
expansion



Aqueous Misdirection syndrome

Management

Irido-zonulo-Hyaloido-vitrectomy
(Minivitrectomy)

and

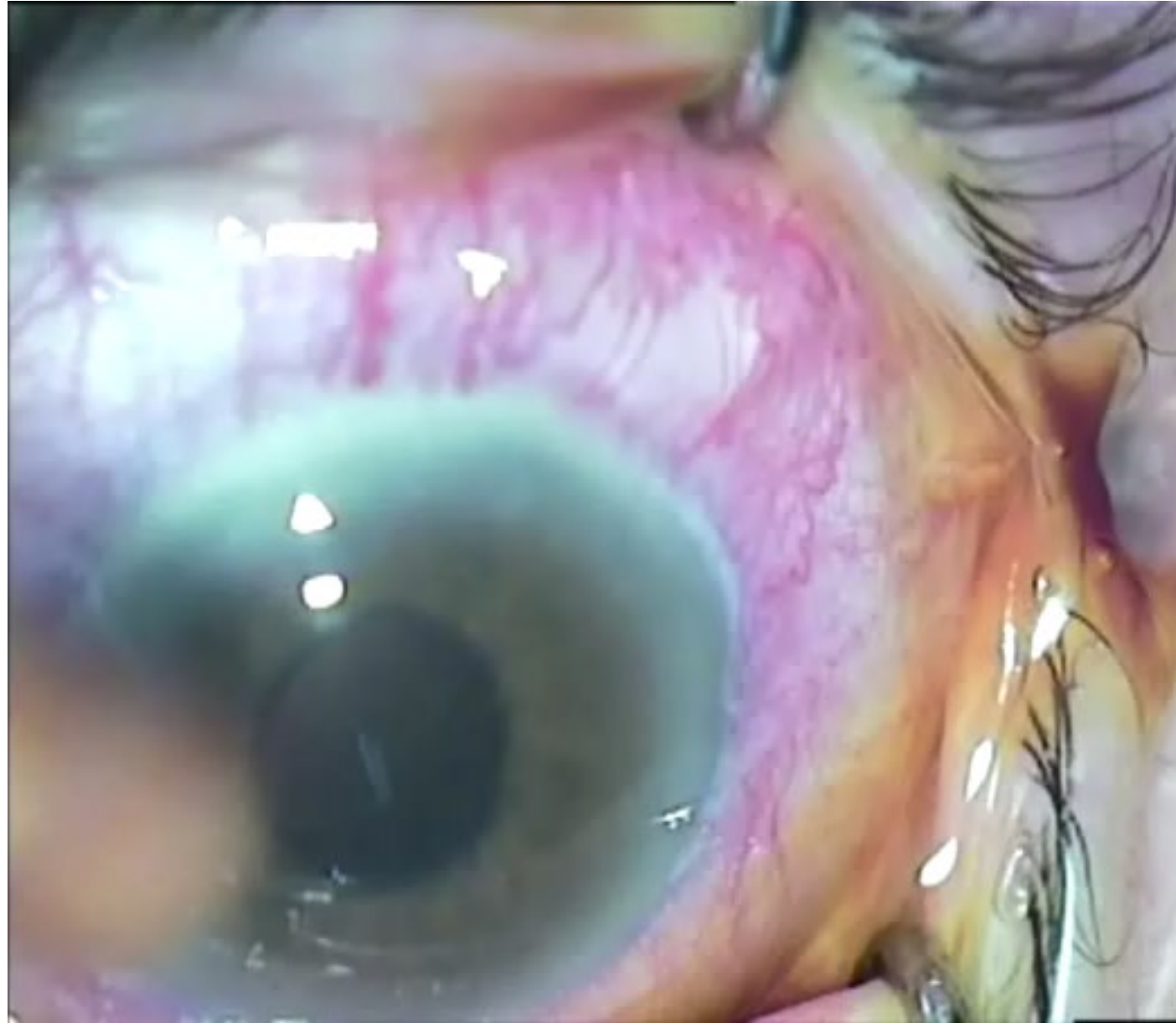
+ / - LPI, c

% in 5 days
st all relapse

Irido-zonulo-Hyaloido-vitrectomy (Minivitrectomy)

- Noemi Lois, 2001 first described this technique.
[Noemi Lois et al; *Ophthalmology* 2001](#)
- This alternative technique can be performed instead of pars plana core vitrectomy.
- No need for retina surgeon!
- Every Glaucomatologist can perform
- Very simple and prompt technique (Minivitrectomy)
- We reported 24 cases; 22 (92%) responded.
[Mohammad Pakravan et al; *J Ophthalmic Vis Res* 2018](#)
- Recently we combined it with **limited CPC** in 1 quadrant







Mount Damavand Iran (5609.2 m; 18,403 ft)
The second most prominent mountain in Asia after Everest.



Thank you

www.youtube.com/watch?v=eo0UvdKNMRU

